

VOLUME 27 | ISSUE 2

APRIL  
MAY  
JUNE

2015

ISSN 2241-9136

Hellenic

# Urology

Quarterly Publication by the Hellenic Urological Association

## REVIEWS

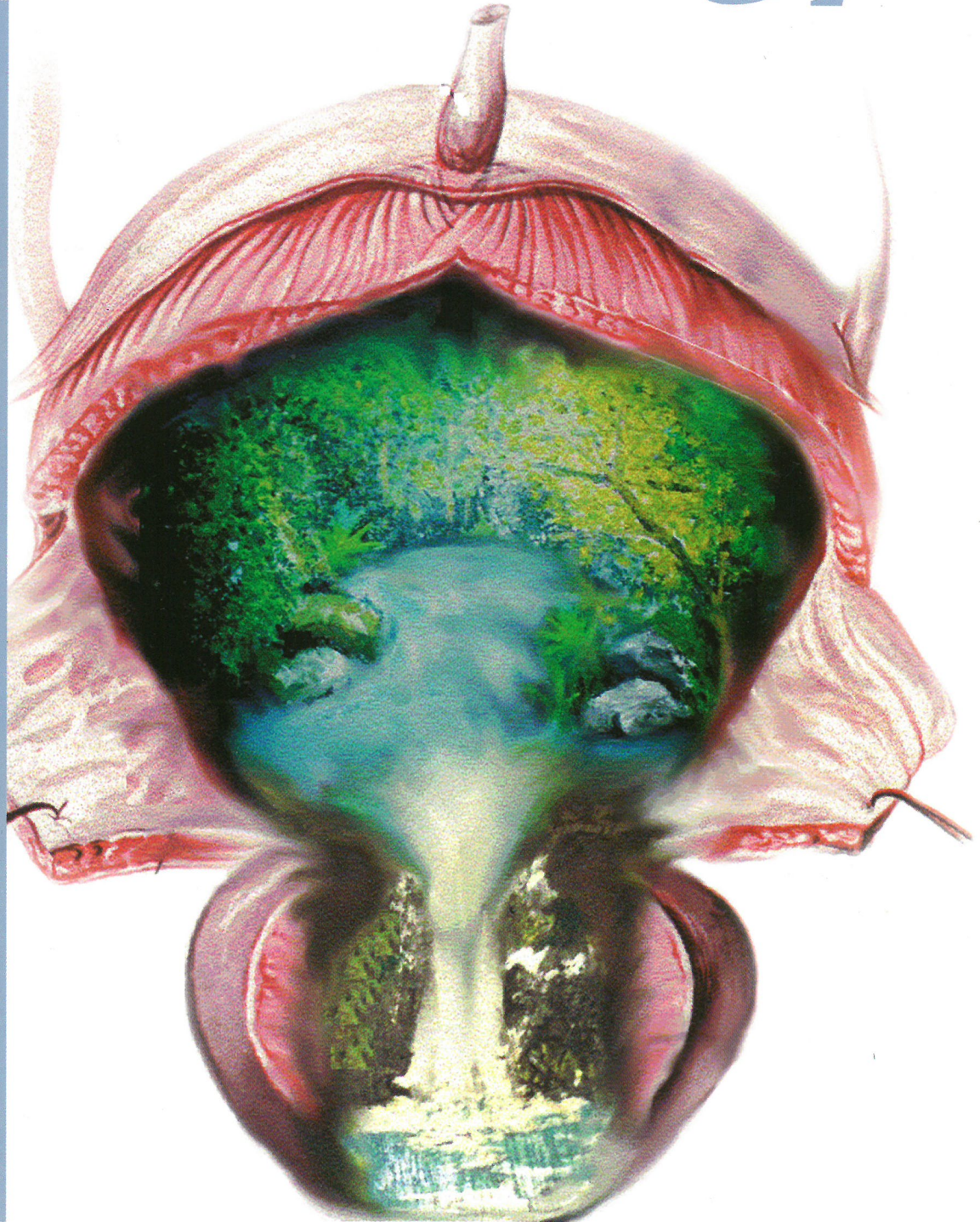- Retroperitoneal Fibrosis
- Intermittent androgen deprivation therapy for prostate cancer

## ORIGINAL ARTICLES

- Short term minocycline administration in gram+ chronic bacterial prostatitis
- TVT for female stress incontinence treatment
- Glans reconstruction using inverted urethral flap

## CASE REPORTS

- Leiomyoma of the epididymis
- Renal artery thrombosis as a result of blunt abdominal trauma



**HELLENIC UROLOGY**

Official Journal of the Hellenic Urological Association



## ORIGINAL ARTICLE

# Glans reconstruction using inverted urethral flap in penile cancer patients who undergo glansctomy or distal corporectomy under penile block. A feasible option in high - risk patients

Vasileios Sakalis<sup>1</sup>, Anastasia Gkotsi<sup>2</sup>, Vasileios Sfiggas, Asterios Fotas<sup>1</sup>, Ioannis Vouros<sup>1</sup>, Georgios Salpiggidis<sup>1</sup>, Athanasios Papathanasiou<sup>1</sup>

<sup>1</sup> Department of Urology, Hippokrateion Hospital of Thessaloniki, Greece

<sup>2</sup> 2nd Department of Internal Medicine, Hippokrateion Hospital of Thessaloniki, Greece

## Abstract

**Objective:** To assess the limitations and the complications of urethral flap neoglans reconstruction in high - risk patients who undergo a penile amputation procedure under local anaesthesia.

**Materials and Methods:** 5 patients with squamous cell carcinoma of the penis underwent glans reconstruction using an inverted urethral flap after glansctomy or distal corporectomy. A penile block with 10ml lignocaine 2% and 10ml naropaine 0.75% was used. After tumour excision, the urethra was carefully dissected and margins were sent off for frozen section prior to reconstruction. The median patient age was 77 years (range 67 to 89). The American Society of Anaesthesiologist (ASA) score

was 3. The median operation time was 139 minutes (range 125 - 160). The median follow up time was 12 months (range 8 to 15).

**Results:** Penile block served adequately in all cases. None required additional analgesia perioperatively. Flaps were taken well in all patients and no complications noted. There were no local recurrences.

**Conclusions:** Neoglans reconstruction using an inverted urethral flap is a feasible and reproducible procedure which can be performed under penile block thus avoiding anaesthesia-related risks in high risk patients who are interested in good cosmetic results.

## Introduction

Penile cancer (PenCa) is a rare disease that accounts for 0.4 - 0.6% of all malignancies in Europe and North America<sup>1</sup>. Early detection and treatment often leads to complete cure, while spread to lymph nodes or distant metastasis carry significantly less favorable outcomes<sup>2</sup>. Surgery remains the definitive treatment option for the primary penile lesion in

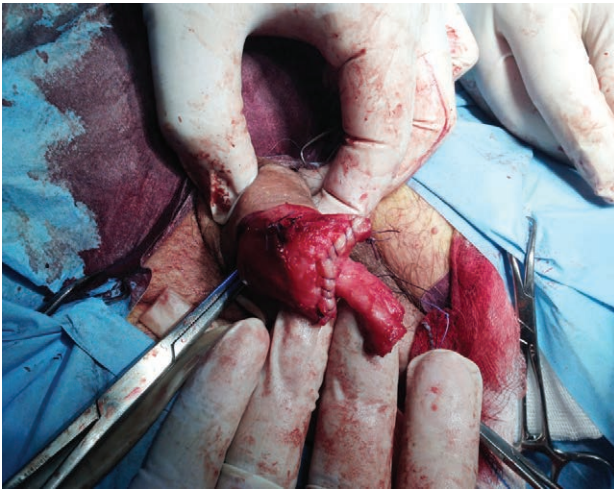
addition to regional lymphadenopathy management. External beam radiotherapy or brachytherapy are alternatives treatment methods to surgical excision, but recommended only in smaller size tumours (<4cm)<sup>1</sup>. Surgical management usually means partial or total amputation with subsequent functional disability and psychosexual morbidity that can be psychologically devastating for both patient and partner<sup>3</sup>.

### Key words

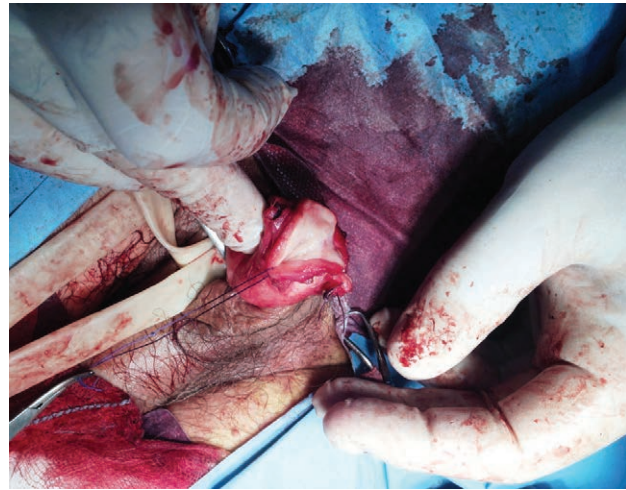Glans reconstruction,  
urethral flap,  
penile cancer

### Corresponding author:

Vasileios Sakalis, Konstantinoupoleos 49, Thessaloniki, Greece, POB 54642, Tel: +30 2310 892376, Mob: +30 6987 402020



**Figure 1.** The distal urethra following mobilization and dissection after tumour excision



**Figure 2.** Ventral spatulation and eversion of urethra to cover the corporeal defect

According to the European Association of Urology (EAU) guidelines, stage T1 and T2 tumors should be treated with penile preserving and reconstructive techniques such as glansctomy and neoglans reconstruction for glans tumors or distal corporectomy and neoglans reconstruction for tumors invading distal corpora<sup>1</sup>. The traditional teaching of primary lesion excision with 2 cm of macroscopically healthy tissue has been replaced by a 5 mm surgical margin that is equally oncologically safe, sparing functional penile length<sup>4,5</sup>. Moreover, neoglans reconstruction reduces psychological distress, allows sexual activity, improves urination and thus enhances quality of life.

So far, several techniques for neoglans reconstruction have been described. Split skin grafts, harvested from the inner thigh, are commonly used in modern penile cancer centers with excellent functional and cosmetic results<sup>6</sup>. Less often, full skin grafts from scrotum or lower abdomen and oral mucosal grafts are used<sup>7</sup>. Alternatively, glans can be reconstructed with the use of urethral, rectus abdominis or palmaris longus flaps<sup>6</sup>. Nevertheless, whichever the reconstructive procedure is used, general anaesthesia is prerequisite, thus excluding the anaesthetically high - risk patient group. In addition, grafting requires tissue harvesting equipment that is not available in many centers.

In this paper we present our experience with the inverted urethral flap for neoglans reconstruction, under penile block in high - risk penile cancer

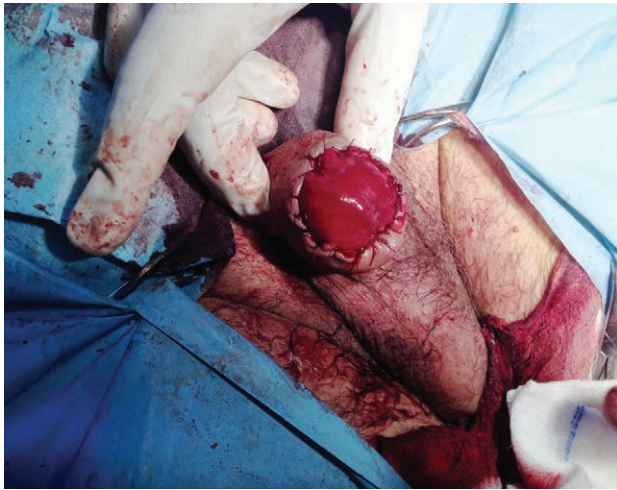
patients to whom general or spinal anesthesia was contraindicated.

### Material and Methods

Urethral flap neoglans reconstruction under penile block was offered to 7 invasive penile cancer patients, unfit for general or spinal anesthesia due to serious comorbidities, who underwent glansctomy ± distal corporectomy.

All patients provided their written consent to undergo this procedure and to participate in the study. The patients were staged preoperatively by CT Scan Thorax - Abdomen - Pelvis to detect loco - regional or distant metastasis. Regional lymphadenopathy was assessed by groin ultrasound. Fine needle aspiration cytology (FNAC) performed in all suspicious nodes according to standardized ultrasound criteria for FNAC<sup>8,9</sup>. Patients with history of penile urethral stricture disease or positive urethral margins on frozen sections were excluded from the study and had a simple parachute or fish mouth closure of penile shaft skin over the corpora defect.

Under penile block (10ml Lignocaine 2%, 10ml Naropaine 0.75%), penile shaft skin was circumferentially incised 1cm proximal to the tumour. Dartos fascia was dissected off the Buck's fascia and the penis was degloved. A tourniquet was applied at the penile base to ensure haemostasis. Typical glansctomy followed along the plane of tunica albuginea using dissecting scissors. Once the glans was dissected off the corpora, the corpus spongiosum was transected

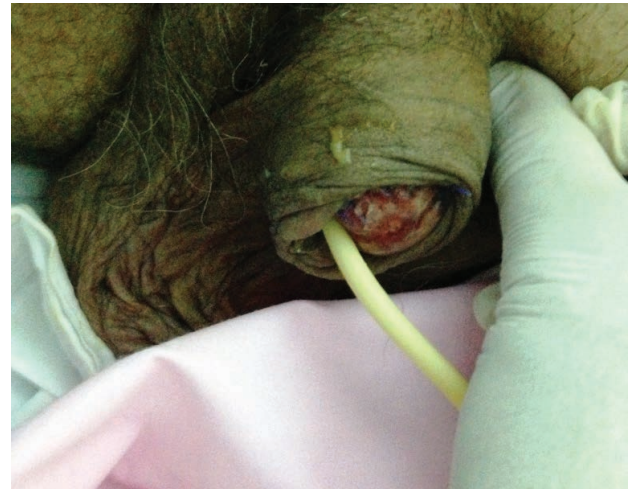

**Figure 3.** Approximation of penile skin to the urethral flap for the completion of the reconstruction

with a clean blade. Frozen sections were requested for both urethral tissue and tunica albuginea from cavernous bodies. When tunica involvement was evident, distal corporectomy commenced. The penile urethra was mobilized to gain adequate length to cover the cavernous bodies. The corporeal defect was sutured with 3 - 0 vicryl continuous suture (**Figure 1**). Tourniquet removal identified bleeders from Buck's fascia or corporal tissue allowing bleeding only from the transected spongiosum. The urethra was then ventrally spatulated 2cm and everted to cover the cavernosal tissue serving as a neoglans (**Figure 2**). The urethral margins were fixed to the tunica using interrupted 4 - 0 rapid, while the spatulated proximal edge was sutured to the median raphe of the penile shaft skin. The Dartos fascia was sutured 1cm away from neoglans and the penile skin was approximated to the edge of the urethral flap (**Figure 3**). At the end of the procedure, a two - way 14 Fr Silicon catheter was inserted and Vaseline gauze on a light dressing was applied. Patients were advised to stay on bed for 24 hours to maximize flap adherence. Full mobilization was allowed from the 2nd postoperative day. The catheter was removed on the 5th postoperative day (**Figure 4**). All patients had a preoperative dose of Gentamycin and three doses of Co - Amoxiclav 625mg in the next 24 hours. Follow up was at the 2nd postoperative week and then 3 monthly as per EAU guidelines.

## Results

Since May 2013, 24 penile cancer patients were



**Figure 4.** The urethral neo-glans on the 5th postoperative day

admitted for surgical management. 10 patients were classified as anaesthetically high risk, with ASA (American society of Anaesthesiologists) score  $\geq 3$ . Urethral flap neoglans reconstruction was offered to 7 of them. The study included 5 patients since 2 were excluded due to positive urethral margins.

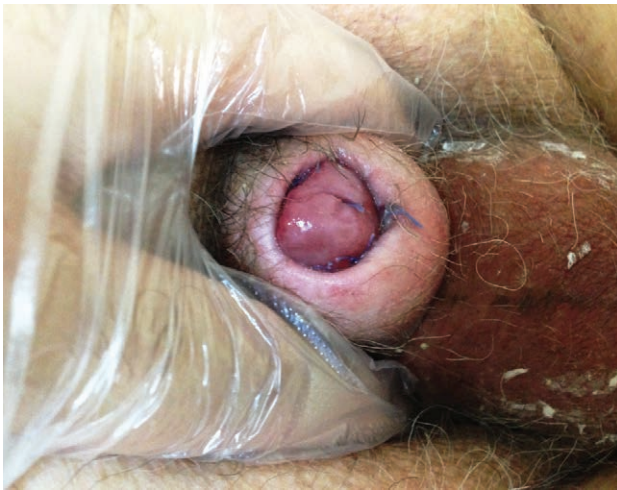The basic demographics are shown on **table 1**. All patients had ASA score 3. Two were considered high risk due to uncontrolled diabetes, two due to reduced lung capacity and one due chronic renal failure and hypertension. One patient had glansctomy while four had additional distal corporectomy as tunica involvement was evident. There were no perioperative or postoperative complications. The median operation time was 139 min (Range: 125 - 160) including the time of the frozen section. Postoperative analgesia was controlled with paracetamol per request.

The flaps appeared erythematous and moist until the 4th-5th postoperative day due to exteriorization of urothelium and to the secretions from urethral glands. Tiny darkened areas typically observed at points of tension, without interfering with the viability of the flap.

Fresh frozen section results agreed with the final pathology results. The histologic diagnosis in all patients was squamous cell carcinoma of usual type arising from penis, stage T2. None had neither deep nor lateral positive margins.

At the 2nd week follow up, there were no complains in terms of pain, sensation, secretions and urination. One patient presented with a burried penis, having





**Figure 5.** The urethral neo-glans on the 14th postoperative day. A case of iatrogenic buried penis.

difficulties in urinating, but he managed to avoid wetting himself by pressing his pubic fat and exposing the penile stump (**Figure 5**).

There were no local recurrences and none required further penile operation. At preoperative staging, two patients had palpable groin lymphadenopathy and one had positive fine needle aspiration unilateral. He underwent groin radiotherapy as he was not fit for groin dissection.

All flaps were taken well and there were no neomeatal related complications.

## Discussion

Urethral flap neoglans reconstruction is a good alternative to grafting in invasive penile cancer patients, who undergo a penile preserving procedure under local anaesthesia. A penile stump of sufficient length enables not only sexual activity, but also proper urination in the standing position.

Clearly, this reconstruction technique offers many advantages. The procedure is well tolerated under local anaesthesia. It minimizes the anaesthesia related risks thus representing an ideal option for high risk patients. It is an easy to perform procedure, as long as the surgeon respects the anatomical planes. In terms of oncological safety, we believe that it shares similar recurrence rate with any other neoglans reconstruction, and it does not exceed the known 27% recurrence rate in the first two years, as long as the urethral margins are free of disease<sup>10</sup>.

TABLE 1	Patient demographics, histology results and need for systemic therapy
Patient Age (Median (range))	77 (67-89) years
Follow up (Median (range))	12 (8-15) months
ASA Score	Score 3 (5 patients)
Tumor Stage	T2a (3 patients), T2b (2 patients)
Tumor Grade	Moderate (2 patients), Severe (3 patients)
Lateral margins	>2 mm
Deep margins	>3 mm
Groin Lymphadenopathy	Palpable (2 patients), Positive FNA (1 patient)
Distant metastasis	None
Neo Adjuvant Therapy	None
Adjuvant Therapy	None
Operation Time (Median (range))	139 (125-160) min
ASA: American Society of Anaesthesiologists	

Urethral flap neoglans reduces postoperative morbidity as it avoids donor site complications such as pain, infection, bleeding, poor healing, irritation and need for wound care. In addition, there is no need for graft harvesting equipment, reducing the cost of the operation, thus making it feasible in poor equipped centers.

To the best of our knowledge, there is no penile cancer operation that can offer a full recovery of sexual activity<sup>11</sup>. However, neoglans reconstruction is an additional aid in the maintenance of sexual function to preoperative levels. Our patient group suffered from erectile dysfunction prior to penile cancer diagnosis, hence making the assessment of postoperative sexual dysfunction difficult. Gulino et al, evaluated 42 penile cancer patients who underwent glansectomy ± distal corporectomy and neoglans reconstruction from an inverted urethral flap. They used specific questionnaires (IIEF-15 and Bigelow - Young) and non-specific questions about sexual function, ejaculation

and libido. The study showed that 60% of patients engaged in a successful sexual intercourse at 5th postoperative week while 76% of patients regained ejaculation and orgasm by that time<sup>12</sup>. Urethral thermoreceptors and/or mechanoreceptors might be involved and activate ejaculatory and orgasmic pathways<sup>11</sup>.


As adequate penile length is preserved, the aesthetic result is satisfactory and the neoglans is more natural, compared to split skin grafts. The spongy neoglans retains its own blood supply; it engorges during erection and gives a more physiologic appearance<sup>4</sup>.

Although, we did not encounter any postoperative problems, there are few well-described complications in the literature. Ventral penile curvature is a consequence of short urethra that acts as a bowstring at erection, occurs in 10% of cases<sup>6</sup>. Sansalone et al, reports a 6% risk of bleeding and haematoma that might need surgical evacuation and a 3% risk of early local recurrence<sup>4</sup>. Another Italian group, who studied the sexual outcomes after glansctomy and glans reconstruction using urethral flap, reported that 24% of patients had orgasm and ejaculation difficulties while 40% failed to have coital activity<sup>12</sup>. Furthermore, only

73% of patients reported spontaneous rigid erections. The negative psychosocial impact is primarily a result of penile cancer disease and the penile operation-glans reconstruction is proved to add a positive value<sup>13</sup>.

The main disadvantages of this procedure are the possibility of positive urethral margins and flap failure. The surgeon needs to rely on the frozen section results. If the section is positive, an additional section of spongiosum should be examined, and if there is insufficient length, a simple penectomy without reconstruction should be performed. Urethral flap viability depends on adequate urethral blood supply. Patients with history of penile urethra stricture disease and extensive spongiofibrosis should be treated with another type of reconstruction.

### Conclusion

We do believe that neoglans reconstruction using urethra flap complies with EAU penile cancer guidelines- it is a quick, oncologically safe and reliable technique. It has good cosmetic and functional results. It is feasible under penile block and devoids of anaesthetic complications in high-risk patients who are not fit for general or regional anaesthesia. 

## Περίληψη

**Στόχος:** Η αξιολόγηση των περιορισμών και των επιπλοκών της κατασκευής νεοβαλάνου από περυσίο ουρήθρας σε ασθενείς υψηλού κινδύνου με καρκίνο του πέους που υποβλήθηκαν σε ακρωτηριασμό του οργάνου υπό τοπική αναισθησία.

**Υλικά και Μέθοδοι:** Πέντε ασθενείς με πλακώδες καρκίνωμα του πέους σταδίου T1 και T2. Η μέση ηλικία των ασθενών ήταν 77 έτη (εύρος 67-89). Η βαθμολογία ASA (American Society of Anaesthesiologists' score) ήταν 3. Η τοπική αναισθησία εξασφαλίστηκε με μπλοκ του πέους από 10ml λιγνοκαΐνης 2% και 10ml naropaine 0,75%. Όλοι υποβλήθηκαν σε ανάπλαση βαλάνου με χρήση ανεστραμμένου περυσίου ουρήθρας μετά από βαλανεκτομή ή μερική πεκτομή. Σε όλους αποκόπηκε προσεκτικά η ουρήθρα μετά την αφαίρεση του όγκου και τα όρια στάλθηκαν για ταχεία βιοψία. Ο διάμεσος χρόνος της επέμβασης ήταν 139 λεπτά (εύρος 125-

160) ενώ ο διάμεσος χρόνος παρακολούθησης ήταν 12 μήνες (εύρος 8-15).

**Αποτελέσματα:** Το ως άνω περιγραφόμενο μπλοκ του πέους εξασφάλισε επαρκή τοπική αναισθησία σε όλες τις περιπτώσεις και δεν απαιτήθηκε επιπλέον αναλγησία διεγχειρητικά. Σε όλους τους ασθενείς ελήφθησαν καλά τα περυσία της ουρήθρας και δεν σημειώθηκαν επιπλοκές. Σε καμία περίπτωση δεν υπήρξε τοπική υποτροπή.

**Συμπεράσματα:** Η κατασκευή νεοβαλάνου με τη χρήση ανεστραμμένου περυσίου ουρήθρας είναι μια εφικτή και επαναλήψιμη διαδικασία, η οποία μπορεί να πραγματοποιηθεί με μπλοκ του πέους από 10ml λιγνοκαΐνης 2% και 10ml naropaine 0,75% αποφεύγοντας έτσι τους κινδύνους που σχετίζονται με την γενική αναισθησία σε ασθενείς υψηλού κινδύνου που ενδιαφέρονται για ένα καλό αισθητικό αποτέλεσμα.

### Λέξεις ευρετηριασμού

Ανακατασκευή βαλάνου, περυσίο ουρήθρας, καρκίνος πέους

## References

1. Hakenberg OW, Comperat E, Minhas S, Necchi A, Protzel C, Watkin N. members of the European Association of Urology (EAU) Guidelines Office. Guidelines on Penile cancer. In: EAU guidelines, edition presented at the 29th EAU Annual Congress, Stockholm 2014.
2. Novara G, Galfano A, De Marco V, Artibani W, Ficarra V. Prognostic factors in squamous cell carcinoma of the penis. *Nat Clin Pract Urol* 2007; 4: 146-6.
3. Ornellas AA, Correia AL, Marota A, et al. Surgical treatment of invasive squamous cell carcinoma of the penis: retrospective analysis of 350 cases. *J Urol* 1994;151:1244-9.
4. Sansalone S, Garaffa G, Vespasiani G, Zucchi A, Kuehhas FE, Herwig R, Silvani M, Pecorato S, Loreto C, Leonardi R. Glans reconstruction with the use of an inverted urethral flap after distal penile amputation for carcinoma. *Arch Ital Androl Urol* 2013;85:24-7.
5. Philippou P, Shabbir M, Malone P, et al. Conservative surgery for squamous cell carcinoma of the penis: resection margins and long-term oncological control. *J Urol* 2012 Sep;188(3):803-8.
6. Garaffa G, Sansalone S, Ralph D. Penile reconstruction. *Asian J Androl* 2013;15:16-9.
7. Mazza O, Cheliz G. Glanuloplasty with scrotal flap for partial penectomy. *J Urol* 2001; 166:887-9.
8. Hadway P, Smith Y, Corbishley C, Heenan S, Watkin NA. Evaluation of dynamic lymphoscintigraphy and sentinel lymph-node biopsy for detecting occult metastases in patients with penile squamous cell carcinoma. *BJU Int* 2007;100:561-5.
9. Lam W, Alnajjar H, La-Touche S, Perry M, Sharma D, Corbishley C, Pilcher J, Heenan S, Watkin N. Dynamic sentinel lymph node biopsy in patients with invasive squamous cell carcinoma of the penis: A prospective study of the long term outcome of 500 inguinal basins assessed at a single institution. *Eur Urol* 2013;63: 657-663.
10. Djajadiningrat RS, van Werkhoven E, Meinhardt W, et al. Penile sparing surgery in penile cancer: does it affect survival? *J Urol* 2013;192:120-6.
11. Carro-Juarez M, Rodriguez-Manzo. Role of genital sensory information in the control of the functioning of the spinal generator for ejaculation. *Int J Impot Res.* 2005; 17: 114-20.
12. Gulino G, Sasso F, Palermo G, D'Onofrio A, Racioppi M, Sacco E, Pinto F, Antonucci M, D'Addessi A, Bassi P. Sexual outcomes after organ potency-sparing surgery and glans reconstruction in patients with penile carcinoma. *Indian J Urol* 2013;29:119-23
13. Salgado C, Chim H, Tang J, Monstry S, Mardini S. Penile reconstruction. *Sem Plast Surg* 2011;25:221-8.



REVIEW

# Intermittent androgen deprivation therapy for prostate cancer: a review of the recent literature and guidelines

Athanasios N. Argyropoulos, Iraklis Poulas  
*"Korgialeneio - Benakeio" Hellenic Red Cross Hospital, Athens, Greece*

## Abstract

Androgen deprivation therapy is an established therapeutic option for prostate cancer patients, but is associated with serious side effects and quality of life issues. The purpose of this

review is to present up - to - date results from randomized trials on intermittent androgen deprivation therapy and to identify those patients that will benefit the most from this approach.

## Introduction

Prostate cancer (PCa) constitutes today one of the most severe diseases affecting male population. It is the most common solid neoplasm, outnumbering lung and colon cancer among Europeans<sup>1</sup> and the second cause of death (COD) among all cancers in males<sup>2</sup>. The androgen deprivation therapy (ADT) was first described back in 1941 by Huggins and Hodges<sup>3</sup> and Schally later discovered the LHRH analogues<sup>4</sup>. Continuous androgen deprivation (CAD) has been established as the recommended treatment in a metastatic hormone-sensitive disease. However, despite the high rates in treatment response, gradually acquired treatment resistance demonstrated by most patients results in a mean survival of 2.5 - 3 years.

Cancer cell development is regulated by endogenous androgens (such as testosterone) and

any surgical approach or medication inhibiting their development plays an important role in managing the disease. ADT remains one of the most effective palliative treatments in PCa patients. However, its extended and wide administration, gradually led to reports on systemic side effects (SEs) (**table 1**). The increased worry over the identification and registry of the SEs contributed to the drawing - up of strategies, aiming to the reduction of the continuous exposure of PCa patients to ADT.

## Key words

Androgen deprivation, intermittent, prostate cancer

## Intermittent androgen deprivation definition - theory - aims

The first intermittent androgen deprivation (IAD) report was made by Klotz et al. In 1981 on 20 metastatic patients. The patients were administered diethylstilbestrol (DES) and the treatment was ceased upon good clinical

## Corresponding author:

Dr. Athanasios N. Argyropoulos, 8, Navarinou st, PC 15343, Agia Paraskevi, Athens, Greece,  
Tel.: +30 213 2068744, +30210 6082870, +306970224033



TABLE 1	<i>Complete androgen deprivation side effects</i>
A. early	-sexual function disorders (↓ libido, erectile dysfunction) -hot flashes -fatigue
B. long-term	-anemia -osseous mass loss -metabolic disorders (↑fat, triglycerides, HDL and LDL, insulin disorders) -cardiovascular events (coronary disease, myocardial infarction, sudden death)

response, aiming to the reduction of SEs and quality of life (QoL) improvement<sup>5</sup>. The treatment was resumed when the osseous metastases turned symptomatic again, and this first attempt of intermittent medication administration demonstrated its feasible application in clinical practice. The theoretical framework of this model emerged from studies on Shionogi mouse models by Bruchovsky<sup>6</sup>. According to these studies, IAD could retard the development of androgen - resistant cancer cells. Akakura et al. later reported that progression time in androgen - resistant phase was increased by three times when on IAD compared to continuous treatment<sup>7</sup>.

Medication exposure intermission (intervals, off-phase) via the testosterone restoration also aimed to a better QoL with sexual desire and potency preservation and avoidance of the rest known SEs. Despite the fact that most of the trials highlighted the need for regular monitoring of the testosterone levels when on IAD, in clinical practice, only 3% of the patients adhered to the recommendation<sup>8</sup>. The decision for treatment resumption in IAD cases is, in clinical practice, solely based on PSA levels and not on testosterone<sup>9</sup>.

Concluding, from the healthcare system point of view, the cost plays an important role. In a time where healthcare expenses are dramatically increasing in the developed countries and given the economic crisis, any plan that both reduces the expenses up to 50 - 75% and safeguards the therapeutic target is particularly appealing.

## Studies on IAD

From the first IAD description onwards, several studies have been reported in the international literature - more reports on phase II studies and less on phase III.

### A. Phase II studies

In a recent review of phase II studies of the year 2010, at least 19 studies are reported<sup>10</sup>. Their methodology is quite different regarding patients, PSA limits, treatment cycles duration and therapeutic scheme interruption.

The number of patients was small and only five studies comprised more than 100 patients<sup>11-15</sup>. The stage of the disease was also uncommon, with studies on localized or metastatic disease, combined localized and metastatic disease etc. PSA limit for treatment interruption in the majority of studies was <4 (10 studies) or ≤4 ng/ml. PSA limit for treatment resumption was, in the majority of the studies, ≥10 or >20 ng/ml, although some researchers had set much lower limits. Leuprolide was the medication most commonly administered.

The design of phase II studies mainly focused on safety issues and SEs. Mean treatment cycles was 3 - 4 per patient, range 1 - 12 cycles and the duration of each cycle was gradually reducing or, in the best case, remained stable<sup>11,16-18</sup>. In a meta - analysis performed by Shaw et al., it was found that the median of treatment cycles was 2 per patient and the intermediate off-phase period was 15.4 months<sup>19</sup>. Data on testosterone levels were available at about 60%: usually, after the first cycle, the values were restored to normal and were gradually reducing over the following cycles. The 5 - year overall survival (OS) rates were estimated at 86% in males exhibiting biochemical failure, 68% in metastatic and 90% in localized disease<sup>19</sup>. QoL was improved off-phase, anemia was treated in a significant number of patients and body weight (BW) was steadily preserved in the study of Malone et al.<sup>17</sup>. In the study of Bouchot et al., sexual activity was improved with restoration of sexual potency in 47% of the patients whereas the male subjects studied by Sato et al. reported increased energy and sense of satisfaction in terms of social and family life<sup>21</sup>.

### B. Phase III studies - Oncologic outcomes

Many phase III studies are currently in progress but not all have published their findings and others have

**TABLE 2** Randomized studies comparing IAD vs. CAD

Reference (study)	Number of patients (n)	Population	PSA Treatment Cessation Treatment Resumption		Treatment	Outcomes
da Silva et al. (2009) SEUG 9401	766	Locally advanced and M1	<4 or symptomatic. and PSA>10 ≤ 80% initial asymptomatic and PSA>20		Triptorelin + Cyproterone Acetate	Progression time HR 0.81, p=0.11 OS HR 0.99, p=0.84
Salonen et al. (2012) FinnProstate VII	554	Locally advanced and M1	<10 or 50% initial	>20 or >initial value	6 months goserelin + Cyproterone Acetate	OS HR 1.15, p=0.17 DSS HR 1.17, p=0.29
Mottet et al. (2012) TAP 22	554	M1 (bones)	<4	>10 or symp- tomatic Disease progress	6 months goserelin + flutamide	Progression time p=0.74 OS p=0.75
Hussain et al. (2013) SWOG 9346	1535	M1 PSA >5	<4	>20 or clinical progress	7 months goserelin + bicalutamide	OS HR 1.10 Min M+ HR 1.19 Ext. M+ HR 1.02
Crook et al. (2012) Protocol 77/NCT 3653	1386	Biochemical re- currence after RT	<4 normal	>10	8 months LHRH analogue + NSID	OS HR 1.03, p=0.009 (non-inferiority) DSS HR 1.18, p=0.24

been presented only as abstracts in conferences. Our search in Medline and Cochrane Library data bases (key words: prostate cancer, intermittent androgen deprivation, randomized trials, survival and quality of life) produced >10 randomized trials. In recent reviews, data from nine<sup>22</sup> and seven<sup>23</sup> studies are respectively shown; of these, only five were randomized, phase III, with complete data regarding the findings on OS and QoL<sup>24-28</sup> - two<sup>24,25</sup> of these comprised mixed groups of patients. The studies in question included 1320 patients in mixed and 3094 in pure group patients. The initial PSA limit to enter the trial was, in the majority of the patients, >3 or >5 ng/ml and the IAD treatment phase in the trial ranged from 3 to 8 months; in the majority of the cases it was 7 to 8 months. Except for one<sup>25</sup>, all trials ceased treatment when PSA levels were <4 ng/ml and treatment was reinstated when PSA levels were >10 or >20 ng/ml. The median monitoring value ranged from 44-108 months. The findings of the studies are briefly depicted in **table 2**.

### B1. SEUG 9401<sup>24</sup>

In the SEUG 9401 study on locally advanced and metastatic disease, the progression time of the disease in the IAD group was slightly shorter compared to CAD (HR 0.81, p= 0.11), and OS exhibited no statistically significant difference (HR 0.99, p= 0.84). In a non-metastatic disease, OS favored CAD whereas in metastatic patients the data favored IAD. In the recent SEUG 9901<sup>29</sup> study, the best candidate for IAD is a patient with M0, T3 and pretreatment PSA <100 ng/ml which reduces to <4 ng/ml (and preferably <1 ng/ml) 3 months after the initial treatment.

### B2. FinnProstate VII<sup>25</sup>

In FinnProstate VII, on locally advanced and metastatic disease, no difference occurred both in the number of total deaths in IAD and CAD groups (186 vs, 206, p=0.17) and in PCa - related deaths (117 vs. 131, p=0.29).

### B3. TAP22<sup>26</sup>

In the TAP22 study on metastatic Ca, the median OS

TABLE 3	Indications on IAD application
1.	In non-metastatic disease (M0), in patients with biochemical recurrence after therapeutic intervention (investigation for possible salvage therapy should precede)
2.	In metastatic disease (M+), when severe IAD treatment-induced SEs are present
3.	In patients with advanced PCa who are primarily interested in preserving the best QoL possible
4.	All IAD patients should be under close monitoring, especially when off-treatment

(52 vs 42 mo,  $p=0.75$ ) and the median OS without disease progression (15.1 vs. 20.7 mo,  $p=0.74$ ) had no statistically significant difference between IAD and CAD.

#### B4. SWOG 9346<sup>27</sup>

The SWOG 9346 study recruited the largest number of patients so far (1535) comparing IAD and CAD in patients with metastatic PCa. It included patients with metastases and initial PSA >5 ng/ml in a 7 - month therapy. If PSA was <4 in the 6th month, then, patients were randomized to IAD or CAD. Treatment reinstatement was decided when PSA was >20 ng/ml. The design of the study foreseen that IAD was not inferior to CAD (non-inferiority trial) and the delta coefficient was 1.2.

Mean OS was 5.8 against 5.1 years for IAD and CAD, respectively (death HR in IAD 1.10; 90% confidence interval, 0.99 - 1.23) and was not statistically significant. In a further analysis in the course of the study among patients with minimal metastatic disease (spinal column, lymph nodes and pelvis), the mean OS differed by 1.5 year (5.4 years IAD and 6.9 CAD with HR 1.19), whereas in widespread metastatic disease (sides, long bones, skull, intestines) the difference favored IAD by 5 months, 4.9 against 4.4 years (HR 1.02).

The analysis of the SWOG 9346 study presents some contradicting outcomes. The mean OS was shorter on IAD by 7 months, with increase of the relative death risk by 10%. The initial hypothesis of the 20% difference cannot be rejected with 90% certainty. According to the review by Piaggio et al.<sup>30</sup>, for the analysis of such studies, when the confidence interval also includes the non-inferiority margin (1.20 in this study) and 1.00, the study produces vague outcomes. Researchers conclude that the outcomes suggest that IAD can affect OS and

the following are reported as possible causes in not detecting the difference: a) PSA limits for treatment resumption, b) monitoring period and c) the longer OS (5.8 instead of 3 years) would require a much larger pool of patients in order to establish a 0.15 difference in OS.

#### B5. NCT3653 (protocol 7)<sup>28</sup>

The NCT3653 (protocol 7) study was the first to document that in a certain patient population with localized PCa and radiation therapy (as initial or salvage treatment), IAD is not inferior to CAD in terms of OS. 1386 PSA > 3 ng/ml patients entered the study after a period of more than a year subsequent to external beam radiation therapy. IAD patients were off - treatment for 71% of the total monitoring period (37.6 mo off - phase, 15.4 on -phase). Mean OS was approximately 9 years (8.8 in IAD and 9.1 in CAD) and the difference was not statistically significant (HR 1.02; 95% CI 0.86 - 1.21).  $p$  for non-inferiority of IAD against CAD was 0.009 (HR, <1.25).

### C. Comparative analysis of randomized trials findings

The discussed randomized trials demonstrate that they pertain to different patient populations, a small pool of male subjects, although the two most recent ones (SWOG9346 and NCT3653)<sup>27,28</sup> comprised a large number of men. In terms of evidence-based medicine (EBM), the outcomes were all Ia and Ib class (LoE) - they were however based on specific - inhomogenous-populations thusly rendering the formulation of a broad spectrum of outcomes difficult. In the SWOG9346<sup>27</sup> study, in patients with metastatic disease, the design of a non - inferiority trial with a set delta coefficient, led to a statistically vague outcome. In the NCT3653<sup>28</sup> study, a non - statistically significant difference was found both in OS and in disease-specific survival.

The studies in question, along with their reported limitations, illustrate that IAD treatment does not result in significant OS shortening compared to CAD. Combined with QoL results and cost reduction, IAD seems to play an important role in certain patient groups and consequently it bears a particular value in defining the patients to benefit the most from it.

### D. Quality of Life on IAD

The main reason behind IAD studies is the preservation of the patients' better QoL which is considered to be





a result of the testosterone recovery to normal levels when off-treatment. Recovery pace is multi-factor dependent (age, IAD treatment duration and number of cycles, pretreatment testosterone levels, nationality). In the five randomized studies reported presenting OS and QoL data, different comparative methods were followed: the EORTC QLQ - C30 questionnaire in three<sup>24,26,28</sup>, Cleary's 30-question health-related quality of life (HRQoL) domains and scores in one<sup>25</sup> and SWOG's 31 special questionnaire in another<sup>27</sup>. Of the available data in a summary, deterioration in cognitive functions when on IAD is reported, which is an unexplainable finding and further investigation is suggested<sup>32</sup>.

In TAP22<sup>26</sup>, even though small differences were observed in QoL in both groups, these were not deemed significant. On IAD, less SEs were encountered ( $p=0.042$ ), and lower rates of headaches and hot flashes were reported. In SEUG9401<sup>24</sup>, SEs were more frequent in the CAD group. Statistically significant differences were found in the affective domain ( $p=0.01$ ), in nausea and vomiting ( $p=0.03$ ) and in insomnia ( $p=0.03$ ). In the FinnProstate VII<sup>25</sup> study, the IAD group exhibited lower reduction rates in activity, physical ability and sexual function. On the contrary, sexuality was higher in the CAD group. Regarding SEs, no statistically significant difference was reported.

In NCT3653<sup>28</sup>, in terms of QoL, the IAD group patients demonstrated slightly better outcomes in body functions and overall health status (non-statistically significant) whereas the differences were greater in terms of symptoms related to androgen deprivation such as hot flashes, desire for sexual activity and urinary system symptoms ( $p < 0.001$ ,  $< 0.001$  and  $= 0.006$ , respectively). 29% of patients with good pretreatment erectile function reported its restoration. In their discussion, the researchers report that they did not observe great differences in QoL, maybe due to the fact that the analysis in question was not related to the treatment phase from the outset.

In SWOG 9346<sup>27</sup>, better preservation of the erectile function, higher libido and physical function is reported 9 months after randomization and better mental health preservation in the IAD group only in the first trimester.

#### E. IAD-induced Side Effects

In a recent review of the literature by Gruca et al., 13 studies were chosen for the analysis of the patients'

safety on and tolerability to ADT, 8 of which were randomized<sup>33</sup>. SEs are categorized into early and late. The first category includes hot flashes and erectile function and desire disorders. The effect of hot flashes was analyzed in 5 trials and a statistically significant difference was found in favor of IAD. For the erectile dysfunction, studied in 6 of the trials, libido and erectile function were lower on IAD whereas the study conducted by de Leval reported that sexual function was restored off-phase<sup>34</sup> in 47% of the men. In the study performed by da Silva, the difference was 28 vs. 10% ( $p \leq 0.01$ ), however, the reduction of the erectile function was greater on CAD (0.9 vs 5.5%,  $p \leq 0.01$ )<sup>35</sup>.

In the aforementioned complications, osseous density and mass reduction, anemia, obesity and cardiovascular diseases incidences are reported. Regarding the comparison between IAD and CAD, only one study compared the incidence of osteoporotic fractures with no difference detected. Anemia was investigated in one study in absence of group comparison. Obesity was studied in three trials; BW increase was identified during therapy and BW reduction upon treatment cessation, without comparative studies. Concluding, cardiovascular complications were investigated in three studies. The acute myocardial infarction (AMI) incidence increased on CAD (4.6 vs 2.8%,  $p=0.4$ ), cerebrovascular accidents (CVA) on IAD (5.5 vs 0.9,  $p=0.6$ ), and deep vein thrombosis (DVT) also on IAD (3.7 vs 1.8%,  $p=0.3$ ).

#### IAD eligibility criteria

Subsequent to the confirmation of biochemical failure in PCa patients who underwent therapy, the androgen deprivation is usually advised. In patients with no osseous metastases (M0), IAD treatment may as well be applied, on condition that the possibility to recourse to salvage therapy has been examined. Based on the recent data found in the SWOG9346 study in metastatic patients (M+), we should be cautious with intermittent treatment. In these cases, the PSA nadir could be considered in assessing which patients will respond, as it has been suggested by some researchers<sup>35-38</sup>. In practice, this means that the patients eligible for androgen deprivation proceed with the treatment and are assessed after the end of the first treatment cycle with PSA nadir and clinical response to the treatment<sup>22,35-38</sup>. In complete response, IAD should

be tested; otherwise, CAD is a better option, especially when the off - phase period is short. In patients with advanced PCa who are primarily interested in preserving their QoL, IAD may also be recommended in patients demonstrating CAD therapy-induced serious SEs. Finally, in patients with biochemical failure after radiation therapy for localized disease, as it was shown in the NCT3653 study, no statistically significant difference was found in OS and consequently, IAD is not a good option.

### Prognostic factors


The most common prognostic factor following IAD treatment is PSA nadir<sup>24,39,40</sup>. On IAD, the PSA nadir is indicative of the respective risk: in the study performed by Sciarra et al. PSA nadir < 0.1 ng/ml was considered a good prognostic factor whereas PSA levels > 0.4 mg/ml were accompanied by double or triple the risk<sup>37</sup>. In the same study, the preparation's Gleason score and the duration of the first off-phase period ( $\leq 24$  or  $> 48$  mo,  $p = 0.01$ ) were also very significant. Gleave et al. demonstrated that when PSA nadir is not < 4 ng/ml, IAD is not indicated<sup>35</sup>. In Keizman et al.'s study, apart from PSA nadir, PSADT was also measured prior to therapy ( $\geq 6$  or  $< 6$  mo,  $p = 0.047$ ) and after the end of the first cycle ( $\geq 3$  or  $< 3$  mo,  $p = 0.05$ )<sup>36</sup>. Yu et al., in a phase II study, report that the off-phase period > 40 wks after the first cycle ( $p = 0.03$ ) was a critical and independent factor related to the transition to castration - resistant PCa<sup>38</sup>.

### International guidelines on IAD

The review of the recent guidelines on IAD delivers several recommendations. The European Association of Urology (EAU), in its revised guidelines of 2013,

reports that IAD is advised as a therapeutic option in a large number of PCa patients and should now be considered a method under investigation (LoE:2)<sup>41</sup>. It is also pointed out that even though the eligibility framework remains to be set, it will probably include males with locally advanced disease or after a local recurrence, on condition that complete response is achieved. The American Urological Association (AUA) has not published any revised guidelines from 2007 onwards on PCa and IAD is not included<sup>42</sup>. The guidelines of the American Society of Clinical Oncology (ASCO), also dated 2007, report the lack of sufficient evidence on IAD application outside the clinical trials framework<sup>43</sup>. To conclude, in the recent review of the National Comprehensive Cancer Network (NCCN) guidelines in 2014, it is reported that IAD is widely applied aiming to the reduction of SEs and the results of the NCT3653 study in patients with biochemical failure after radiation therapy (non - metastatic disease) are cited<sup>44</sup>. No clear suggestions are included on metastatic diseases since the findings of the SWOG 9346 and NCI Canada PR7 studies on advanced disease have not been included; however, certain categories of patients are suggested where IAD is applicable due to serious SEs or desire for better QoL.

### Conclusions

IAD, as it is shown in recent studies, can result in similar oncological outcomes with continuous therapy and better treatment tolerability by patients. Yet, more comparative studies are required on QoL issues, prevention of long-term complications of the intermittent therapy compared to CAD and certainly a determination of the applicable prognostic factors on treatment response. 

## Περίληψη

Ο ανδρογονικός αποκλεισμός αποτελεί μια από πλέον καθιερωμένες θεραπευτικές επιλογές στον καρκίνο προστάτη, με σημαντικές ωστόσο ανεπιθύμητες ενέργειες και επίδραση στην ποιότητα ζωής. Σκοπός της ανασκόπησης είναι η παρουσίαση των σύγχρονων δεδομένων στο διακοπτόμενο αποκλεισμό με βάση πρόσφατες μελέτες και η αναζήτηση δεδομένων για την ομάδα ασθενών που θα ωφεληθεί περισσότερο από την προσέγγιση αυτή.

### Λέξεις ευρετηριασμού

Ανδρογονικός  
αποκλεισμός,  
διακοπτόμενος, καρκίνος  
προστάτη

## References

- Boyle P, Ferlay J. Cancer incidence and mortality in Europe, 2004. *Ann Oncol* 2005, 16(3): 481 - 8
- Jemal A, Siegel R, Ward E, Hao Y, Xu J, Murray T, et al. Cancer statistics, 2008. *CA Cancer J Clin* 2008, 58(2): 71 - 96
- Huggins C, Hodges CV. Studies on prostatic cancer: I. The effect of castration, of estrogen and of androgen injection on serum phosphatases in metastatic carcinoma of the prostate. 1941. *J Urol* 2002, 168(1): 9 - 12
- Schally AV, Kastin AJ, Arimura A. Hypothalamic follicle-stimulating hormone (FSH) and luteinizing hormone(LH)-regulating hormone: structure, physiology, and clinical studies. *Fertil Steril* 1971, 22(11): 703 - 21
- Klotz LH, Herr HW, Morse MJ, Whitmore WF Jr. Intermittent endocrine therapy for advanced prostate cancer. *Cancer* 1986, 58(11): 2546 - 50. Erratum in *Cancer* 1987, 59(10): 43
- Bruchovsky N, Rennie PS, Coldman AJ, Goldenberg SL, To M, Lawson D. Effects of androgen withdrawal on the stem cell composition of the Shionogi carcinoma. *Cancer Res* 1990, 50(8): 2275 - 82
- Akakura K, Bruchovsky N, Goldenberg SL, Rennie PS, Buckley AR, Sullivan LD. Effects of intermittent androgen suppression on androgen-dependent tumors. Apoptosis and serum prostate-specific antigen. *Cancer* 1993, 71(9): 2782 - 90
- Zlotta A, Debruyne FMJ. Expert opinion on optimal testosterone control in prostate cancer. *Eur Urol Suppl* 2005, 4(8): 37 - 41
- Oefelein MG, Feng A, Scolieri MJ, Ricchiutti D, Resnick MI. Reassessment of the definition of castrate levels of testosterone: implications for clinical decision making. *Urology* 2000, 56(6): 1021 - 4
- Abrahamsson PA. Potential benefits of intermittent androgen suppression therapy in the treatment of prostate cancer: a systematic review of the literature. *Eur Urol* 2010, 57(1): 49 - 59
- Bruchovsky N, Klotz L, Crook J, Malone S, Ludgate C, Morris WJ, et al. Final results of the Canadian prospective phase II trial of intermittent androgen suppression for men in biochemical recurrence after radiotherapy for locally advanced prostate cancer: clinical parameters. *Cancer* 2006, 107: 389 - 95
- de La Taille A, Zerbib M, Conquy S, Amsellem - Ouazana D, Thiounn N, Flam TA, et al. Intermittent androgen suppression in patients with prostate cancer. *BJU Int* 2003, 91: 18 - 22
- Pether M, Goldenberg SL, Bhagirath K, Gleave M. Intermittent androgen suppression in prostate cancer: an update of the Vancouver experience. *Can J Urol* 2003, 10: 1809 - 14
- Prapotnich D, Fizazi K, Escudier B, Mombet A, Cathala N, Vallancien G. A 10-year clinical experience with intermittent hormonal therapy for prostate cancer. *Eur Urol* 2003, 43: 233 - 40, discussion 239 - 40
- Spry NA, Kristjanson L, Hooton B, Hayden L, Neerhut G, Gurney H, et al. Adverse effects to quality of life arising from treatment can recover with intermittent androgen suppression in men with prostate cancer. *Eur J Cancer* 2006, 42: 1083 - 92
- Grossfeld GD, Small EJ, Carroll PR. Intermittent androgen deprivation for clinically localized prostate cancer: initial experience. *Urology* 1998, 51: 137 - 44
- Malone S, Perry G, Eapen L, Segal R, Gallant V, Dahrouge S, Crook J, et al. Mature results of the Ottawa phase II study of intermittent androgen-suppression therapy in prostate cancer: clinical predictors of outcome. *Int J Radiat Oncol Biol Phys* 2007, 68: 699 - 706
- Youssef E, Tekyi-Mensah S, Hart K, Bolton S, Forman J. Intermittent androgen deprivation for patients with recurrent/metastatic prostate cancer. *Am J Clin Oncol* 2003, 26: 119 - 23
- Shaw GL, Wilson P, Cuzick J, Prowse DM, Goldenberg SL, Spry NA, et al. International study into the use of intermittent hormone therapy in the treatment of carcinoma of the prostate: a meta-analysis of 1446 patients. *BJU Int* 2007, 99(5): 1056 - 65
- Bouchot O, Lenormand L, Karam G, Prunet D, Gaschignard N, Malinovsky JM, et al. Intermittent androgen suppression in the treatment of metastatic prostate cancer. *Eur Urol* 2000, 38(5): 543 - 9
- Sato N, Akakura K, Isaka S, Nakatsu H, Tanaka M, Ito H, et al. Intermittent androgen suppression for locally advanced and metastatic prostate cancer: preliminary report of a prospective multicenter study. *Urology* 2004, 64(2): 341 - 5
- Klotz L, Toren P. Androgen deprivation therapy in advanced prostate cancer: is intermittent therapy the new standard of care? *Curr Oncol* 2012, 19(Suppl 3): S13 - 21
- Sciarra A, Abrahamsson PA, Brausi M, Galsky M, Mottet N, Sartor O, et al. Intermittent androgen - deprivation therapy in prostate cancer: a critical review focused on phase 3 trials. *Eur Urol* 2013, 64(5): 722 - 30
- Calais da Silva FE, Bono AV, Whelan P, Brausi M, Marques Queimadelos A, Martin JA, et al. Intermittent androgen deprivation for locally advanced and metastatic prostate cancer: results from a randomised phase 3 study of the South European Urooncological Group. *Eur Urol* 2009, 55(6): 1269 - 77
- Salonen AJ, Taari K, Ala - Opas M, Viitanen J, Lundstedt S, Tammela TL. Advanced prostate cancer treated with intermittent or continuous androgen deprivation in the randomised FinnProstate Study VII: quality of life and adverse effects. *Eur Urol* 2013, 63(1): 111 - 20
- Mottet N, Van Damme J, Loulidi S, Russel C, Leitenberger A, Wolff JM. Intermittent hormonal therapy in the treatment of metastatic prostate cancer: a randomized trial. *BJU Int* 2012, 110(9): 1262 - 9
- Hussain M, Tangen CM, Berry DL, Higano CS, Crawford ED, Liu G, et al.



- Intermittent versus continuous androgen deprivation in prostate cancer. *N Engl J Med* 2013, 368(14): 1314 - 25
28. Crook JM, O'Callaghan CJ, Duncan G, Dearnaley DP, Higano CS, Horwitz EM, et al. Intermittent androgen suppression for rising PSA level after radiotherapy. *N Engl J Med* 2012, 367(10): 895 - 903
  29. Calais da Silva F, Calais da Silva FM, Goncalves F, Santos A, Kliment J, Whelan P, et al. Locally advanced and metastatic prostate cancer treated with intermittent androgen monotherapy or maximal androgen blockade: Results from a randomised phase 3 study by the South European Urological Group. *Eur Urol* 2013. <http://dx.doi.org/10.1016/j.eururo.2013.03.055>
  30. Piaggio G, Elbourne DR, Altman DG, Pocock SJ, Evans SJ; CONSORT Group. Reporting of noninferiority and equivalence randomized trials: an extension of the CONSORT statement. *JAMA* 2006, 295(10): 1152 - 60
  31. Moynihan CM, Hayden KA, Thompson IM, Feigl P, Metch B. Quality of life assessment in Southwest Oncology Group trials. *Oncology (Williston Park)* 1990, 4(5): 79 - 84
  32. Verhagen PCMS, Wissenburg LD, Wildhagen MF, Bolle WABM, Verkerk AM, Schroder FH, et al. Quality of life effects of intermittent and continuous hormonal therapy by cyproterone acetate (CPA) for metastatic prostate cancer [abstract 541] *Eur Urol Suppl* 2008, 7: 206
  33. Gruca D, Bacher P and Tunn U. Safety and tolerability of intermittent androgen deprivation therapy: A literature review. *Int J Urol* 2012, 19: 624 - 5
  34. de Leval J, Boca P, Yousef E, Nicolas H, Jeukenne M, Seidel L, et al. Intermittent versus continuous total androgen blockade in the treatment of patients with advanced hormone-naïve prostate cancer: results of a prospective randomized multicenter trial. *Clin Prostate Cancer* 2002, 1: 163 - 71
  35. Gleave M, Klotz I, Taneja SS. The continued debate: intermittent vs. continuous hormonal ablation for metastatic prostate cancer. *Urol Oncol* 2009, 27: 81 - 6
  36. Keizman D, Huang P, Antonarakis ES, Sinibaldi V, Carducci MA, Denmeade S, et al. The change of PSA doubling time and its association with disease progression in patients with biochemically relapsed prostate cancer treated with intermittent androgen deprivation. *Prostate* 2011, 71: 1608 - 15
  37. Sciarra A, Cattarino S, Gentilucci A, et al. Predictors for response to intermittent androgen deprivation in prostate cancer patients with biochemical progression after surgery. *Urol Oncol* 2013, 31(5): 607 - 14
  38. Yu YJ, Gulati R, Telesca D, Jiang P, Tam S, Russell KJ, et al. Duration of first off-treatment interval is prognostic for time to castration resistance and death in men with biochemical relapse of prostate cancer treated on a prospective trial of intermittent androgen deprivation. *J Clin Oncol* 2010, 28: 2668 - 73
  39. Langenhuijzen JF, Badhauser D, Schaaf B, Kiemeny LA, Witjes JA, Mulders PF. Continuous vs. intermittent androgen deprivation therapy for metastatic prostate cancer. *Urol Oncol* 2013, 31(5): 549 - 56
  40. Benaim EA, Pace CM, Lam PM, Roehrborn CG. Nadir prostate-specific antigen as a predictor of progression to androgen-independent prostate cancer. *Urology* 2002, 59: 73 - 8
  41. Heidenreich A, Bastian PJ, Bellmunt J, Bolla M, Joniau S, Mason MD, et al. Guidelines on prostate cancer. European Association of Urology Web site. [http://www.uroweb.org/gls/pdf/09\\_Prostate\\_Cancer\\_LR.pdf](http://www.uroweb.org/gls/pdf/09_Prostate_Cancer_LR.pdf)
  42. Prostate cancer. Guidelines for the management of clinically localized prostate cancer: 2007 update. American Urological Association Web site. <http://www.auanet.org/education/guidelines/prostate-cancer.cfm>
  43. Loblaw DA, Virgo KS, Nam R, Somerfield MR, Ben - Josef E, Mendelson DS, et al. American Society of Clinical Oncology. Initial hormonal management of androgen-sensitive metastatic, recurrent, or progressive prostate cancer: 2006 update of an American Society of Clinical Oncology practice guideline. *J Clin Oncol* 2007, 25: 1596 - 605
  44. Mohler JL, Kantoff PW, Armstrong AJ, Bahnon RR, Cohen M, D'Amico AV, et al. Prostate cancer, version 1.2014. *J Natl Compr Canc Netw* 2013, 11: 1471 - 9



## CASE REPORT

# Leiomyoma of the epididymis

Michael Platanas, Ioannis Solinis, Eftichios Stavroulakis  
*Department of Urology, General Hospital of Didymoteicho, Evros, Greece*

## Abstract

Neoplasms of the epididymis are distinguished into benign and malignant, are very rare and are frequently diagnosed as benign

neoplasms. Leiomyomas are benign tumors that may arise from any structure or organ containing smooth muscle fibers.

## Introduction

The majority of the leiomyomas in the genitourinary system has been detected in the renal capsule but leiomyomas are also reported to have been found in the epididymis, the seminiferous cord and the tunica albuginea.

The ultrasonography is an imaging technique for the assessment of the scrotum's pathology; however, the ultrasonographic depiction of leiomyomas emerging from the tunica albuginea has been rarely reported.

## Case report

A 68-year-old male patient presented to the Department of Urology with deterioration of his scrotum swelling. The swelling, noticed by the patient himself approximately 2 years earlier, was painless, exhibited gradual enlargement and was occasionally accompanied by a mild discomfort in the ipsilateral groin area. The patient's personal history was free.

The clinical examination revealed induration of the right testis and oedema in its lower pole at the tail of the right epididymis. The performed blood and biochemical investigation showed no pathological findings. The b-HCG, a-fetoprotein and LDH were

negative. The ultrasound imaging of the scrotum revealed an oval-shaped mass of inhomogenous composition measuring 3 cm in diameter with localized necrosis in the lower pole – a finding compatible with neoplasm at the tail of the epididymis.

Also, the ultrasound examination depicted presence of ipsilateral hydrocele. Our patient was subjected to resection of the right epididymis lesion. The patient's post-operative

recovery and hospitalization had no particular problems.

Macroscopically, the histopathological study showed a whitish solid elastic tumor measuring approximately 4 cm in diameter; microscopically, the study revealed a tumor composed of smooth muscle fibers.

## Discussion

The review of the American and European literature shows that the leiomyoma is the second most common neoplasia of the epididymis representing 6% of its primary tumors.

In 1972, Albert και Mininberg reported the first case of leiomyoma in the scrotum. The literature contains 17 cases reported in the past. The 5th decade (40 to 49 years old) is the characteristic

## Key words

Leiomyoma,  
epididymis,  
testicle

## Corresponding author:

Michael Platanas, Aitolias 48, POB 15341, Ag. Paraskevi, Athens, Tel: +3025530 44113, E-mail: mplatanas@yahoo.gr

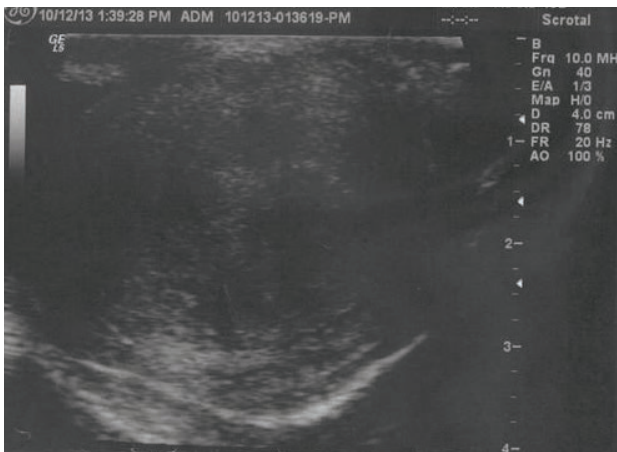
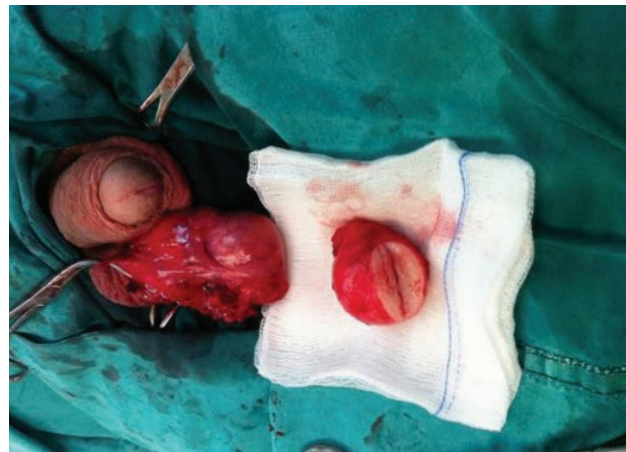
Figure 1. Ultrasound imaging of the scrotum: An oviform inhomogeneous mass of 3 cm in diameter with central necrosis localized in the lower pole of the right testicle




Figures 2. Intra-operative image of the tumor: a whitish solid elastic tumor of 4 cm in diameter displaying macroscopically benign characteristics

mostly shared among leiomyoma patients. The tumors in question progress particularly slowly.

### Conclusion

Leiomyoma is a very rare neoplasia. It is very difficult

to form an accurate pre-operative diagnosis and for this reason the patient is usually referred to surgery for the investigation of the mass. The histological study is the only examination that can establish a safe diagnosis. 

## Περίληψη

Τα νεοπλασμάτα της επιδιδυμίδας διακρίνονται σε καλοήθη και κακοήθη, είναι πολύ σπάνια και μεταξύ αυτών συχνότερα διαγιγνώσκονται τα καλοήθη νεοπλασμάτα. Τα λειομύωματα είναι καλοήθη νεοπλασμάτα που μπορεί να προκύψουν από οποιαδήποτε δομή ή όργανο περιέχει λείες μυϊκές ίνες.

**Λέξεις  
ευρετηριασμού**  
Λειομύωμα,  
επιδιδυμίδα, όρχις

## References

1. Siegal GP, Gaffey TA: Solitary leiomyomas arising from the tunica dartos scroti. J Urol 1976, 116:69.
2. Chiong E, Tan KB, Siew E, Rajwanshi A, See H, Esuvaranathan K: Uncommon benign intrascrotal tumours. Ann Acad Med Singapore 2004, 33:351.
3. Ragsdale BD: Tumours of fatty, muscular and osseous tissue: fat as a tissue, an organ and a source of tumors. In Lever's Histopathology of the Skin. 8th edition. Edited by Elder D, Elenitsas R, Jaworsky C, Johnson B Jr. Philadelphia, PA: Lippincott-Raven; 1997:457-502.
4. Holstein AF, Otlandini GE, Baumgarten HG: Morphological analysis of tissue components in the tunica dartos of man. Cell Tissue Res 1974, 154:329.
5. Das AK, Bolick D, Little NA, Walther PJ: Pedunculated scrotal mass: leiomyoma of scrotum. Urology 1992, 39:376.
6. Sherwani RK, Rahman K, Akhtar K, Zaheer S, Hassan MJ, Haider A: Leiomyoma of scrotum. Indian J Pathol Microbiol 2008, 51:72.
7. Belis JA, et al.: Genitourinary leiomyomas. Urology 1979, 13(4):424-9.
8. Borri A, et al.: Bizarre leiomyoma of the epididymis. A case report. Minerva Urol Nefrol 2000, 52(1):29-31.
9. De Rosa G, et al.: Symplastic leiomyoma of the scrotum. A case report. Pathologica 1996, 88(1):55-7.
10. Robboy SJ, et al.: Pathology and pathophysiology of uterine smooth-muscle tumours. Environ Health Perspect 2000, 108(Suppl 5):779-84.
11. Habuchi T, et al.: Leiomyoma of the scrotum: a case report and sonographic





- findings. *Hinyokika Kyo* 1990; 36(8):959 - 62.
12. Kim NR, et al.: Bizarre leiomyoma of the scrotum. *J Korean Med Sci* 2003; 18(3):452 - 4.
  13. Cabello Benavente R, et al.: Giant bizarre scrotal leiomyoma. *Arch Esp Urol* 2004; 57(8):847 - 51.
  14. Sevilla Chica F, et al.: Atypical or bizarre leiomyoma of the scrotum. Report of one case and bibliographic review. *Arch Esp Urol* 2004; 57(4):428 - 31.
  15. Slone S, et al.: Scrotal leiomyomas with bizarre nuclei: a report of three cases.
  16. Belis JA, Post GJ, Rochman SC, Milan DF. Genitourinary leiomyomas. *Urology* 1979;13:424.
  17. Chiamonte RM. Leiomyoma of tunica albuginea of testis. *Urology* 1988;31:344 - 5.
  18. Albert PS, Mininberg DT. Leiomyoma of tunica albuginea. *J Urol* 1972;107:869 - 71.
  19. Honore LH, Sullivan LD. Intratesticular leiomyoma: a case report with discussion of differential diagnosis and histogenesis. *J Urol* 1975;114:631 - 5.
  20. Bitker MO, Leo JP, Jardin A, Chatelain Ch. Les tumeurs rares du testicule. A propos de quinze observations. *Ann Urol* 1986;20:238-243. [in French].
  21. Nino-Murcia M, Kosek J. Leiomyoma of the testis: sonographic and pathologic findings. *J Can Assoc Radiol* 1989;40:178-9.
  22. Takahashi G, Takahashi H. Intratesticular leiomyoma: a case report. *Acta Urol Jpn* 1991;37:1551 - 3.
  23. Thomas J, Rifkin M, Nazeer T. Intratesticular leiomyoma of the body of the testis. *J Ultrasound Med* 1998;17:785 - 7.
  24. Destito A, Servello C, Pisanti F, Pierconti F, Candidi MO, Lacquaniti S. Leiomyoma of the testis. *Scand J Urol Nephrol* 1999;33:338 - 9.
  25. Remzi D. Tumors of the tunica vaginalis. *South Med J* 1973;66:841 - 2.
  26. Lia-Beng T, Wei-Wuang H, Biing-Rorn C, Chia-Chun T. Bilateral synchronous leiomyomas of the testicular tunica albuginea. A case report and review of the literature. *Int Urol Nephrol* 1996;28:549 - 552.
  27. Richie JP, Steele GS. Neoplasms of the testis, Chapt.81, In: Kavoussi LR, Novick AC, Partin AW, Peters CA, eds. *Campbell's urology*, 8th ed., Philadelphia, PA: Elsevier Science, 2003;2876 - 919.
  28. Maria NS, Emilia R: Leiomyoma of the tunica albuginea. *Urologia* 1979; 46: 768.
  29. Aus G, Boiesen PT. Bilateral leiomyoma of the tunica albuginea. *Scand J Urol Nephrol* 1991;25:79 - 80.
  30. Heidenreich A, Moul JW, Srivastava S, Engelmann UH. Synchronous bilateral testicular tumour nonseminomatous germ cell tumours and contralateral benign tumours. *Scand J Urol Nephrol* 1997;31:389 - 92.
  31. Longchamps E, Carriou G, Arborio M, Skrobala E, Brouland J, Cochand-Priollet B. Le leiomyome intratesticulaire: une localisation exceptionnelle. *Ann Pathol* 1998;18:418 - 21. [In French].
  32. Gonzalez CM, Victor TA, Bourtsos E, Blum MD. Monoclonal antibody confirmation of a primary leiomyoma of the testis. *J Urol* 1999;161:1908.
  33. Mak CW, Tzeng WS, Chou CK, Chen CY, Chang JM, Tzeng CC. Leiomyoma arising from the tunica albuginea of the testis: sonographic findings. *J Clin Ultrasound* 2004;32:309 - 11.
  34. Chiong E, Tan KB, Siew E, Rajwanshi A, Esuvaranathan K. Uncommon benign intrascrotal tumors. *Ann Acad Med Singapore* 2004; 33:351 - 5.
  35. Beccia D J, Krane R J, Olsson C A. Clinical management of nontesticular intrascrotal tumors. *J Urol* 1976; 116: 476.
  36. Tammela T L J, Karttunen T J, Makarainen H P et al. Intrascrotal adenomatoid tumors. *J Urol* 1991; 146: 61.
  37. Nistal M, Contreras F, Paniagua R. Adenomatoid tumour of the epididymis: Histochemical and ultrastructural study of 2 cases. *Br J Urol* 1978; 50: 121.
  38. Delahunt B, King J N, Bethwaite P B et al. Immuno-histochemical evidence for mesothelial origin of para-testicular adenomatoid tumour. *Histopathology* 2000; 36: 109 - 115.
  39. Lee J C, Bhatt S, Dogra V S, Imaging of the Epididymis *Ultrasound Quarterly* March 2008; Volume 24 (1).
  40. Akbar SA, Sayyed TA, Neil JS A: Multimodality Imaging of Para testicular Neoplasms and their rare mimics *Radiographics* Nov 2003.
  41. Woodward P J, Schwab C M, Sesterhenn I A, From the Archives of AFIP: extratesticular scrotal masses: radiologic-pathologic correlation. *Radiographics* 2003; 23:215 - 240.
  42. Klerk D P, Nime F. Adenomatoid tumor (mesothelioma) of testicular and paratesticular tissue. *Urology* 1975; 6: 635 (s).
  43. Manson A L. Adenomatoid tumor of the testicular tunica albuginea mimicking testicular carcinoma *J Urol* 1988; 139: 819-820 (s).
  44. Mazella F M, Sieber S C, Lopez V. Histiocytous Hemangioma of the testis. *J Urol* 1995; 153: 743 - 744 (s).
  45. Shveta G, Mathew M. Adenomatoid Tumor of Tunica Albuginea Mimicking a Testicular Neoplasm. *The Internet Journal of Urology* 2007; 4(2).



## CASE REPORT

# Renal artery thrombosis as a result of blunt abdominal trauma

Vasileios Klapsis, Konstantinos Bouropoulos, Nikolaos Ferakis, Iraklis Poulas  
Department of Urology, Hellenic Red Cross Hospital 'Korgialeneio-Benakeio', Athens, Greece

### Abstract

Complete renal artery occlusion is a very rare complication of blunt abdominal trauma. An optimal treatment of this injury has not

been well established. We report a case of an isolated renal artery thrombosis in a young man following a motor vehicle accident.

### Introduction

Complete renal artery occlusion is a very rare complication of blunt abdominal trauma. Less than 400 cases have been reported in the literature<sup>1</sup>. It was initially described by Von Recklinghausen in 1861<sup>2</sup>. The optimal treatment of this injury has not been well established. There are three therapeutic options: immediate surgical revascularization, percutaneous revascularization and conservative treatment<sup>1</sup>.

### Case Report

A 34 - year - old male was admitted to the hospital after a motorcycle accident. He was transported to the hospital 1 hour after the accident. On arrival at the emergency department the patient complained for left flank and left femoral pain. Physical examination revealed a systolic blood pressure of 80 mm Hg, a heart rate of 98 beats per minute and a respiration rate of 18 breaths per minute. He had contusions extended from his left flank to the iliac region. He also had a large hematoma in his left thigh. Focused assessment with sonography

for trauma (FAST) was negative and he had no other indication for immediate laparotomy. His hemoglobin was 10,5 gr/dl. X - ray films revealed a left femoral fracture. Enhanced computed tomography scans (CT) were obtained from the chest to the pelvis after hemodynamic stabilization. There was a normal contrast uptake from the right kidney but no uptake from the left kidney, although no damage of the left renal parenchyma was observed (**Figure**

**1**). Subsequently arteriography was performed in order to evaluate the left renal artery, which revealed a total occlusion of the vessel about 3cm from the aorta (**Figure 2**). Conservative management of this injury was decided and an external fixation of the femoral fracture was applied. CT scan two days

later demonstrated a limited contrast enhancement in the inner side of the upper pole of the right kidney (**Figure 3**).

### Discussion

The complete traumatic renal artery occlusion is a

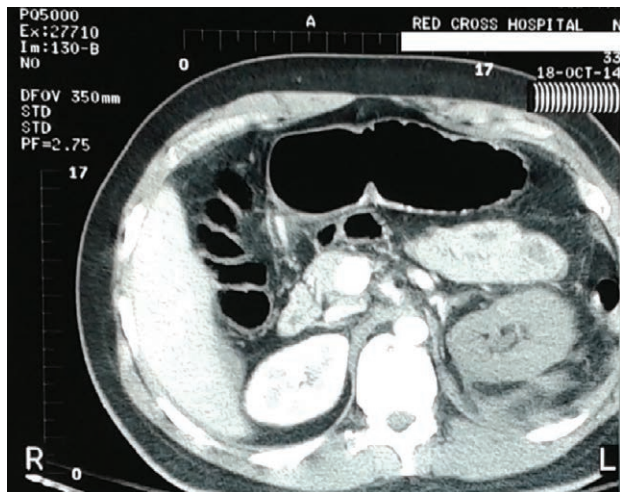


### Key words

Renal artery thrombosis, blunt trauma, endovascular stent

### Corresponding author:

Konstantinos Bouropoulos, Hellenic Red Cross Hospital 'Korgialeneio-Benakeio', Department of Urology, Athanasaki 1, 11526, Athens, E- mail: cbourop@gmail.com

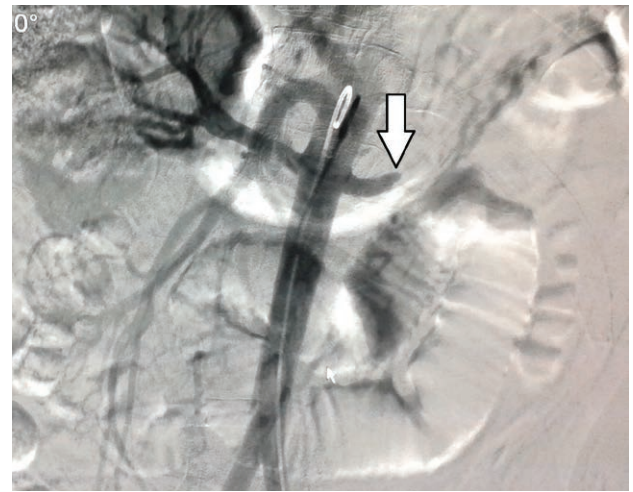

**Figure 1.** Contrast -enhanced CT scan of the abdomen, which shows no contrast uptake from the left kidney

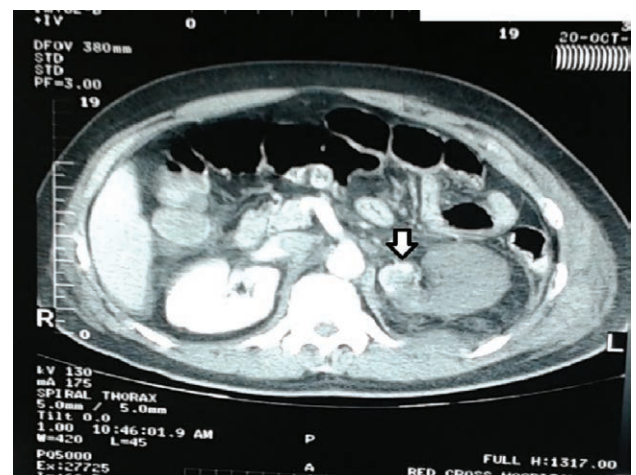
very rare condition. According to the literature its incidence is lower than 0.1% among patients with blunt abdominal trauma<sup>1,3</sup>. The left side is reported to be slightly more prone to injury<sup>4</sup>. Its occurrence requires a high velocity blunt trauma and the vast majority of the patients have other life threatening associated injuries, the treatment of which takes a priority. The main injury mechanisms are acceleration/ deceleration trauma or direct impact trauma. Intimal tear followed by subintimal dissection, thrombosis and compression of the renal vessels between the anterior abdominal wall and the vertebral bodies are the two suggested associated causes<sup>1</sup>.

The physical examination is not sensitive in establishing the diagnosis of a renal artery occlusion. Computed tomography scan is the study of choice. Although the condition is rare, its incidence is been increasing due to the use of CT in the evaluation of abdominal trauma. A high index of suspicion together with high quality imaging is necessary for early detection. The management of traumatic renal artery occlusion remains controversial and no generally accepted treatment has been established. In the literature the following treatment options have been described: immediate surgical revascularization, percutaneous revascularization and conservative treatment<sup>1-4</sup>. Complications of an infracted kidney include delayed development of hypertension or infection.

In the acutely obstructed normal kidney angiography will not usually demonstrate collateral



**Figure 2.** Complete occlusion of the left renal artery as shown in the arteriogram



**Figure 3.** CT scan two days later demonstrates a limited contrast enhancement in the inner side of the kidney

flow. However, after several days collateral circulation is developed. This circulation is from lumbar, adrenal, intercostals, gonadal and ureteric vessels<sup>5</sup>. In our case three days after the injury CT showed a small region of contrast enhancement in the inner renal side.

In the past the treatment of choice described in the literature was the surgical revascularization. The procedures include thrombectomy with vein patch angioplasty, excision of the thrombosed segment and end - to - end anastomosis, aortorenal bypass and autotransplantation<sup>1</sup>. The main purpose of revascularization is to preserve sufficient renal function and prevent renovascular hypertension. The crucial factors for successful revascularization are the time of warm ischemia and the extent of the


vessel lesion. An accepted time of warm ischemia used to be 4 hours but a multicenter study of the Western Trauma Association showed that the outcome in terms of prevention of the renal function of these patients was not better than those who were treated later<sup>3</sup>. Haas et al, have reviewed the literature and identified 139 patients with unilateral renal artery occlusion<sup>6</sup>. Surgical revascularization was attempted in 34 patients and was successful in 9 (26%). 67% of these patients had decreased renal function at a mean follow - up of 1.8 years and 12% experienced hypertension at a mean 3.1 years follow up. The poor outcomes of this technique, even when surgeons report it to be technically successful may be due to the presence of peripheral thrombi which are undetectable during the operation. Another drawback of this therapy option is that the majority of the patients have other life threatening injuries, the management of which takes priority. Revascularization is indicated in patients with bilateral lesions and in those with solitary kidney.

Renovascular hypertension remains a major concern with the conservative approach. Rates of hypertension in blunt renal artery patients range from 3 to 30% in different series<sup>1-4</sup>. The hypertension is mediated via renin hypersecretion from the affected kidney and may normalize spontaneously, or may be controlled medically or progress to severe hypertension that necessitates delayed nephrectomy. Haas CA et al, reviewed retrospectively treatment outcomes and complications of 12 patients (13 injuries)<sup>7</sup>. Seven patients did not have revascularization and none of them experienced immediate complications. 5 of 12 underwent surgical revascularization and one of them required nephrectomy because of the inability to restore arterial flow, 3 had no renal function and 1 had 9% of renal function in postoperative renal scan. Hypertension was developed in 3 patients who required nephrectomy for blood pressure control at a mean 5 months after injury.

Another treatment option with recently growing

interest is the percutaneous revascularization with endovascular stent placement in stable patients, first described from Whigham et al, in 1995<sup>8</sup>. There are still no adequate data in the literature in order to evaluate the long-term results of this method. Abu - Gazala et al, have reviewed the literature, identifying 14 patients with blunt renal artery injury treated endovascularly<sup>4</sup>. Of these patients, 4 had complete renal artery stenosis. Two of those had markedly reduced renal function as shown in DTPA scan, and two of them developed renovascular hypertension, necessitating delayed nephrectomy in one of them. Kushimoto et al. have reported a case of a patient treated with endovascular stent placement and simultaneous suction of peripheral thrombi and thrombolysis with urokinase, followed by selective continuous heparinization<sup>3</sup>. The need to administer anticoagulant factors in trauma patients in order to ensure the stent patency is a major drawback of this technique.

Conservative treatment is indicated in unilateral cases with the presence of a normal contralateral kidney. Jawas et al, have suggested a treatment algorithm for traumatic renal artery occlusion, suggesting conservative approach of stable patients with unilateral lesions, whether they have indication for immediate laparotomy for other associated injuries or not<sup>1</sup>. About 25 - 50% of these patients will develop hypertension. It may be controlled medically or progress to severe hypertension. Among the 147 conservatively treated patients reviewed by Haas et al., hypertension developed in 34 (32%) and was present by a mean of 97 days postinjury<sup>5</sup>. Delayed nephrectomy is reserved for those with drug-resistant hypertension or in order to prevent infection of the necrotic tissue.

In conclusion, traumatic renal artery occlusion in trauma patients is a rare condition, the optimal treatment of which has not been yet established. Revascularization seldom results in a successful outcome. Patients who were managed conservatively must have close follow up for hypertension. 



## Περίληψη

Η πλήρης απόφραξη της νεφρικής αρτηρίας είναι μια σπάνια επιπλοκή αμβλείας κάκωσης της κοιλιάς. Η ιδανική θεραπεία αυτής της κάκωσης δεν έχει ακόμα καθιερωθεί. Αναφέρουμε μία περίπτωση θρόμβωσης της νεφρικής αρτηρίας σε νέο άνδρα μετά από τροχαίο ατύχημα.

**Λέξεις  
ευρετηριασμού**  
Θρόμβωση νεφρικής  
αρτηρίας, αμβλεία  
κάκωση, ενδαγγειακή  
πρόθεση

## References

1. Jawas A, Abu - Zidan FM. Management of algorithm of complete blunt renal artery occlusion in multiple trauma patients: Case series. *Int J Surg* 2008;6:317 - 2
2. Negoro H, Iwamura H, Oka H, Kawakita M, Ariyoshi K, Koda Y, Imai Y. Traumatic renal artery thrombosis with renovascular hypertension. *Int J Urol* 2004;11:903 - 5
3. Kushimoto S, Shiraiishi S - I, Miyauchi M, Tanabe S, Fukuda R, Tsujii A, et al. Traumatic renal artery occlusion treated with an endovascular stent. The limitations of surgical revascularization: Report of a case. *Surg Today* 2011;41:1020 - 3
4. Abu-Gazala M, Shussman N, Abu-Gazala S, Elazary R, Bala M, Rozenberg S, Klimov A, Rivkind A, Arbell D, Almogy G, Bloom A. Endovascular management of blunt renal artery trauma. *IMAJ* 2013;15:278 - 3
5. Flye Wayne M, Anderson RW, Fish JC, Silver D. Successful Surgical Treatment of Anuria Caused By Renal Artery Occlusion. *Am Surg* 1982; 195(3):346 - 353
6. Haas CA, Spirnak JP. Traumatic renal artery occlusion: a review of the literature. *Tech Urol* 1998;4(1):1 - 11
7. Haas CA, Dinchman KH, Nasrallah PF, Spirnak JP. Traumatic renal artery occlusion: a 15 - year review. *JTrauma* 1998;45(3):557 - 561
8. Whigan CJ, Bodenamer JR, Miller JK. Palmaz stent in primary treatment of renal artery intimal injury secondary to blunt trauma. *J Vasc Interv Radiol* 1995;6:571 - 2

## REVIEW

# Retroperitoneal Fibrosis: Review of modern literature

Marios Stavropoulos<sup>1</sup>, Athanasios G. Papatsoris<sup>2</sup><sup>1</sup>Department of Urology, Hellenic Red Cross Hospital, Athens, Greece<sup>2</sup>Second University Department of Urology, Sismanoglio General Hospital, Athens, Greece

## Abstract

Retroperitoneal fibrosis (RPF) is a rare disease characterized by the presence of an extensive inflammatory fibrotic mass in the retroperitoneum. The aorta, inferior vena cava (IVC) and iliac vessels are usually involved. Ureteral obstruction is observed in most of the cases. Recently, RPF is reported to belong to IgG4-related diseases, which is proposed as a new clinical entity.

Imaging studies play a primary role in the diagnosis of RPF, with the CT scan being the modality of choice. Glucocorticoids are the mainstay of treatment, used either as monotherapy or in combination with other agents. If conservative measures fail, surgical intervention is necessary. Recently, minimally invasive techniques have been applied.

## Introduction

Retroperitoneal fibrosis (RPF) is a rare disorder characterized by fibroinflammatory tissue surrounding the abdominal aorta and the iliac arteries<sup>1</sup>. This process may extend into the retroperitoneum and envelop adjacent structures, often ureters. It is thought that this disease has been first described by the French urologist Albarran in 1905, but the description of two cases by Ormond in 1948 established RPF as a clinical entity<sup>2,3</sup>. Although its true incidence is unknown, estimates range from one case per 200,000 to 500,000 individuals per year<sup>4</sup>. However, other studies raise its annual incidence up to 1.3/100,000 inhabitants<sup>5</sup>. There are idiopathic and secondary forms of RPF, with the former

accounting for over 70% of cases. Idiopathic disease (also called Ormond's disease) most commonly occurs in individuals 40 to 60 years of age, with a 2 to 3:1 male to female predominance. Rare pediatric reports have been described. There is no evidence of an ethnic predisposition or a familiar pattern of this disease<sup>6,7</sup>. The objective of this review was to emphasize on the recent developments in the pathophysiology, diagnosis and treatment of RPF published in current literature.

## Key words

**Retroperitoneal fibrosis, Ormond's disease, IgG4, glucocorticoids**

## Materials and Methods

An electronic database (i.e. PubMed) literature search was performed by using relevant key words, such as retroperitoneal fibrosis, Ormond's disease,

## Corresponding author:

Marios Stavropoulos, Department of Urology, Hellenic Red Cross Hospital, Erythrou Stavrou & Athanasaki 1, 115 26 Athens, Greece, E-mail: mastav1@hotmail.com, Tel: +302132068744, Fax: +302132068744



chronic periaortitis or IgG4 - related retroperitoneal fibrosis (alone or in combination). Both retrospective and prospective studies were analyzed. The selected journals were written in English and the majority of the articles were published during the last decade.

### Etiology

Secondary RPF may be a result of: aortic aneurysm, previous radiation therapy, abdominal surgery, trauma, primary or metastatic neoplasms in the retroperitoneal space, infections (tuberculosis, histoplasmosis, actinomycosis) and drugs (ergotamine, methyldopa, beta-blockers, methysergide, bromocriptine, hydralazine)<sup>8</sup> (**Table 1**). However, the distinction between idiopathic and secondary forms of RPF is vague, since direct causal relationship between secondary cause and the disease is unclear and some authors consider these conditions (particularly surgery, radiation and drugs) as only predisposing factors<sup>9</sup>. Primary retroperitoneal neoplasms, such as lymphoma or sarcoma, and metastatic tumors, such as breast and colon cancer can also produce a desmoplastic reaction and thus mimic RPF<sup>10</sup>. RPF secondary to malignancy is of particular importance because of its poor prognosis and is estimated to account for 8% of cases<sup>7</sup>.

### Pathogenesis

Although the exact pathogenesis of RPF is poorly understood, it has been thought to be an exaggerated local inflammatory reaction to aortic atherosclerosis, incited by oxidized Low Density Lipoprotein (LDL)<sup>11</sup>. On the other hand, it seems that autoimmune mechanisms play a crucial part in the induction of chronic inflammation and fibrosis. It is difficult to state whether it is a localized process or just a manifestation of a systemic disease. However, the systemic mechanism of the disorder is suggested by the fact that RPF favorably responds to immunosuppressive agents and is often associated with autoimmune diseases, such as systemic lupus erythematosus, rheumatoid arthritis, vasculitides and autoimmune thyroid diseases. Additionally, concurrent fibrosis of additional organs (sclerosing cholangitis, Riedel's thyroiditis) and frequent raised concentrations of acute phase reactants and autoantibodies support this hypothesis<sup>9,12-16</sup>.

Lately, a novel clinical entity known as IgG4 related

TABLE 1	Major causes of secondary retroperitoneal fibrosis <sup>1</sup>
Drugs	Drugs Methysergide Pergolide Bromocriptine Ergotamine Methyldopa Hydralazine Analgesics Beta blockers
Malignant diseases	Carcinoid Hodgkin and non-Hodgkin lymphomas Sarcomas Carcinomas of the colon, prostate, breast, stomach
Infections	Tuberculosis Histoplasmosis Actinomycosis
Radiotherapy	Testicular seminoma Colon carcinoma Pancreatic carcinoma
Surgery	Lymphadenectomy Colectomy Hysterectomy Aortic aneurysmectomy
Others	Histiocytosis Erdheim-Chester disease Amyloidosis Trauma Barium enema

disease (IgG4RD) has been proposed to describe the group of autoimmune disorders involving connective tissue. This condition is characterized by elevated serum IgG4 concentration and tissue infiltration by IgG4 - positive plasma cells together with CD4+ or CD8+ T-lymphocytes, which can involve multiple organs. IgG4RD may be present in a certain proportion of patients with a wide variety of diseases including RPF. Chronic inflammatory and fibrotic changes may be present and can involve regional tissues. The diagnosis of IgG4 - RD in this setting can be challenging because of the advanced fibrotic changes typically observed in this condition. Although IgG4RD is a novel clinical entity, it is not a rare disease. The clinical diagnostic criteria for IgG4RD have not been established. Because it may occur in a variety of organs throughout the body, comprehensive discussions with the cooperation

of many clinicians from various specialized fields is needed to establish uniform diagnostic criteria. Consensus has been reached on two diagnostic criteria for IgG4RD: (1) serum IgG4 concentration >135 mg/dl and (2) > 40% of IgG - positive plasma cells being IgG4 - positive<sup>17-19</sup>.

The pathologic findings in idiopathic and secondary RPF are sometimes indistinguishable. Macroscopically, a hard white plaque of varying thickness is seen. A typical distribution of RPF includes the region around the abdominal aorta and inferior vena cava with spreading from the level of the renal hilum into the pelvis along the iliac vessels. There is no elevation of the aorta from the spine in the typical picture of RPF1. In several studies, unusual locations of RPF have been described such as: pelvic, perinephric, peripancreatic or periduodenal<sup>20</sup>. Microscopically, the inflammatory component consists of B and T lymphocytes, plasma cells, macrophages and scattered eosinophils while fibroblasts and myofibroblasts compose a sclerotic matrix of type I collagen<sup>1,10</sup>.

### Clinical Presentation

The clinical manifestations of idiopathic or secondary RPF vary with the stage of presentation and are nonspecific, with the diagnosis often not considered until there is significant organ (more commonly kidney) involvement<sup>6</sup>. Early symptoms tend to be relatively nonspecific, most commonly abdominal or lumbar discomfort. Other nonspecific symptoms include weight loss, malaise, anorexia, nausea, testicular pain, edema and gross hematuria<sup>9</sup>. As the degree of fibrosis progresses, the compressive effects of the abnormal soft - tissue mass determine symptomatic evolution. Lower extremity edema and/or thrombophlebitis or deep vein thrombosis may result from obstruction of the inferior vena cava and/or iliac veins. Arterial compromise of the lower extremities and mesenteric arteries may result in claudication and intestinal ischemia, respectively<sup>21</sup>. Swelling of the scrotum, varicocele or hydrocele may also be present. Constitutional and non - specific GI symptoms are common<sup>1</sup>. Flank pain becomes acute and colicky with ureteral involvement. Due to nonspecific finding, patients can present with renal failure secondary to obstructive uropathy and

long - standing hydronephrosis before the correct diagnosis is made. Ureteral involvement is reported in 80 - 100% of cases and indeed the late stage of RPF is characterized by progressive ureteral obstruction, bilateral in over half of RPF cases. Physical examination is generally unremarkable with the exception of hypertension, probably of renal origin<sup>7,22</sup>.

### Diagnosis

The presence of RPF is often detected as a part of the evaluation for urinary tract obstruction. Imaging studies play a primal role. Commonly used modalities include ultrasonography, intravenous urography, CT scanning and magnetic resonance imaging (MRI).

RPF may be identified as a hypoechoic or anechoic, poorly marginated periaortic mass on sonography. Varying degrees of hydronephrosis are usually seen. It is often the first procedure performed because of its common use to detect possible urinary tract obstruction in patients with unexplained renal insufficiency and also its low cost. However, the overall sensitivity of sonography in the detection of RPF is poor; only 25% of affected patients in whom disease is identified on CT scanning present a corresponding abnormality on sonography<sup>6</sup>.

Because ureteral obstruction is a common result of RPF, intravenous urography, retrograde or percutaneous antegrade pyelography may be used to outline the site and severity of obstruction<sup>6</sup>. When performing intravenous urography, diagnosis usually relies on the presence of delayed renal contrast excretion with unilateral (20% of cases) or bilateral (68% of cases) hydronephrosis and proximal hydroureter secondary to ureteral involvement and medial deviation of the middle third of both ureters at the L3 - L4 vertebral level<sup>20</sup>.

However, nowadays these tests are rarely used; CT and MRI have become the mainstays of diagnosis. CT scanning may provide comprehensive evaluation of RPF location, extent and effect of the plaque on adjacent organs and vascular structures. It may also allow to assess the presence of the underlying cause (e.g lymphadenopathy, tumor, abdominal aortic aneurysm). RPF usually presents as a paraspinal, well-demarcated but irregular retroperitoneal mass that is isodense to psoas muscle. The mass usually surrounds the anterior and lateral sides of the aorta and iliac





vessels. Medial deviation and extrinsic compression of the ureters are usually seen. Significant extension of the inflammatory process may occur and other abdominal structures such as the IVC can similarly become enveloped<sup>1,6,7,9,10</sup>. The degree of soft-tissue enhancement with contrast correlates with the activity of the fibrotic process. Great enhancement may be observed in the early, acute stages of the disease, whereas little or no enhancement may be seen in a chronic, advanced condition. A larger and bulkier mass with a more cephalad distribution displacing the IVC and the aorta is thought to be associated with RPF of a malignant origin. However, the sensitivity and specificity of these features are poor and exceptions are encountered<sup>6,7</sup>.

MRI produces findings comparable to those with CT scanning. MRI provides the advantage of far superior soft - tissue contrast resolution to that of CT, while avoiding the need for the administration of iodinated contrast medium<sup>6,7</sup>. Particular consideration should be given however, in the administration of Gadolinium as a contrast agent, as it has been associated with a rare but severe disease called nephrogenic systemic fibrosis among patients with impaired renal function<sup>24,25</sup>. An inhomogeneous signal in T2 - weighted scan is proposed to be suggestive of a malignant process. However, as in the case of CT, the manifestation of malignant RPF on MRI may be variable and no definitive findings have been proven useful in the confident differentiation of benign from malignant RPF<sup>6,7,26</sup>.

Positron emission tomography (PET) with 18-F-fluorodeoxyglucose (18F-FDG) has been described as a very promising tool in the diagnosis of RPF. FDG-PET is a sensitive mean to assess metabolic activity of retroperitoneal lesions; however, it lacks specificity and cannot allow distinction between a benign and a malignant cause<sup>16,27</sup>. Nonetheless, FDG - PET has been successfully proposed for the evaluation of recurrent disease activity during follow-up and thus, tailoring future conservative or surgical interventions<sup>6,7,16,18,28-31</sup>.

Biopsy is not always performed, especially if radiological features predispose to RPF. However, if diagnostic dilemmas exist and an underlying malignancy is suspected or if there is no response to initial therapy, biopsy must be carried out in order

for the diagnosis to be confirmed. Biopsy may be performed either via an imaging - guided method or during a surgical procedure<sup>1,22</sup>.

### Therapy

The treatment strategy of RPF includes relief from the obstruction caused by fibrosis, preservation of renal function, suppression of the inflammatory process and prevention of recurrence. Several agents have been used for the treatment of idiopathic RPF, including glucocorticoids, other immunosuppressive agents and tamoxifen (a selective estrogen receptor modulator), used alone or in combination<sup>1,10,22</sup>. However, the optimal treatment regimen remains to be determined. Glucocorticoids are the mainstay of therapy. They can achieve prompt improvement of symptoms and often lead to a reduction in size of the retroperitoneal mass and resolution of obstructive complications. Drainage of the upper urinary tract may be required in patients presenting with renal failure or if one kidney is severely obstructed even if renal function is normal. Percutaneous nephrostomy tubes or ureteral double-J stents are the current preferable approach, providing short-term relief of symptoms until the effects of appropriate management occur. In most cases the initial approach will combine urinary tract decompression and medical therapy<sup>32,33</sup>.

Treatment with glucocorticoids alone is usually initiated as soon as the diagnosis is made. Oral prednisone is usually administered in high doses for approximately a month. However, different dosage schemes are proposed by different investigators. Vaglio et al. reported treatment of patients with idiopathic RPF with prednisone 1mg/Kg per day (max dose 80 mg/day) for four weeks. If improvement is achieved, the dose is then tapered over approximately 2 to 3 months to 10 mg/day and maintained for an additional 6 to 18 months in order to prevent relapse<sup>1</sup>. Prednisone has been proven to be more effective in prevention of relapses than tamoxifen and should be considered as first-line treatment for patients with newly diagnosed idiopathic RPF, despite a significantly higher rate of adverse effects<sup>34</sup>. Thus, tamoxifen is usually administered in patients who have contraindications to steroids<sup>35</sup>. Moreover, in patients with relative contraindications to long - term, high dose prednisone, therapeutic

regimens may include combination of lower total doses of glucocorticoids with other agents such as mycophenolate mofetil or colchicine<sup>36, 37</sup>. Within a few weeks of treatment manifestations of RPF usually subside. Pain, constitutional symptoms and urinary tract obstruction may be improved unless permanent renal damage has occurred. Acute - phase reactants (CRP and ESR) should fall rapidly. Resolution of the mass in CT scanning may begin<sup>22</sup>.

In cases where failure to detect clinical or radiological improvement within 4 to 6 weeks of initiation of medical therapy is observed, evaluation with CT scan and biopsy should be repeated in order to exclude a wrong diagnosis. If the diagnosis is confirmed, administration of prednisone is continued with the addition of an immunosuppressive agent such as azathioprine, cyclophosphamide, cyclosporine, mycophenolate mofetil or methotrexate<sup>38-40</sup>. Methotrexate induced nephrotoxicity, especially in patients with renal dysfunction should be taken seriously in account.

At present, there are no validated predictors of response to glucocorticoid therapy. Markers of inflammation proved to be poor predictors of a therapeutic response to corticosteroid therapy in patients with RPF. The mean CRP level and ESR tended to be higher in patients with radiographic regression but these differences failed to reach statistical significance<sup>40</sup>. However, recent studies have enhanced the use of FDG - PET in the follow-up of patients with RPF in order to tailor medical and surgical approaches as already mentioned. As PET is a rather expensive technique however, one of the goals of further analysis will be to define a favorable cost/benefit policy in this regard<sup>16</sup>.

Treatment continuation depends on the severity of the disease and the response to therapy. Recurrence rates are relatively high and usually depend on the kind of treatment and the duration of therapy<sup>40, 42</sup>.


Effective management of secondary RPF depends on removal of the underlying cause, when identified. This can lead to significant improvement within a few months. However, additional therapy with prednisone in such cases (mainly in drug - induced disease) may be beneficial<sup>1, 10</sup>. RPF is also, sometimes, associated with venous or arterial occlusion due to compression or an aortic aneurysm. In addition to

medical therapy for RPF these situations may require endovascular or surgical management (e.g. venous stent implantation)<sup>21</sup>.

If conservative strategies or endoscopic methods fail to diminish the compressive effects of RPF or malignancy has not been definitely ruled out, surgical intervention may be suggested. Surgical treatment main goals are obtaining biopsies of the fibrous plaque during the release of both ureters and their transposition inside the peritoneal cavity. This procedure is completed with a ureteral wrapping with omentum which can prevent a new entrapment and may promote revascularization of the ureters. Surgical approach can be achieved either by an open procedure or laparoscopically with or without robot assistance. Minimally invasive techniques have similar complication rates to the conventional method and are equally effective. Moreover, they can provide quicker convalescence and lower need for postoperative analgesia and blood transfusion<sup>43-47</sup>. However, surgical procedures may be associated with significant risks and complications including ureteric leakage, ureteral devascularization and strictures, urinary fistula formation, recurrent fibrosis and thromboembolism<sup>6</sup>.

Patients with benign RPF have generally a good prognosis. Although, severe complications may occur, total survival is not usually affected<sup>48</sup>. On the other hand, patients with malignant underlying causes have an ominous outcome. The prognosis is poor with a mean survival of 3 - 6 months<sup>22</sup>.

## Conclusion

RPF is an uncommon clinical entity for which an underlying cause is found in less than 30% of cases, with 8% of causes relating to malignancy. Treatment strategy should aim to close monitoring of the patients in order to prevent relapses of the disease and to customized therapeutic regimens. Before labeling a RPF as idiopathic any identifiable cause should be excluded, especially a malignant one. Progress has been made in the field of aetiopathogenesis of the disease, whereas no innovative ideas have been recently produced about diagnostics and therapy of RPF, apart from the development and application of novel, minimally invasive surgical techniques. 

## Περίληψη

Η οπισθοπεριτοναϊκή ίνωση είναι μια σπάνια ασθένεια που χαρακτηρίζεται από την παρουσία μιας εκτεταμένης, φλεγμονώδους, ινώδους μάζας στο οπίσθιο περιτόναιο, που συνήθως περιβάλλει την αορτή, την κάτω κοίλη φλέβα και τα λαγόνια αγγεία.

Στις περισσότερες περιπτώσεις παρατηρείται συνήθως και απόφραξη των ουρητήρων. Πρόσφατα, αναφέρθηκε πως η οπισθοπεριτοναϊκή ίνωση ανήκει στις ασθένειες σχετιζόμενες με IgG4, που απο-

τελούν μια νέα κλινική οντότητα. Οι απεικονιστικές μέθοδοι παίζουν πρωταρχικό ρόλο στη διάγνωση της οπισθοπεριτοναϊκής ίνωσης, με την αξονική τομογραφία να αποτελεί την εξέταση εκλογής.

Τα γλυκοκορτικοειδή αποτελούν την κυριότερη θεραπεία και χρησιμοποιούνται είτε ως μονοθεραπεία είτε σε συνδυασμό με άλλους παράγοντες. Εάν οι συντηρητικές μέθοδοι αποτύχουν, συνήθως απαιτείται χειρουργική παρέμβαση. Πρόσφατα, ελάχιστα επεμβατικές μέθοδοι έχουν εφαρμοσθεί.

**Λέξεις  
ευρητηριασμού**  
Οπισθοπεριτοναϊκή  
ίνωση, νόσος Ormond,  
IgG4, γλυκοκορτικοειδή

## References

- Vaglio A, Salvarani C, Buzio C. Retroperitoneal fibrosis. *Lancet*. 2006; 367: 241 - 251.
- Albarran J. Retention rénale par periurétérité. Libération externe de l'uretère. *Assoc Fr Urol*. 1905; 9: 511 - 517.
- Ormond JK. Bilateral ureteral obstruction due to envelopment and decompression by an inflammatory retroperitoneal process. *J Urol*. 1948; 59: 1072.
- Kottra JJ, Dunnick NR. Retroperitoneal fibrosis. *Radiol Clin North Am*. 1996; 34: 1259 - 1275.
- Van Bommel EF, Jansen I, Hendriksz TR, Aarnoudse AL. Idiopathic retroperitoneal fibrosis: prospective evaluation of incidence and clinoradiologic presentation. *Medicine (Baltimore)*. 2009; 88: 193 - 201.
- Cronin CG, Lohan DG, Blake MA, Roche C, McCarthy P, Murphy JM. Retroperitoneal fibrosis: a review of clinical features and imaging findings. *AJR*. 2008; 191: 423 - 431.
- Mehta A, Blodgett TM. Retroperitoneal fibrosis as a cause of positive FDG PET/CT. *J Radiol Case Rep*. 2011; 5: 35 - 41.
- Zielonko J, Obolonczyk L. Retroperitoneal fibrosis with pancreatic involvement—radiological appearance. *Pol J Radiol*. 2011; 76: 69 - 72.
- Ha YJ, Jung SJ, Lee KH, Lee SW, Lee SK, Park YB. Retroperitoneal fibrosis in 27 Korean patients: single center experience. *J Korean Med Sci*. 2011; 26: 985 - 990.
- Vaglio A, Palmisano A, Corradi D, Salvarani C, Buzio C. Retroperitoneal fibrosis: evolving concepts. *Rheum Dis Clin North Am*. 2007; 33: 803-817.
- Parums DV, Brown DL, Mitchinson MJ. Serum antibodies to oxidized low-density lipoprotein and ceroid in chronic periaortitis. *Arch Pathol Lab Med*. 1990; 114: 383.
- Vaglio A, Corradi D, Manenti L, Ferretti S, Garini G, Buzio C. Evidence of autoimmunity in chronic periaortitis: a prospective study. *Am J Med*. 2003; 114: 454 - 462.
- Rompa GT, Jablonska AK, Guzek MK, Dubowik MM, Marek IE, Smoczynski MK. Sclerosing cholangitis associated with retroperitoneal fibrosis: a case of multisystem fibroinflammatory disorder. *Hepatol Int*. 2010; 4: 779 - 783.
- Scheel PJ Jr, Feeley N. Retroperitoneal fibrosis: the clinical, laboratory, and radiographic presentation. *Medicine (Baltimore)*. 2009; 88: 202 - 207.
- Swartz RD. Idiopathic retroperitoneal fibrosis: a review of the pathogenesis and approaches to treatment. *Am J Kidney Dis*. 2009; 54: 546-553.
- Piccoli GB, Consiglio V, Arena V, Pelosi E, Anastasio D, Ragni F, et al. Positron emission tomography as a tool for the 'tailored' management of retroperitoneal fibrosis: a nephro - urological experience. *Nephrol Dial Transplant*. 2010; 25: 2603 - 2610.
- Umehara H, Okazaki K, Masaki Y, Kawano M, Yamamoto M, Saeki T, et al. A novel clinical entity, IgG4-related disease (IgG4RD): general concept and details. *Mod Rheumatol*. 2012; 22: 1 - 14.
- Kotani S, Wakamatsu R, Itoh A, Miyamoto K, Yoshino M, Takami K, et al. Proteinase 3 anti - neutrophil cytoplasmic antibody (PR3-ANCA) positive IgG4 - related retroperitoneal fibrosis: utility of PET - CT with 18F - fluorodeoxy glucose (FDG). *Intern Med*. 2012; 51: 755 - 758.
- Patel SM, Szostek JH. IgG4 - related systemic disease in a Native American man. *Intern Med*. 2011; 50: 931 - 4.
- Vivas I, Nicolás AI, Velázquez P, Elduayen B, Fernández - Villa T, Martínez-Cuesta A. Retroperitoneal fibrosis: typical and atypical manifestations. *Br J Radiol*. 2000; 73: 214 - 222.
- Okuyama H, Hirono O, Ishigaki D, Yuki K, Kubota I. Percutaneous transvenous stent implantation to external iliac vein stenosis in a patient with retroperitoneal fibrosis. *Intern Med*. 2010; 49: 913 - 918.
- Van Bommel EF. Retroperitoneal fibrosis. *Neth J Med*. 2002; 60: 231-242.
- Heckmann M, Uder M, Kuefner MA, Heinrich MC. Ormond's disease or secondary retroperitoneal fibrosis? An overview of retroperitoneal fibrosis. *Rof*. 2009; 181: 317 - 323.
- Do JG, Kim YB, Lee DG, Hwang JH. A case of delayed onset nephrogenic systemic fibrosis after gadolinium based contrast injection. *Ann Rehabil Med*. 2012; 36: 880 - 886.
- Chopra T, Kandukurti K, Shah S, Ahmed R, Panesar M. Understanding nephrogenic systemic fibrosis. *Int J Nephrol*. 2012; 2012: 912189.



26. Nishino M, Hayakawa K, Minami M, Yamamoto A, Ueda H, Takasu K. Primary retroperitoneal neoplasms: CT and MR imaging findings with anatomic and pathologic diagnostic clues. *Radiographics*. 2003; 23: 45 - 57.
27. Nakajo M, Jinnouchi T, Tanabe H., Tateno R. 18F - fluorodeoxyglucose positron emission tomography features of idiopathic retroperitoneal fibrosis. *J Comput Assist Tomogr*. 2007; 31: 539 - 543.
28. Vaglio A, Versari A, Fraternali A, Ferrozzi F, Salvarani C, Buzio C. (18)F - fluorodeoxyglucose positron emission tomography in the diagnosis and followup of idiopathic retroperitoneal fibrosis. *Arthritis Rheum*. 2005 15; 53: 122 - 125.
29. Young PM, Peterson JJ, Calamia KT. Hypermetabolic activity in patients with active retroperitoneal fibrosis on F - 18 FDG PET: report of three cases. *Ann Nucl Med*. 2008; 22: 87 - 92.
30. Moroni G, Castellani M, Balzani A, Dore R, Bonelli N, Longhi S, et al. The value of (18)F - FDG PET/CT in the assessment of active idiopathic retroperitoneal fibrosis. *Eur J Nucl Med Mol Imaging*. 2012; 39: 1635 - 1642.
31. Jansen I, Hendriksz TR, Han SH, Huiskes AW, van Bommel EF (18) F - fluorodeoxyglucose position emission tomography (FDG - PET) for monitoring disease activity and treatment response in idiopathic retroperitoneal fibrosis. *Eur J Intern Med*. 2010; 21: 216 - 221.
32. Jois RN, Gaffney K, Marshall T, Scott DG. Chronic periaortitis. *Rheumatology (Oxford)*. 2004; 43: 1441 - 1446.
33. Kermani TA, Crowson CS, Achenbach SJ, Luthra HS. Idiopathic retroperitoneal fibrosis: a retrospective review of clinical presentation, treatment, and outcomes. *Mayo Clin Proc*. 2011; 86: 297 - 303.
34. Vaglio A, Palmisano A, Alberici F, Maggiore U, Ferretti S, Cobelli R, et al. Prednisone versus tamoxifen in patients with idiopathic retroperitoneal fibrosis: an open-label randomised controlled trial. *Lancet*. 2011; 378: 338 - 346.
35. Van Bommel EF, Hendriksz TR, Huiskes AW, Zeegers AG. Brief communication: tamoxifen therapy for nonmalignant retroperitoneal fibrosis. *Ann Intern Med*. 2006; 144: 101 - 106.
36. Scheel PJ Jr, Feeley N, Sozio SM. Combined prednisone and mycophenolate mofetil treatment for retroperitoneal fibrosis: a case series. *Ann Intern Med*. 2011; 154: 31 - 36.
37. Vega J, Goecke H, Tapia H, Labarca E, Santamarina M, Martínez G. Treatment of idiopathic retroperitoneal fibrosis with colchicine and steroids: a case series. *Am J Kidney Dis*. 2009; 53: 628 - 637.
38. Marcolongo R, Tavolini IM, Laveder F, Busa M, Noventa F, Bassi P. Immunosuppressive therapy for idiopathic retroperitoneal fibrosis: a retrospective analysis of 26 cases. *Am J Med*. 2004; 116: 194 - 197.
39. Al-Harthy F, Esdaile J, Berean KW, Chalmers A. Multifocal idiopathic fibrosclerosis: treatment of 2 cases with cyclosporine. *J Rheumatol*. 2006; 33: 358 - 361.
40. Moroni G, Gallelli B, Banfi G, Sandri S, Messa P, Ponticelli C. Long-term outcome of idiopathic retroperitoneal fibrosis treated with surgical and/or medical approaches. *Nephrol Dial Transplant*. 2006; 21: 2485 - 2490.
41. Magrey MN, Husni ME, Kushner I, Calabrese LH. Do acute - phase reactants predict response to glucocorticoid therapy in retroperitoneal fibrosis? *Arthritis Rheum*. 2009; 61: 674 - 679.
42. Van Bommel EF, Siemes C, Hak LE, van der Veer SJ, Hendriksz TR. Long-term renal and patient outcome in idiopathic retroperitoneal fibrosis treated with prednisone. *Am J Kidney Dis*. 2007; 49: 615 - 625.
43. Seixas - Mikelus SA, Marshall SJ, Stephens DD, Blumenfeld A, Arnone ED, Guru KA. Robot-assisted laparoscopic ureterolysis: case report and literature review of the minimally invasive surgical approach. *JSLs*. 2010; 14: 313 - 319.
44. Keehn AY, Mufarrij PW, Stifelman MD. Robotic ureterolysis for relief of ureteral obstruction from retroperitoneal fibrosis. *Urology*. 2011; 77: 1370 - 1374.
45. Styn NR, Frauman S, Faerber GJ, Wolf JS Jr. University of Michigan surgical experience with ureterolysis for retroperitoneal fibrosis: a comparison of laparoscopic and open surgical approaches. *Urology*. 2011; 77: 339 - 343.
46. Stein RJ, Patel NS, Quinn K, Berger M, Koff W, Shah G, et al. Laparoscopic ureterolysis with omental wrap for idiopathic retroperitoneal fibrosis. *BJU Int*. 2010; 106: 703 - 707.
47. Srinivasan AK, Richstone L, Permpongkosol S, Kavoussi LR. Comparison of laparoscopic with open approach for ureterolysis in patients with retroperitoneal fibrosis. *J Urol*. 2008; 179: 1875 - 1878.
48. Brandt AS, Kamper L, Kukuk S, Haage P, Roth S. Associated findings and complications of retroperitoneal fibrosis in 204 patients: results of a urological registry. *J Urol*. 2011; 185: 526 - 531.



## ORIGINAL ARTICLE

# The clinical efficacy of short term minocycline administration in patients with chronic bacterial prostatitis from gram - positive microorganisms. A prospective, pilot study

K. Stamatiou<sup>1</sup>, G. Koritsiadis<sup>2</sup><sup>1</sup> Urology Department, Tzaneio Hospital, Piraeus, Greece<sup>2</sup> Urology Department, Metaxa Hospital, Piraeus, Greece

## Abstract

**Aim:** Today, the mainstay in the treatment of chronic bacterial prostatitis (CBP) is the use of oral antimicrobial agents and currently, the most effective medications are fluoroquinolones. Low healing rates have been associated to reinfection by gram - positive cocci. Minocycline is an inexpensive drug used for decades to treat acne. It has a long plasma half - life and it is effective in eradicating gram - positive cocci. Moreover it displays anti-inflammatory and immunomodulatory effects.

**Purpose:** To investigate the potential therapeutic benefit of minocycline in the treatment of patients of chronic prostatitis due to gram - positive bacteria.

**Methods:** Patients with proven chronic bacterial prostatitis due to gram - positive microorganisms who attended the outpatient department were randomized into two open groups (group 1:

minocycline, group: 2 ciprofloxacin). Patients of both groups were treated for 2 weeks and monitored for 16 weeks. The rate of microbial eradication and changes in the overall Chronic Prostatitis Symptom Index (NIH - CPSI) score from baseline to 16 weeks after the completion of treatment were evaluated in both groups.

**Results:** A total of 75 patients were participated in the study. At the end of the study period, a similar degree in changes in the overall result of the NIH - CPSI was found for both groups. The two treatment arms did not differ significantly with respect to the effectiveness of microbial eradication.

**Conclusions:** Minocycline shows comparable efficacy to ciprofloxacin in the treatment of chronic bacterial prostatitis from gram - positive microorganisms and it could be used as an alternative therapeutic agent to treat infection by gram positive cocci.

## Introduction

Chronic bacterial prostatitis is characterised by chronic pain of the pelvic region associated with intermittent urinary symptoms such as a sudden urge to urinate, frequent and urgent urination, and painful urination or nocturnal urination as well. Some men have low back pain, pain in the rectum,

or a feeling of heaviness behind the scrotum. Several patients present sexual dysfunction, others have pain after ejaculation, and, in a few cases, the semen may be tinged with blood<sup>1</sup>. The burden of symptoms varies from extremely bothering to understated. Treatment choice is of great interest because chronic bacterial prostatitis

### Key words

Minocycline chronic bacterial prostatitis from gram-positive microorganisms

## Corresponding author:

Dr. Konstantinos Stamatiou, Urology Department, Tzaneio Hospital, Afendouli 1 Ave 18536, Piraeus, Greece, E-mail: stamatiouk@gmail.com

can be very bothersome so that patients demand rapid relief. Actually, treatment requires the same antibiotics used for the acute form. The duration of treatment vary: recommendations of European Association of Urology are 4 - 6 weeks minimum with microbiological control fractionated one week after, four weeks after and it is recommended every three months to complete the year. However, prolonged treatment can increase costs, promote antimicrobial resistance, and increase the risk for *Clostridium difficile* infection, while even with the prolonged treatment, the infection often recurs<sup>2</sup>.

The mainstay in the treatment of chronic bacterial prostatitis is the use of oral antimicrobial agents and currently, the most effective medications are fluoroquinolones. Quinolone - based treatments have a bacterial eradication rate between 55% and 100%<sup>3</sup>. In most studies, the low healing rates have been associated to reinfection by gram - positive cocci. In addition bacterial resistance to the antibiotics seems to be the main cause of recurrence<sup>4</sup>. The last can usually be controlled with a course of another antibiotic. Moreover, an increasing prevalence of Gram - positive strains in prostatic secretion samples and an increasing resistance to quinolones was recently reported<sup>5</sup>.

For the reasons mentioned above, availability of a vast spectrum of antibiotic agents is of outmost importance for the definitive therapy. Tetracyclines and macrolides achieve high concentrations in the prostate and therefore they consists an alternative to the conventional antibiotic treatment. Additional properties render both tetracyclines and macrolides promising agents in the treatment of chronic bacterial prostatitis<sup>6</sup>. More precisely, minocycline shows antiinflammatory properties. Similar properties have been also described for several macrolides such as clarithromycin and erythromycin<sup>4</sup>. Clindamycin, an antibiotic of the lincosamide class, also exhibit several antiinflammatory properties and shows comparable concentrations in the prostate. Moreover, the azalide azithromycin (a subclass of macrolide antibiotic) displays an antiproliferative and autophagic effect on airway smooth muscle cells when is used in long-term treatment of airway diseases<sup>7</sup>. This effect is very likely to happen on prostate smooth muscle cells during prostatitis treatment.

Some of the above mentioned antibiotics have limited efficacy against gram - negative bacteria

which are the most common causes of UTI, other (erythromycin, tetracycline) have linked to increased bacterial resistance from gram+ bacteria such as *S. aureus*, *S. pyogenes* and other have properties that render problematic their usage in prostatitis treatment<sup>8</sup>.

Minocycline is a broad - spectrum tetracycline antibiotic. It is rapidly absorbed after oral administration and unlike most tetracyclines; its absorption is not significantly impaired by ingestion of food or milk. Its serum half - life is 18 hours. As a result of its bacteriostatic long - acting effect, it generally has serum levels two to four fold greater than that of the other tetracyclines. Seventy percent of the drug is protein bound and becomes active following gradual releasing so after 24hours serum level of Minocycline may be as high as 16 times than other tetracyclines<sup>9</sup>. Moreover, being the most lipid - soluble of the class, exhibits the greatest penetration into the prostate. It also has a broader spectrum than the other members of the group and is more potent against certain pathogens. In fact has excellent in vitro inhibitory activity against *coagulase-negative staphylococci*, particularly methicillin - resistant *S. aureus* and methicillin-resistant *S. epidermidis* strains<sup>10</sup>. The aim of the study is to investigate the therapeutic benefit of minocycline in the treatment of chronic prostatitis due to gram-positive bacteria.

### Material and methods

The material consisted of individuals with reported pelvic discomfort and genital pain with or without lower urinary tract symptoms and sexual dysfunction visiting our department from 04/2011 to 04/2014. Patients suffering from neurological disorders, those with anatomic abnormalities of the urinary tract and immunosuppressed patients were excluded from the study, as these are all conditions which can affect the clinical manifestation of the disease and could alter the outcome of the study. Patients underwent Stamey-Meares test (a few cases underwent the two glass test). Depending on history and specific symptoms urethral smear and sperm cultures were additionally obtained from several patients. Patients found with gram positive bacteria in prostatic secretion, urine sample, urethral smear and sperm cultures were randomly assigned one-to-one into two groups. Subjects

TABLE 1	<i>Characteristics of groups 1 and 2 with regard to age, prostatitis related history and baseline questionnaire scores</i>		
	Group A	Group B	P value
N	34	41	<0.05
Average age	45,57	41,96	<0.05
Average pain score	26,96	26,64	<0.05
N bacterial resistance	18	14	<0.05
N prior history of prostatitis	11	15	<0.05

in the first group were asked to fill the NHI - CPSI questionnaire and received minocycline (200 mg twice daily) for 15 days, while subjects in the second group were also asked to fill the NHI - CPSI questionnaire and received ciprofloxacin (500 mg twice daily) for 15 days. Patients of both groups were also asked to report possible side effects during antimicrobial treatment upon follow up visits.

The final choice of antibiotic for both groups was influenced by the antibiotic sensitivity testing and therefore those who were found with bacterial resistance to the default antimicrobial agent switched group.

Microbial response was assessed by the Stamey-Meares test and the response to symptoms by the NHI - CPSI and DRE findings at 8 and 16 weeks from the beginning of the study.

Statistical analysis: Analysis was performed using the SPSS 12 program and Fisher's exact test of significance was used. The accepted statistical significance cut - off value was 0.05 (P value < 0.05).

## Results

Ninety - three (93) patients enrolled from 04/2011 to 04/2014 were equally distributed to two groups (47+46). Twenty nine were found with more than one type of bacteria from each isolate. In twelve of them Gram negative bacteria were found among the responsible microorganisms and so they were excluded from the study. Two additional patients were excluded from the study since the pathogen (*Enterococcus*) was resistant to both ciprofloxacin and minocycline (while was sensitive to linezolid,

ampicillin, teicoplanin and amoxicilin). Three patients of the group A switched group and two patients of each group discontinued the study. Finally, a total of 75 patients participated in the study (34 in the group A and 41 in the group B). The average age in the first group was 45.57 years and 41.96 in the second group.

No statistically significant difference was noted between groups 1 and 2 with regard to mean age and prior history of prostatitis upon introduction into the study. Assessment of the questionnaires revealed moderate to severe pain in several patients in both groups. No significant difference was noted between groups 1 and 2 with regard to individual questionnaire fields upon introduction into the study. *Enterococcus faecalis* and *coagulase-negative staphylococci* (CoNS) strains are the first and second frequent pathogens found, respectively. Pathogens showed a slight decreasing of susceptibility to both quinolones and tetracyclines, however; no statistically significant difference in bacterial resistance rate between groups was found (**Table 1**).

1st follow up visit: At the first follow-up 11/34 patients in the first group reported persistence of symptoms compared to 19/41 patients in the second group. Symptoms questionnaire analysis revealed statistically significant differences between the two groups with regard to overall symptoms regression. Four patients in group 1 and five patients in group 2 had positive cultures despite symptoms improvement. Bacterial eradication was achieved in 26 patients in the first and 33 patients in the second group. Two patients of the first group reported symptoms persistence despite bacterial eradication and one patient of this group had

TABLE 2		Outcome in the 1st and 2nd follow up visit		
1st follow up visit	Group A	Group B	P value	
Symptoms improvement	23 (67.6%)	22 (53.4%)	>0.05	
Bacterial eradication	26 (76.4%)	33 (80.4%)	<0.05	
2nd follow up visit	Group A	Group B		
Symptoms improvement	32 (96.9%)	36 (92.3%)	<0.05	
Bacterial eradication	33 (100%)	39 (100%)	<0.05	

an obvious false negative EPS culture. Comparison of bacteriological results after treatment revealed not statistically significant differences between the two groups with regard to outcome (**Table 2**).

2nd follow up visit: At the second follow-up 1/33 patients in the first group and 3/39 in the second group (3 patients did not attend) reported persistence of symptoms. Of note, two of these patients (one in each group) reported recurrence of the symptoms despite being asymptomatic at the first follow - up. Comparison of symptoms questionnaire analysis revealed not statistically significant differences between the two groups with regard to outcome. Since, none of the patients of each group had a positive culture, bacterial eradication was achieved in the 100% of the participants (**Table 2**).

## Discussion

The value of minocycline in the treatment of urinary tract infections has been established in a number of trials and was found to be most effective in *E. coli* and *Strep. faecalis* infections. Moreover it has been widely used in the past against intra cellular pathogens in many chronic prostatitis patients<sup>11</sup>. A comparative study of minocycline and doxycycline in chronic prostatitis treatment showed a statistical difference in efficacy with regard to overall clinical response between the two agents in favor of minocycline<sup>12</sup>. Similarly, a small single - blind, parallel-group designed study found greater clinical and bacteriologic cures in the minocycline-treated group than in the cephalexin - treated group after four weeks treatment<sup>13</sup>.

The use of Minocycline for the treatment of genito-

urinary infections was gradually diminished over the years and so is assumed to be more effective and less likely to cause bacterial resistance than before. As mentioned above, nowadays the most effective medications for the treatment of chronic bacterial prostatitis are fluoroquinolones. Interestingly, there are no studies comparing head to head the efficacy of minocycline against that of quinolones<sup>14</sup>. In our study, minocycline showed comparable efficacy to ciprofloxacin in the treatment of chronic bacterial prostatitis from gram - positive microorganisms. Rapid symptoms regression despite short term minocycline administration (15 days) could be attributed to the anti-inflammatory properties of minocycline. In fact it has been proved that minocycline inhibits apoptosis via attenuation of TNF - alpha, downregulating pro-inflammatory cytokine output. This effect is mediated by a direct action of minocycline on the activated T cells. It also decreases the production of substances causing inflammation, such as prostaglandins, metalloproteinases and leukotrienes while it increases production of interleukin - 10, a substance that reduces inflammation<sup>15</sup>.

The greater disadvantage of minocycline is the variety and frequency of adverse reactions associated with its usage. However, minocycline shares many side effects in common with quinolones such as gastrointestinal effects (nausea, vomiting, and diarrhea), as well as headache dizziness and unsteadiness. They may also affect quality of sleep and rarely cause sleep disorders. Similarly to quinolones, minocycline increases sensitivity to sunlight. In prolonged use, minocycline may cause mental



changes, including depersonalization or may result in autoimmune disorders however these side effects are rare and are most commonly seen in female patients. In our study adverse effects were not recorded however the patient compliance was similar in both groups a fact that suggests comparable tolerability. Convenience of dosage was similar for both minocycline and ciprofloxacin.


In contrast economy favours minocycline use since the cost of ciprofloxacin is twice as that of minocycline. Although neither decreasing of susceptibility to ciprofloxacin nor decreasing of activity of ciprofloxacin against Gram - positive organisms was detected in this study, minocycline could be proposed as an alternative therapeutic agent against gram positive bacteria induced chronic bacterial prostatitis.

## Conclusions

Short term administration of minocycline seems to exhibit comparable efficacy to ciprofloxacin in the

treatment of chronic bacterial prostatitis from gram-positive microorganisms. Clinical efficacy, economy and convenience of dosage render minocycline an ideal alternative therapeutic agent for the treatment of chronic bacterial prostatitis by gram positive bacteria.

## Restrictions

The main bias of this study is related to randomization scheme, which was not clearly 'blind' since it was driven by antibiotic resistance. However, it is unclear whether and if the choice to switch antibiotic according to sensitivity could affect conclusive findings. It is also unclear whether the fact that patients with resistance to either tetracyclines or fluoroquinolones were not excluded from randomization (similarly to patients with gram - negative bacteria) influenced the results. Unfortunately data on adverse effects provided by the patients were scarce however none of the patients of both groups discontinued the study because of the side effects. 

## Περίληψη

**Στόχος:** Σήμερα, ακρογωνιαίος λίθος της θεραπείας της χρόνιας βακτηριακής προστατίτιδας είναι τα από του στόματος αντιμικροβιακά και κατά βάση οι φθοροκινολόνες που είναι και τα πιο αποτελεσματικά. Τα χαμηλά ποσοστά επιτυχίας στην θεραπεία της χρόνιας βακτηριακής προστατίτιδας έχουν συνδεθεί με υποτροπή ή επαναμόλυνση από gram-θετικά βακτήρια. Η μινοκυκλίνη είναι ένα φθηνό φάρμακο που χρησιμοποιείται εδώ και δεκαετίες για την θεραπεία της ακμής. Έχει παρατεταμένο χρόνο ημίσειας ζωής στο πλάσμα και είναι αποτελεσματική στην εξάλειψη των gram-θετικών κόκκων. Επιπλέον εμφανίζει αντι-φλεγμονώδεις και ανοσορυθμιστικές δράσεις. Σκοπός της μελέτης είναι η διερεύνηση του δυναμικού θεραπευτικού οφέλους από την χορήγηση μινοκυκλίνης σε ασθενείς με χρόνια προστατίτιδα από gram-θετικά βακτήρια. Υλικό και μέθοδος: Ασθενείς με αποδεδειγμένη χρόνια βακτηριακή προστατίτιδα που οφείλεται σε Gram θετικούς μικροοργανισμούς που διαγνώστηκαν στο νοσοκομείο μας και παρακολούθηθηκαν στα εξωτερικά ια-

τρία τυχαιοποιήθηκαν σε δύο ανοιχτές ομάδες (ομάδα 1: μινοκυκλίνη, ομάδα 2: σιπροφλοξασίνη). Οι ασθενείς των δύο ομάδων υποβλήθηκαν σε αγωγή για 2 εβδομάδες και παρακολούθηθηκαν για 16 εβδομάδες. Το ποσοστό της μικροβιακής εκρίζωσης καθώς και οι αλλαγές στη συνολική βαθμολογία του δείκτη συμπτωμάτων της χρόνιας προστατίτιδας (NIH-CPSI) από την έναρξη έως και 16 εβδομάδες μετά την ολοκλήρωση της θεραπείας αξιολογήθηκαν και στις δύο ομάδες. Αποτελέσματα: Ένα σύνολο από 75 ασθενείς συμμετείχαν στη μελέτη. Τόσο στην αρχή όσο και στο τέλος της μελέτης οι βαθμολογίες στο συνολικό αποτέλεσμα του NIH - CPSI ήταν παρόμοιες ενώ τα δύο σκέλη θεραπείας δεν διέφεραν σημαντικά και στην αποτελεσματικότητα την μικροβιακής εκρίζωσης. **Συμπεράσματα:** Η μινοκυκλίνη παρουσιάζει συγκρίσιμη αποτελεσματικότητα με σιπροφλοξασίνη στη θεραπεία της χρόνιας βακτηριακής προστατίτιδας από gram-θετικούς μικροοργανισμούς και θα μπορούσε να χρησιμοποιηθεί ως εναλλακτική λύση στη θεραπεία αυτής της ομάδας ασθενών.

**Λέξεις  
ευρετηριασμού**  
Μινοκυκλίνη,  
χρόνια βακτηριακή  
προστατίτιδα,  
gram-θετικά βακτήρια

## References

1. Stamatou K, Karageorgopoulos DE. A prospective observational study of chronic prostatitis with emphasis on epidemiological and microbiological features. *Urologia* 2013;3(80):225 - 232.
2. McNaughton Collins M, Pontari MA, O'Leary MP, Santanna J, Landis JR, et al. Quality of life is impaired in men with chronic prostatitis; the Chronic Prostatitis Collaborative Research Network. *J Gen Intern Med* 2001;16(10):656 - 662.
3. Bundrick W, Heron SP, Ray P, Schiff WM, Tennenberg AM, Wiesinger BA, et al. Levofloxacin versus ciprofloxacin in the Treatment of Chronic Bacterial Prostatitis: A Randomised Double-blind Multicenter Study. *Urology* 2003;62(3):537 - 541.
4. Cai T, Mazzoli S, Meacci F, Boddi V, Mondaini N, Malossini G, et al. Epidemiological features and resistance pattern in uropathogens isolated from chronic bacterial prostatitis. *J Microbiol.* 2011;49(3):448 - 54.
5. Wan CD, Zhou JB, Song YP, Zou XJ, Ma YQ. Pathogens of prostatitis and their drug resistance: an epidemiological survey. *Zhonghua Nan Ke Xue.* 2013;19(10):912 - 7.
6. Perletti G, Skerk V, Magri V, Markotic A, Mazzoli S, Parnham MJ, et al. Macrolides for the treatment of chronic bacterial prostatitis: an effective application of their unique pharmacokinetic and pharmacodynamic profile (Review). *Mol Med Rep.* 2011;4(6):1035 - 44.
7. Stamatou R, Paraskeva E, Boukas K, Gourgoulialis KI, Molyvdas PA, Hatziefthimiou AA. Azithromycin has an antiproliferative and autophagic effect on airway smooth muscle cells. *Eur Respir J.* 2009;34(3):721 - 30.
8. Albrich WC, Monnet DL, Harbarth S. Antibiotic selection pressure and resistance in *Streptococcus pneumoniae* and *Streptococcus pyogenes*. *Emerging Infect. Dis.* 2004;10(3):514 - 7.
9. Macdonald H, Kelly RG, Allen ES, Noble JF, Kanegis LA. Pharmacokinetic studies on minocycline in man. *Clin. Pharmacol. Ther.* 1973;14:852.
10. O Qadri SM, Halim M, Ueno Y, Saldin H. Susceptibility of methicillin-resistant *Staphylococcus aureus* to minocycline and other antimicrobials. *Chemotherapy* 1994;40:26 - 29
11. Simmons PD, Thin RN. Minocycline in chronic abacterial prostatitis: a double-blind prospective trial. *BJU* 1985;57(1):43 - 5.
12. Brannan W. Treatment of chronic prostatitis. Comparison of Minocycline and Doxycycline. *Urology.* 1975;5(5):626 - 31.
13. Paulson DF, Zinner NR, Resnick MI, Childs SJ, Love T, Madsen PO. Treatment of bacterial prostatitis. Comparison of cephalexin and minocycline. *Urology.* 1986;27(4):379 - 87.
14. Perletti G, Marras E, Wagenlehner FM, Magri V. Antimicrobial therapy for chronic bacterial prostatitis. *Cochrane Database Syst Rev.* 2013;8:CD009071.
15. Yrjanheikki J, Tikka T, Keinänen R, Goldsteins G, Chan PH, Koistinaho J. A tetracycline derivative, minocycline, reduces inflammation and protects against focal cerebral ischemia with a wide therapeutic window. *Proc Natl Acad Sci U S A.* 1999 Nov 9;96(23):13496 - 500.

APPENDIX	<i>Characteristics of staphylococci (Staphylococcus Haemoliticus, Aureus, Hominis, CoNS) strains and antibiotic treatment</i>			
Sample	N colonies	Sensitivity	Resistance	AB
VB3/postPM	2000 cfu/ml	full sensitive	-	Cipro
VB3/postPM		Tetracycline, Tigeclyline, Vancomycin	multiresistant	Mino
VB3/postPM	8000 cfu/ml	full sensitive		Mino
EPS	1200 cfu/ml	multisensitive	Erythromycin	Cipro
VB3/postPM	8000 cfu/ml	Tetracycline	multiresistant	Mino
EPS	900 cfu/ml	multisensitive	Macrolides, Methicillin, Penicillin	Mino
EPS	100 cfu/ml	multisensitive	Methicillin, Penicillin, Macrolides, Tetracycline	Cipro
Sperm		Tetracycline	multiresistant	Mino
VB3/postPM	100000 cfu/ml	full sensitive	-	Mino
VB3/postPM	3000 cfu/ml	multisensitive	Ampicillin	Mino
VB3/postPM	1500 cfu/ml	full sensitive	-	Mino
VB3/postPM	1000 cfu/ml	full sensitive	-	Mino
VB3/postPM	15000 cfu/ml	full sensitive	-	Cipro
VB3/postPM	100000 cfu/ml	multisensitive	Tetracyclines	Cipro
VB3/postPM	1000 cfu/ml	Tetracycline, Linezolid, Rifampicin	multiresistant	Mino
VB3/postPM	30000 cfu/ml	Tetracycline, Linezolid, Rifampicin	multiresistant	Mino
VB3/postPM	80000 cfu/ml	multisensitive	Penicillin	Cipro
VB3/postPM	2000 cfu/ml	Cefoxitin, Clindamycin, Penicillin, Ciprofloxacin	multiresistant	Cipro
VB3/postPM	1000 cfu/ml	multisensitive	Erythromycin	Mino
VB3/postPM	1100 cfu/ml	full sensitive	-	Cipro
VB3/postPM	5000 cfu/ml	full sensitive	-	Cipro
VB3/postPM	1200 cfu/ml	multisensitive	Penicillin, Erythromycin	Mino
VB3/postPM	1000 cfu/ml	multisensitive	Methicillin, Penicillin, Gentamycin, Clindamycin, Erythromycin	Cipro
VB3/postPM	5000 cfu/ml	full sensitive	-	Cipro
VB3/postPM	1200 cfu/ml	multisensitive	Penicillin, Erythromycin	Mino
VB3/postPM	1000 cfu/ml	multisensitive	Penicillin, Erythromycin, Methicillin, Gentamycin, Tetracyclines	Cipro
VB3/postPM	2500 cfu/ml	full sensitive	-	Mino
VB3/postPM	2000 cfu/ml	multisensitive	Penicillin, TMP-SMX, Tetracycline, Erythromycin	Cipro
VB3/postPM	8000 cfu/ml	multisensitive	Ampicillin	Cipro
VB3/postPM	1000 cfu/ml	multisensitive	Levofloxacin	Mino
VB3/postPM	8000 cfu/ml	full sensitive	-	Cipro
VB3/postPM	1000 cfu/ml	full sensitive	-	Cipro
VB3/postPM	4000 cfu/ml	full sensitive	-	Mino

APPENDIX	<i>Characteristics of enterococcus strains and antibiotic treatment</i>			
Sample	N colonies	Sensitivity	Resistance	AB
VB3/postPM	700 cfu/ml	full sensitive	-	Cipro
VB3/postPM	1700 cfu/ml	full sensitive	-	Cipro
VB3/postPM	2000 cfu/ml	Ciprofloxacin	multiresistant	Cipro
EPS	400 cfu/ml	sens to Tetracyclines	Quinolones, Macrolides	Mino
VB3/postPM	100000 cfu/ml	full sensitive	-	Cipro
VB3/postPM	2000 cfu/ml	sens to Quinolones	multiresistant	Cipro
VB3/postPM	7000 cfu/ml	fully sensitive	-	Mino
VB3/postPM	300 cfu/ml	full sensitive	-	Mino
EPS	200cfu/ml	full sensitive		Mino
VB3/postPM	40000 cfu/ml	multisensitive	Erythromycin, Ciprofloxacin, Levofloxacin	Mino
VB3/postPM	10000 cfu/ml	multisensitive	Erythromycine, Gentamicine, Dalfopristin	Cipro
VB3/postPM	10000 cfu/ml	full sensitive	-	Mino
VB3/postPM	1200 cfu/ml	full sensitive	-	Cipro
VB3/postPM	1400 cfu/ml	multisensitive	Macrolides, TMP-SMX	Mino
VB3/postPM	6000 cfu/ml	multisensitive	Erythromycine, Tetracycline	Cipro
VB3/postPM	2000 cfu/ml	multiresistant	Vancomycin, Linezolid, Dalfopristin, Teicoplanin	Cipro
EPS	400 cfu/ml	vancomycin, levofloxacin	multiresistant	Mino
VB3/postPM	600 cfu/ml	multisensitive	Erythromycine, Tetracycline	Cipro
VB3/postPM	500 cfu/ml	multisensitive	Erythromycine, Gentamicine, Dalfopristin	Cipro
VB3/postPM	1000 cfu/ml	multisensitive	Quinupristin, Erythromycin, Tetracycline	Cipro
VB3/postPM	5000 cfu/ml	multisensitive	Dalfopristin, Tetracycline	Cipro
VB3/postPM	1000 cfu/ml	multisensitive	Levofloxacin	Mino
VB3/postPM	40000 cfu/ml	multisensitive	Erythromycin, Ciprofloxacin, Levofloxacin	Mino
VB3/postPM	2000 cfu/ml	multisensitive	Quinupristin, Erythromycin, Tetracycline	Cipro
VB3/postPM	20000 cfu/ml	full sensitive	-	Cipro
VB3/postPM	1000 cfu/ml	multisensitive	Ciprofloxacin	Mino

APPENDIX	<i>Characteristics of streptococcus (streptococcus agalactiae, mitis, parasanguinis) strains and antibiotic treatment</i>			
Sample	N colonies	Sensitivity	Resistance	AB
EPS	100 cfu/ml	full sensitive	-	Cipro
VB3/postPM	400 cfu/ml	full sensitive	-	Mino
VB3/postPM	2200 cfu/ml	full sensitive	-	Cipro
EPS	300 cfu/ml,	full sensitive	-	Cipro
VB3/postPM	1000 cfu/ml	full sensitive	-	Cipro
VB3/postPM	7000 cfu/ml	full sensitive	-	Mino
EPS	300 cfu/ml	full sensitive	-	Mino
VB3/postPM	1000 cfu/ml	full sensitive	-	Cipro
VB3/postPM	7000 cfu/ml	full sensitive	-	Cipro



APPENDIX	<i>Characteristics of cultures with more than one type of bacteria from each isolate and antibiotic treatment</i>	
	Enterococcus Faecalis 100 cfu/ml (multisensitive, res to tetracyclines), CoNSTaphylococcus 1500 cfu/ml (multisensitive, res to tetracyclines) CoNSTaphylococcus 2000cfu/ml (multisensitive, res to erythromycin)	Cipro
	CoNSTaphylococcus 1000 (multisensitive, res to ciprofloxacin, levofloxacin) CoNSTaphylococcus 3000cfu/ml (multisensitive, res to Erytromycin, TMP-SMX, Fusidic acid)	Mino
	Staphylococcus haemoliticus 5000 cfu/ml, Staphylococcus epidermidis 800 cfu/ml (multisensitive res to erythromycin, clindamycin)	Cipro
	Enterococcus Faecalis 2000 cfu/ml (multisensitive, res to ciprofloxacin) Streptococcus agalactiae 2500 cfu/ml (full sensitive),	Mino
	Enterococcus Faecalis 10000 cfu/ml (full sensitive), CoNS 4000 cfu/ml (multisensitive, res to tetracyclines)	Cipro
	CoNS 500 cfu/ml (tetracycline, TMP-SMX, Erythromycin) Enterococcus 600 cfu/ml (Res to tetracycline)	Cipro
	CoNS 1000 cfu/ml (multisensitive, res to TMP-SMX, ciprofloxacin, levofloxacin), Enterococcus 2000 cfu/ml (multisensitive, res to Ampicillin)	Mino

APPENDIX	<i>Cultures with more than one type of bacteria from each isolate containing Gram negative bacteria (excluded from the study)</i>	
Gram – Gram+	E Coli 80000 (multisensitive res to tetracyclines, TMP-SMX) Enterococcus 30000 cfu/ml (full sensitive)	
Gram – Gram+	Klebsiella 800 (full sensitive), Staphylococcus Haemolyticus 2000 cfu/ml	
Gram – Gram+	Citrobacter freundii (multisensitive, res to Cefoxitin, Piperillin), Enterococcus Faecalis 30000 cfu/ml (multisensitive, res to Dalfopristin, Tetracycline)	
Gram – Gram –	E Coli 10000 cfu/ml (multisensitive, res to ciprofloxacin, TMP-SMX), Staph CoN 5000 cfu/ml (multiresistant sens to clindamycin, linesolid)	
Gram – Gram+	E Coli 1500 cfu/ml (multisensitive, res to ampicillin) Enterococcus Faecalis 1500 cfu/ml (multisensitive, res to TMP-SMX)	
Gram – Gram + Gram +	E Coli 1000 cfu/ml (full sensitive), Enterococcus faecalis 500 cfu/ml (multisensitive), CoNS 200 cfu/ml (multisensitive, Res to tetracyclines)	
Gram – Gram+	Proteus 100000 cfu/ml (full sensitive) Enterococcus 100000 cfu/ml (multisensitive except Macrolides),	
Gram – Gram+	E Coli 5000 cfu/ml (multisensitive), Enterococcus 2000 cfu/ml (full sensitive)	
Gram – Gram+	E Coli 5000 cfu/ml (multisensitive), Enterococcus Faecalis 2000 cfu/ml (multisensitive, res to dalfopristin, tetracycline)	
Gram – Gram+	E Coli 1800 cfu/ml (res to Quinolones, TMP-SMX, Tetracyclines) CoNS 15000 cfu/ml (Res to Macrolides)	
Gram – Gram+	E Coli 15000 cfu/ml (multisensitive), Staphylococcus 1500 cfu/ml (multisensitive)	
Gram – Gram+ Gram+	Proteus 10000 cfu/ml (full sensitive) Enterococcus faecalis 1200 cfu/ml (multisensitive, res to TMP-SMX), Staphylococcus epidermidis 1100 cfu/ml (multisensitive, res to Fusidic acid)	

## ORIGINAL ARTICLE

# The tension - free vaginal tape for managing female stress urinary incontinence in 95 cases

Nikolaos Kostakopoulos, Panagiotis Tekerlekis, Vasileios Argyropoulos, Athanasios Kostakopoulos  
Urological Department of IASO - General Hospital, Athens

## Abstract

**Objective.** To evaluate the results 1 year after surgery in women who underwent a tension - free vaginal tape procedure for stress incontinence.

**Patients and methods.** The study comprised 95 women with genuine stress incontinence. The patients were evaluated subjectively and objectively by the uroflowmetry, iresidual urine measurements and pressure flow, 1 year after the surgery.

**Results.** At the 1 year follow up 86 women (90%) were subjectively and objectively cured and 9 (10%) improved. The flow class 1 or 2 to a more obstructive pattern, implying a

lower Qmax and increased flow time. One patient had clinical problems and used self - catheterization once daily 3 months after surgery. There were only a few minor complications during and after operation.

**Conclusion.** The procedure presents very good results without serious complications and important influence of voiding phase. More extensive reports on the use of this technique are needed and further long - term follow up is necessary to validate the durability of the procedure and allay fears about late voiding disfunction.

## Introduction

The tension - free vaginal tape procedure is a minimally invasive surgical method for treating female stress incontinence which gained widespread popularity<sup>1, 2, 3, 4</sup>. The surgical technique requires positioning of a vaginal tape underneath the mid - urethra with no tension to restore urethral support. The aim of the present study was to evaluate the cure and complication rate of the procedure.

## Patients and methods

Between March 2004 and March 2013, 95 women (mean age 49,5 years, range 28 - 72) with urodynamically confirmed genuine stress urinary

incontinence underwent the procedure of tension - free vaginal tapes in two centres ( Spark of AMS and TVT-TO). Most of the operations (65) were carried out under local anaesthesia using the technique described

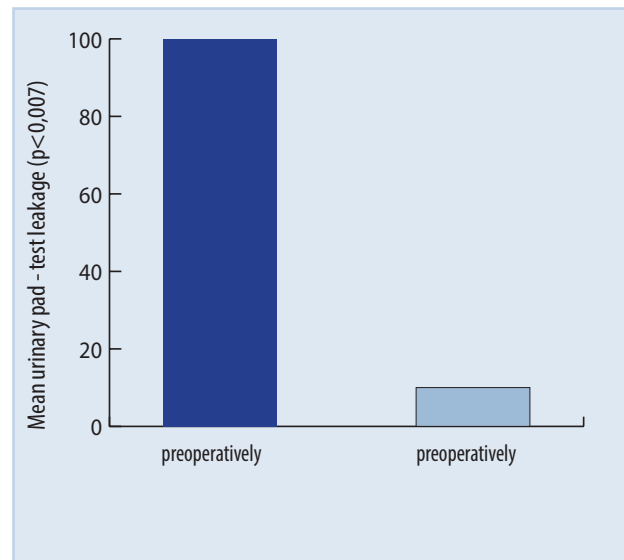
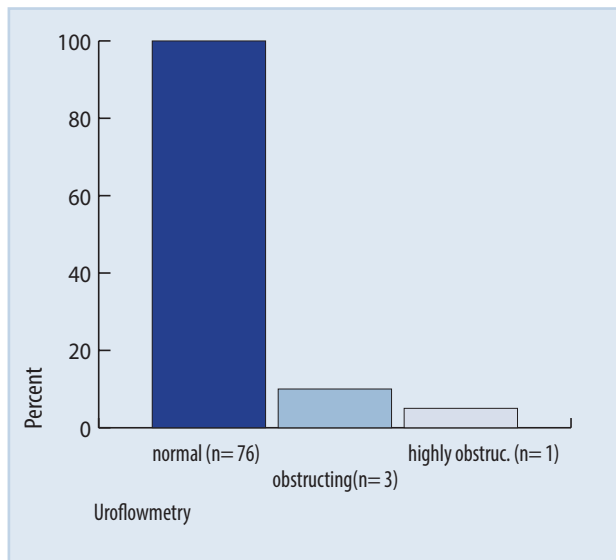
previously by ulmten etal<sup>1</sup>. 10 patients has an anterior colporraphy, 13 anterior and posterior colporraphy and two vaginal hysterectomy. In 30 last patients epidural anaesthesia was used. The evaluation before treatment included a detailed medical history, physical examination, pelvic examination, a 3 - day frequency/ volume chart, a 24h pad test, urine analysis, a postvoid residual urine volume (PVR) by ultrasonography, a Q tip test and finally a full urodynamic examination.

## Key words

Tension - free vaginal tape, stress incontinence, female

## Corresponding author:

A.Kostakopoulos. Department of Urology IASO General Hospital, 264 Mesogion Av. Athens Greece, E - mail: Kostako@otenet.gr



The diagnosis of genuine stress incontinence was based on the detection of urinary leakage during coughing in the absence of detrusor activity during the urodynamic test. Urodynamics were undertaken before surgery and 1 year after surgery. In the postoperative assessment the patients were asked if they considered themselves cured, improved, unchanged or worse than before the surgical procedure.

The voiding phase was assessed in four ways:

1. Subjectively, by asking if voiding had changed after surgery (dysuria, hesitancy, use of abdominal pressure, feeling of incomplete emptying).
2. By the uroflowmetry pattern.
3. A measurement of PVR (PVR > 25% of bladder capacity at cystometry considered significant).
4. PFS estimate of Qmax, detrusor pressure at Qmax (Pdet Qmax), maximum detrusor pressure (Pdetmax) and the urethral resistance factor (PdetQmax/Q2max).

Impaired bladder emptying was defined as the occurrence of abnormal voiding symptoms combined with the objective findings of obstruction or a hypoactive detrusor or a repeated PVR of >25% of the bladder capacity.

Urodynamic evidence was considered to indicate obstruction when the Qmax in repeated free - flow studies was  $\leq 12\text{ml/s}$ , combined with a PdetQmax of  $\geq 20\text{cmH}_2\text{O}$  during the PFS. A hypoactive detrusor was defined as a PdetQmax of  $< 20\text{cmH}_2\text{O}$  during the PFS, associated with a Qmax in free - flow studies of

$< 12\text{ml/s}$ . The objective cure rate was defined as a pad - test leakage of  $< 8\text{g}/24\text{h}$  and / or no leakage episodes on the frequency/ volume chart.

The results were compared using the wilcoxon signed - rank test with a level of significance of 0.05. The methods definitions and units conform to the standards recommended by the ICS.

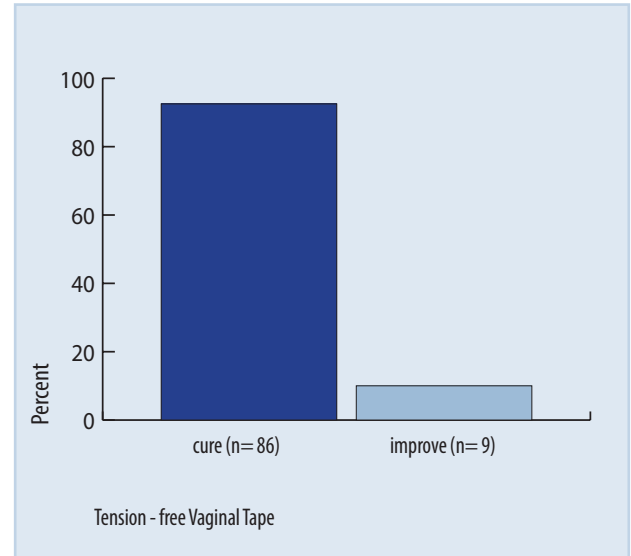
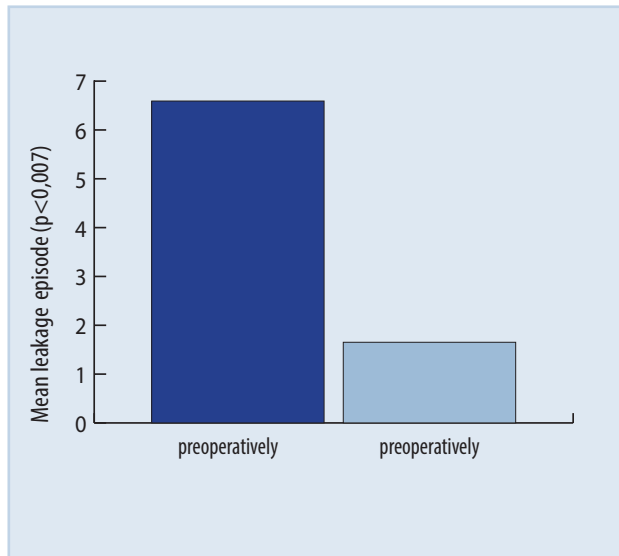
## Results

At the 1 - year follow - up 86 women (90%) were subjectively and objectively cured and (8 -10%) improved. The mean urinary pad-test leakage and mean number of leakage episodes from the frequency / volume chart decreased significantly from 95 to 5g/24h ( $p=0.001$ ) and 6.3 to 0.3 leakage episodes /24h ( $p<0.001$ ), respectively. There were only a few minor complications during and after operation.

Five patients had a bladder perforation and the needle was replaced. Three patients (3,15%) developed urinary retention. They underwent in replacement of catheter for 3 - 4 days. One of these women continued to have a significant PVR of 150 ml and used CISC once daily for 3 months.

Another one, developed persistent urinary retention. Finally she underwent new operation in which the vaginal tape released completely.

After surgery the uroflowmetry curve changed in 3 of the 80 women assessed (3,75%) from flow class 1 or 2 to a more obstructive pattern, implying a lower Qmax and increased flow time. The uroflowmetry



variables are shown in **diagram 1-4** . After surgery only one patient (the woman with a URF of 0,82) could be classified as having impaired bladder emptying according to the definition used. She reported that voiding had become more difficult and on PFS she had a Pdetmax of 35cmH2O and a Qmax of 5,9ml/s. Her PVR after surgery was 60ml (<25% of bladder capacity).

## Discussion

The present results show us that the procedure of the tension - free vaginal tape offers women with uncomplicated stress incontinence a minimally invasive alternative for surgical correction. The success rates are consequence of those in previous studies using the same technique<sup>1,5,6</sup>.

Also the present data indicate that this technique does not affects importantly the voiding phase, as other authors have reported<sup>5,7,8,9</sup>.

It detected no significant increase in PVR. An increase in PVR after the procedure but not greater of 100ml, has been reported in other studies. We used the technique of Spark and TVT - TO and the cure (90%) and complication rates are compatible with those reported previously with the original TVT technique.


Thus we consider that our findings are valid. Perioperative risks are low, hospitalization short and the return to work/ activity rapid.

Any operation for stress incontinence may introduce voiding difficulties and changes in voiding function<sup>5,7</sup>.

However, the clinical significance of introducing

voiding symptoms, urge incontinence, recurrent UTI and objective findings such as PVR, impaired flow rate /pattern and changes in pressure - flow variables, remain to be elucidated<sup>5</sup>. In our study we didn't found important postoperative changes in urodynamic parameters.

Although the procedure of tension - free vaginal tape has been introduced as "a tension - free" it is clear that the sling has tension applied by the surgeon. This tension may be inappropriate, such that it interferes with the normal bladder - neck mobility. Thus a sling properly placed mid - urethrally may be obstructive because the tension is too high, or the direction of traction inappropriate, or because of secondary fibrosis along the sling<sup>9,10</sup>.

The procedure has gained widespread popularity amongst both urologists and gynaecologists, although long - term results are not yet available. More extensive reports on the use of this technique are needed and further long term follow up is necessary to validate the durability of the procedure and allay fears about late voiding dysfunction. 

## Abbreviations

PVR, postvoid residual urine volume; PFS, pressure - flow study; Qmax, maximum urinary flow rate; Qave, mean urinary flow rate; PdetQmax, detrusor pressure at Qmax; Pdetmax, maximum detrusor pressure; URF, urethral resistance factor.



## Περίληψη

**Σκοπός:** Η αξιολόγηση των αποτελεσμάτων μετά έτος, ύστερα από χειρουργική επέμβαση τοποθέτησης ταινίας ελεύθερης τάσης, σε γυναίκες για αποκατάσταση ακράτειας προσπαθείας

**Υλικό και μέθοδος:** Η μελέτη περιλάμβανε 95 γυναίκες με γνήσια ακράτεια προσπαθείας. Αυτές, αξιολογήθηκαν έπειτα από 1 χρόνο από το χειρουργείο, με μετρήσεις ουροροομετρίας, υπολείμματος ούρων και μελέτες πίεσης ροής.

**Αποτελέσματα:** Κατά το ετήσιο follow - up, 86 γυναίκες (90%) θεραπεύτηκαν και 9 (10%) βελτιώθηκαν. Μόνο μία ασθενής εμφάνισε έντονο αποφρακτικό πρόβλημα και χρειάστηκε αυτοκαθετηριασμούς για 3 μήνες μετά την επέμβαση. Κατά τη διάρκεια της επέμβασης και άμεσα μετεγχειρητικά, μόνο λίγες και μικρής σοβαρότητας επιπλοκές παρουσιάστηκαν.

**Συμπεράσματα:** Η συγκεκριμένη χειρουργική διαδικασία, εμφανίζει ελάχιστες επιπλοκές και πολύ καλά αποτελέσματα σε ότι αφορά την εγκράτεια και τη διαδικασία της κένωσης της κύστης γενικότερα. Σίγουρα απαιτούνται έρευνες με μεγαλύτερο follow - up, ώστε να αξιολογηθεί ασφαλέστερα η διάρκεια των αποτελεσμάτων της συγκεκριμένης επέμβασης.

**Λέξεις  
ευρετηριασμού**  
Ταινία ελεύθερης  
τάσης, ακράτεια ούρων,  
γυναίκα

## References

- Moldovan CP, Marinone ME, Staack A. Transvaginal retropubic sling systems: efficacy and patient acceptability. *Int J Womens Health*. 2015 Feb 16;7:227 - 37.
- Petros P. Creating a gold standard surgical device: scientific discoveries leading to TVT and beyond : Ulf Ulmsten Memorial Lecture 2014. *Int Urogynecol J*. 2015 Apr;26(4):471 - 6.
- Min L, Zhao X. [Comparison of the efficacy and safety between TVT-0 and TVT-0 with biofeedback pelvic floor electrical stimulation on female stress urinary incontinence]. *Sichuan Da Xue Xue Bao Yi Xue Ban*. 2015 Jan;46(1):149 - 52. Chinese.
- Leanza V, Zanghi G, Vecchio R, Leanza G. How to prevent mesh erosion in transobturator Tension - Free Incontinence Cystocele Treatment (TICT): a comparative survey. *G Chir*. 2015 Jan-Feb;36(1):21 - 5.
- Kirby AC, Tan-Kim J, Nager CW. Dynamic maximum urethral closure pressures measured by high - resolution manometry increase markedly after sling surgery. *Int Urogynecol J*. 2015 Jan 31. [E - pub ahead of print]
- Wein AJ. Re: comparison of an adjustable anchored single - incision mini - sling, Ajust® with a standard mid-urethral sling, TVT-0™ : a health economic evaluation. *J Urol*. 2014 Jul;192(1):158.
- Forzini T, Viart L, Alezra E, Saint F. [Erosive complications of mid urethral slings (MUS): 10years of surgical experience]. *Prog Urol*. 2015 Apr;25(5):240 - 8.
- Tommaselli GA, D'Afiero A, Di Carlo C, Formisano C, Fabozzi A, Nappi C. Tension-free vaginal tape - obturator and tension-free vaginal tape-Secur for the treatment of stress urinary incontinence: a 5 - year follow-up randomized study. *Eur J Obstet Gynecol Reprod Biol*. 2015 Feb;185:151-5
- Solomon ER, Jelovsek JE. Removing a misplaced retropubic midurethral sling from the urethra and bladder neck using ear, nose, and throat instruments. *Obstet Gynecol*. 2015 Jan;125(1):58 - 61.
- Schweitzer KJ, Milani AL, van Eijnhoven HW, Gietelink DA, Hallensleben E, Cromheecke GJ, van der Vaart CH. Postoperative pain after adjustable single-incision or transobturator sling for incontinence: a randomized controlled trial. *Obstet Gynecol*. 2015 Jan;125(1):27 - 34.



Άμεση δράση στη φλεγμονή του προστάτη



# Libeprosta®

Λιπιδостερολικό εκχύλισμα *Serenoa repens*

## Μοναδικός τρόπος δράσης:

- Στη **φλεγμονή**<sup>1,2,3,4,5</sup>
- Στη **βελτίωση** συμπτωμάτων<sup>6,7</sup> και τον **έλεγχο** της εξέλιξης της ΚΥΠ<sup>8</sup>
- Στη **διασφάλιση** της ποιότητας ζωής<sup>8,9</sup> και το **σεβασμό** του ασθενούς

# Libeprosta®

**320 mg**  
την ημέρα

**Libeprosta®:**  
το εξανικό εκχύλισμα *Serenoa repens* με τις περισσότερες κλινικές και φαρμακολογικές μελέτες.<sup>10</sup>

**ΠΕΡΙΛΗΨΗ ΤΩΝ ΧΑΡΑΚΤΗΡΙΣΤΙΚΩΝ ΤΟΥ ΠΡΟΪΟΝΤΟΣ (S.P.C.):** 1. ΕΜΠΟΡΙΚΗ ΟΝΟΜΑΣΙΑ ΤΟΥ ΦΑΡΜΑΚΕΥΤΙΚΟΥ ΠΡΟΪΟΝΤΟΣ LIBEPROSTA 80 mg 2. ΠΟΙΟΤΙΚΗ & ΠΟΣΟΤΙΚΗ ΣΥΝΘΕΣΗ σε δραστικό συστατικό: Κάθε επικαλυμμένο δισκίο (434,9 mg) περιέχει: *Serenoa repens* lipidosterolic extract (1) 80 mg (1) Έλαιο προερχόμενο από τους καρπούς της *Serenoa repens* (διεργασία με εξάνο) 3. ΦΑΡΜΑΚΟΤΕΧΝΙΚΗ ΚΑΛΥΜΜΕΝΑ ΔΙΣΚΙΑ 4. ΚΛΙΝΙΚΑ ΣΤΟΙΧΕΙΑ 4.1. Θεραπευτικές ενδείξεις Για τη συμπτωματική αντιμετώπιση δυσουρικών εντολήσεων επί καλοήθους υπερπλασίας του προστάτη 4.2. Δοσολογία και τρόπος χορήγησης 4.3. Αντενδείξεις Δεν υπάρχουν 4.4. Ιδιαίτερες προειδοποιήσεις και ιδιαίτερες προφυλάξεις κατά τη χρήση Το φάρμακο δεν μπορεί να υποκαταστήσει την προστατεκτομή και κατά τη διάρκεια της λήψης του ο ασθενής πρέπει να βρίσκεται υπό συνεχή ιατρικό έλεγχο 4.5. Αλληλεπιδράσεις με άλλα φάρμακα ή άλλες μορφές αλληλεπίδρασης Δεν έχει παρατηρηθεί καμία αλληλεπίδραση με τις θεραπευτικές κλάσεις που συνήθως συγχρησιμοποιούνται για αυτή την πάθηση (αντιβιοτικά, ουρικά αντισηπτικά, αντιφλεγμονώδη). 4.6. Κύηση και γαλουχία Δεν εφαρμόζεται 4.7. Επίδραση στην ικανότητα οδήγησης και χειρισμού μηχανημάτων Δεν υπάρχει 4.8. Ανεπιθύμητες ενέργειες Η χρήση του φαρμάκου αρχικά μπορεί να προκαλέσει ναυτία. 4.9. Υπερδοσολογία Δεν έχουν ποτέ αναφερθεί περιστατικά. Μελέτες σε πειραματόζωα δεν έδειξαν ότι το ιδιοσυστάμα παρουσιάζει τοξικότητα. 5. ΦΑΡΜΑΚΟΛΟΓΙΚΕΣ ΙΔΙΟΤΗΤΕΣ 5.1. Φαρμακοδυναμικές ιδιότητες Δραστική ουσία του LIBEPROSTA είναι το λιπιδостερολικό εκχύλισμα του φυτού *Serenoa Repens* με αντι-ανδρογονικές ιδιότητες, αντιφλεγμονώδη και ανοιδοποιητική δράση. • Αναστέλλει τη μετατροπή της τεστοστερόνης σε διυδροτεστοστερόνη μέσω μη αναναστρέψιμης αναστολής της 5α-αναγωγάσης (τύπου 1 και 2) και προλαμβάνει από τους υποδοχείς DHT (διυδροτεστοστερόνη) του προστάτη εμποδίζοντας την εγκατάσταση της διυδροτεστοστερόνης στους υποδοχείς. • Μειώνει τη σύνθεση των προσταγλανδινών με την αναστολή της δράσεως της A2 φωσφολιπάσης (PLA2) και της απελευθέρωσης του αραχιδονικού οξέος. • Φαρμακολογικές μελέτες έχουν δείξει ότι το LIBEPROSTA έχει αντισφαιρωτικές ιδιότητες, μειώνοντας τη διαπερατότητα των αγγείων. Δρα μόνο στο επίπεδο οργάνου στόχου (προστάτη) χωρίς άλλες ορμονικές επιδράσεις ή παρεμβάσεις στον υποδομοκυτταρικό δόξα. 5.2. Φαρμακοκινητικές ιδιότητες Δεν είναι δυνατόν να πραγματοποιηθούν φαρμακοκινητικές μελέτες με τα φάρμακα αυτού του τύπου, επειδή δεν είναι δυνατόν να προσδιοριστούν τα επίπεδα όλων των συστατικών του φυτικού εκχυλίσματος στο αίμα και επιπλέον επειδή μερικά από τα συστατικά του υπάρχουν ήδη στο αίμα. 5.3. Προκλινικές μελέτες ασφαλείας Επανεξιλημένες μελέτες τοξικότητας σε 3 διαφορετικά είδη πειραματόζωων, έδειξαν χαμηλή τοξικότητα. Επιπλέον, δεν ήταν δυνατόν να πιστοποιηθεί ότι κάποια όργανα μπορεί να ήταν ιδιαίτερα ευαίσθητα στο φάρμακο. Αυτά τα τοξικολογικά αποτελέσματα στα ζώα σε δόσεις 40 έως 500 φορές υψηλότερες από την συνιστώμενη θεραπευτική δόση συμπίπτουν με την άριστη ασφάλεια που παρατηρήθηκε από τη στιγμή που το προϊόν χρησιμοποιείται από το 1982 στη Γαλλία. Οι πιο πρόσφατες μελέτες επαναληπτικές αποτελέσματα στα ζώα σε δόσεις 40 έως 500 φορές υψηλότερες από την συνιστώμενη θεραπευτική δόση συμπίπτουν με την άριστη ασφάλεια που παρατηρήθηκε από τη στιγμή που το προϊόν χρησιμοποιείται από το 1982 στη Γαλλία. 6. ΦΑΡΜΑΚΕΥΤΙΚΑ ΣΤΟΙΧΕΙΑ 6.1. Κατάλογος με έκδοχα EΚΔΟΧΑ Magnesium carbonate, silicon dioxide colloidal, kaolin, wheat starch, methylated casein, polyvidone excipient, magnesium stearate, purified water\* ΣΥΝΘΕΣΗ ΕΠΙΚΑΛΥΨΗΣ Hypromellose, hydroxypropylcellulose, polyethylene glycol 400, quinoline yellow lacquer E104, indigotine lacquer E132, titanium oxide, purified water \* Διαλύτης που εφαρμόζεται κατά τη διάρκεια της παρασκευής 6.2. Ασυμβατότητες Δεν αναφέρονται 6.3. Διάρκεια ζωής 36 μήνες για το έτοιμο προϊόν 6.4. Ιδιαίτερες προφυλάξεις κατά τη φύλαξη του προϊόντος Φυλάσσετε σε θερμοκρασία μικρότερη των 30° C. 6.5. Φύση και συστατικά του περιέκτη Κομτί που περιέχει 60 επικαλυμμένα δισκία σε 5 blister των 12 δισκίων 6.6. Οδηγίες χρήσης/χειρισμού Δεν αναφέρονται 6.7. Κάτοχος της άδειας κυκλοφορίας ΤΗΣ ΠΡΩΤΗΣ ΑΔΕΙΑΣ: 1-7-1986 ΑΝΑΝΕΩΣΗ ΤΗΣ ΑΔΕΙΑΣ ΚΥΚΛΟΦΟΡΙΑΣ: 6-2-2007 Χορηγείται με ιατρική συνταγή

**Pierre Fabre**  
FARMΑΚΑ S.A.  
Α. Μεσογείων 350, 15341, Αγία Παρασκευή  
Τηλ. 210 7234 582, Fax. 210 7234 589

Βοηθήστε να γίνουν τα φάρμακα πιο ασφαλή και Αναφέρετε ΟΛΕΣ τις ανεπιθύμητες ενέργειες για ΟΛΑ τα φάρμακα Συμπληρώνοντας την «ΚΙΤΡΙΝΗ ΚΑΡΤΑ»

Libe-203-2012