

VOLUME 26 | ISSUE 4

OCTOBER  
NOVEMBER  
DECEMBER


2014

Hellenic

# Urology

Quarterly Publication by the Hellenic Urological Association

ISSN 2241-9136



## REVIEWS

- Surgical Complete Androgen Blockade (SCAB) in the prostate cancer
- Distal ureterectomy techniques in LNU and RALNU

## ORIGINAL ARTICLES

- The role of transarterial embolization of RCC in elderly and unresected disease patients
- Pathophysiology and severity based proposed urodynamic classification of detrusor BnD
- Bci and booi versus wfmax and ura

## CASE REPORTS

- Successful restoration of deep open rupturing penile trauma
- Antegrade opening of the ureteral orifice via dilation balloon and placement of a ureteral double - J stent



**HELLENIC UROLOGY**

Official Journal of the Hellenic Urological Association

# Antegrade opening of the ureteral orifice via dilation balloon and placement of a ureteral double - J stent

Stamatiou K<sup>1</sup>, Moschouris I<sup>2</sup>.

1. Urology Department, Tzaneio General Hospital, Piraeus, Greece
2. Radiology Department, Tzaneio General Hospital, Piraeus, Greece

## Corresponding contributor:

Konstantinos N. Stamatiou, MD, PhD , Tzaneio Hospital, Afendouli 1 Avenue, 18536 Piraeus, Attica - Greece , E-mail: stamatiouk@gmail.com

## Abstract

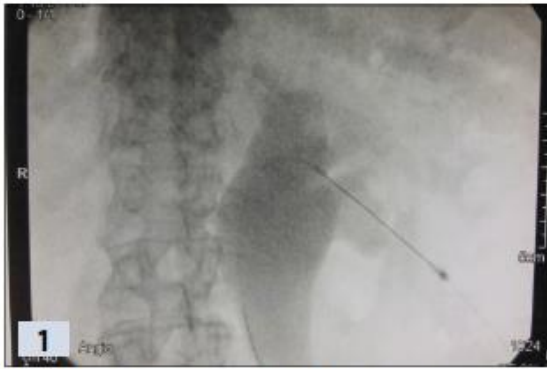Ureteral orifice destruction (complete or partial) during extensive transurethral resection of tumors of the urinary bladder is a relatively uncommon complication that may result in the dilation of the overlying part of the urinary tract. The present case report describes the orthodromic opening of the ureteral orifice via balloon dilation and placement of a ureteral double-J stent in a patient with complete ureteral orifice destruction, dilation of the overlying part of the urinary tract and hydronephrosis complicated by multiple lithiasis.

## Keywords:

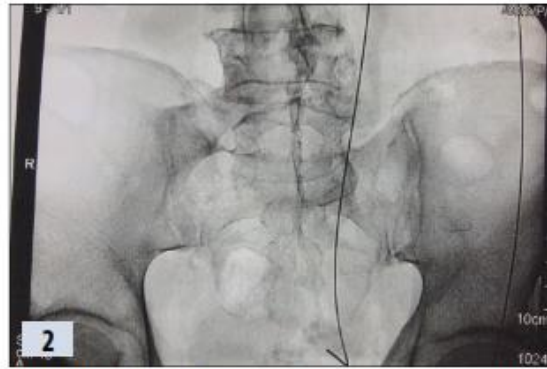
Ureteral orifice, ureteral stent, balloon dilation, lithiasis

## Introduction

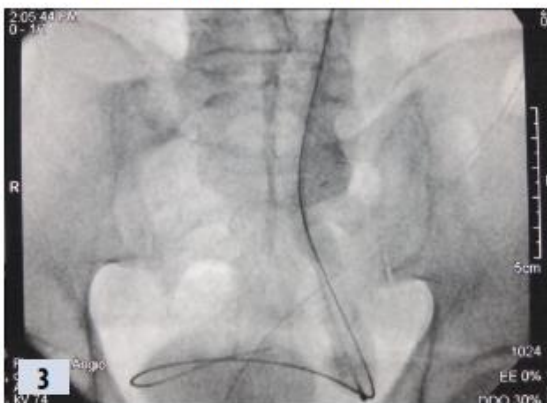
Transurethral Resection of Bladder Tumor (TUR-BT) is one of the most common urologic procedures. It consist the preferable and accepted treatment option for non-invasive tumors and it is also part of the diagnostic approach for all bladder tumors. It is considered as a safe surgical procedure, however complications may rarely occur<sup>1</sup>. One of them is the traumatic injury of the ureteral orifice. It is relatively rare and may occur during extensive TUR's of large tumors especially when is located proximal to the ureteral orifice. The injury may cause orifice stricture or failure of the antireflux mechanism. The first results in dilation of the overlying part of the urinary tract and hydronephrosis, while the latter may predispose to



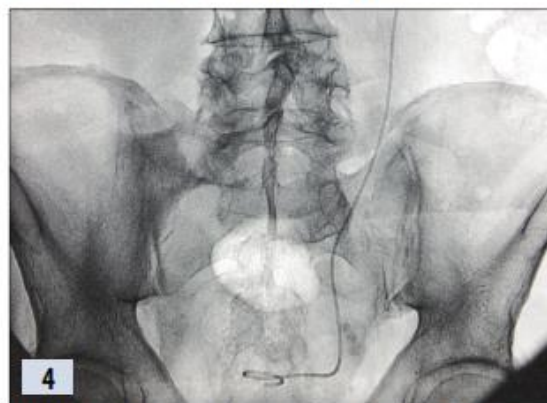**Figure 1.** Aspiration of a dilated calyx of the left kidney with a Chiba, 21G needle and subsequent infusion of diluted iodinated contrast material



**Figure 2.** Filling deficit in final portion of the left ureter suggesting the presence of stones. The bladder's lumen is not outlined



**Figure 3.** The point of entry in the bladder

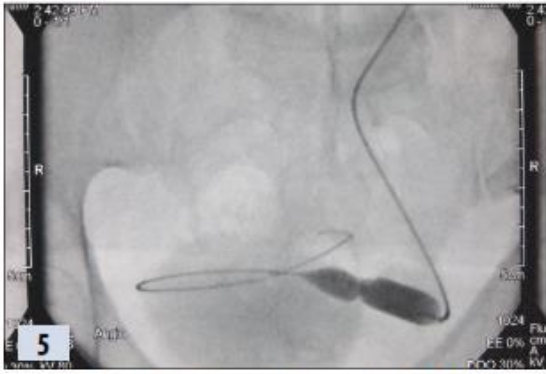


**Figure 4.** The double - J stent is deployed in the bladder. When its final position was confirmed the guide - wire and the pusher were withdraw

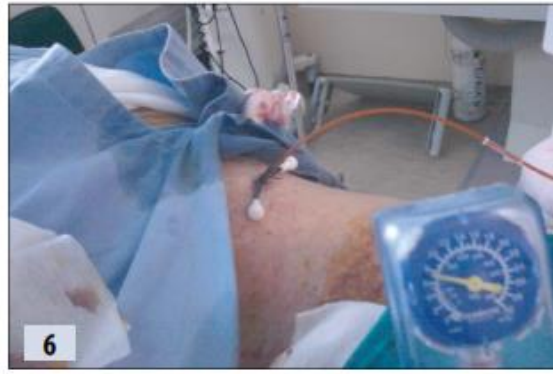urinary tract infections, dilation of the overlying part of the urinary tract or implantation of cancer cells in the upper urinary tract system. In such a case, in order to avoid potential implantation of cancer cells in the upper urinary tract system or outside the urinary tract, the repair is deemed necessary to be endoscopically performed<sup>2</sup>. The most common stricture management is scar tissue resection and it depends on the identification of the exact location site of ureteral orifice via several techniques. In certain cases, the access to the orifice is particularly difficult due to deformity or edema and therefore a blind opening at the orifice site is not indicated. The present case report describes the orthodromic opening of a destructed ureteral orifice via balloon dilation and ureteral double-J stent placement in a patient with complete orifice failure, dilation of the overlying part of the urinary tract and hydronephrosis complicated by multiple lithiasis.

### Case report

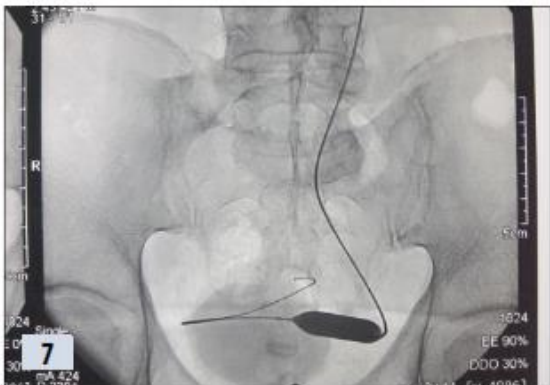A 62-year-old male patient, who, ten months prior to his visit, was subjected to TUR of a superficial tumor of the urinary bladder, was presented with macroscopic hematuria and back pain, occasionally recurring with paroxysms. The patient is under follow up and receives intravesicular instillations of epirubicin. In cystoscopy (3 months prior to the diagnosis of hematuria) neither tumor recurrence nor cancer development in situ were



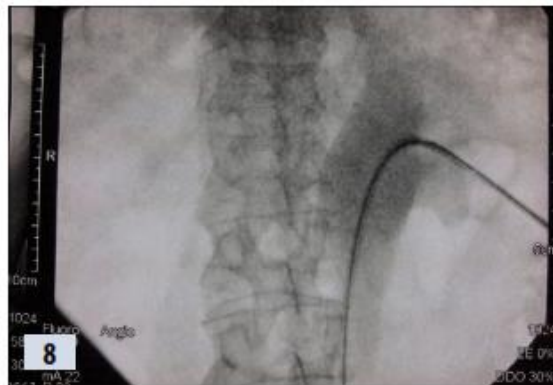**Figure 5.** The ureteral catheter with the incorporated compliant balloon is forwarded to the narrowed intravesical portion of the ureter



**Figure 6.** Progressive dilation of 1 - 2 min duration at 14 atm (max)



**Figure 7.** Progressive dilation of 1 - 2 min duration at 14 atm (max)



**Figure 8.** Placement of the double - J 8Fr ureteral stent

found however; the left orifice was undetectable. Apart from confirming hematuria, urinalysis and urine culture showed no infection or crystalluria. The ultrasound examination of the abdomen revealed dilation of both the pelvicalyceal system of the left kidney and the ipsilateral ureter. The CT-scan diagnosed multiple lithiasis in the lower part of the affected left ureter. Blood urea nitrogen and creatinine levels were within normal range. The patient consecutively underwent an unsuccessful endoscopic repair attempt and extracorporeal lithotripsy. Due to the progressive hydronephrosis and patient's unfavourable condition, a percutaneous nephrostomy placement for drainage purposes was decided.

For the drainage of the pelvicalyceal system via percutaneous access, a percutaneous drainage kit (Introducer Drainage Catheter Kit, Bioteque Corporation, Taiwan) was used. Under ultrasound guidance, a dilated left upper pole calyx was punctured via a 21g Chiba needle and the pelvicalyceal system was opacified with iodinated contrast agent (diluted with normal saline 50/50) (**Fig. 1**). Next, a 0.018" Mandril guidewire and a Cobra angiographic stent were introduced into the pelvicalyceal system and, properly maneuvered; were advanced to the distal part of the ureter in order to facilitate the demonstration of the dilation of the lower part of the ureter. A filling defect distanced 4 cm from the conceivable orifice location, suggested a calculi-induced obstruction and in fact, the bladder lumen was not opacified (**Fig. 2**).

A 0.018" Mandril guidewire assisted the catheterization of the pelvicalyceal system with coaxial implantation system and, for maneuverability reasons; it was replaced by a 0.035" Heavy Duty guidewire. The last was advanced into the bladder. The insertion site, the bladder's lumen outline as well as any potential leak, were inspected via contrast medium injection (**Fig. 3**). A 9-Fr peel-away sheath (Cook Medical Europe Ltd. Limerick, Ireland) was introduced into the pelvicalyceal system. Via the sheath and guided by the Heavy Duty wire, a 4.8-Fr double-J ureteral stent and its pusher (Standard Loop Stent, Bioteque Corporation, Taiwan) were placed into the ureter. When the double-J stent was well-advanced in the bladder and its final place in the pelvis was confirmed, the guidewire was retrieved followed by the pusher (**Fig. 4**). Through the sheath, an extra 8-Fr nephrostomy catheter was placed in order to ensure the kidney drainage in case of stent malfunction. A few days later, subsequent to the confirmation of the ureteral double-J stent's proper functioning, the nephrostomy catheter was removed.

Having confirmed the restoration of the pelvicalyceal system, an attempt to expand the ureteral orifice via balloon dilation was decided.

Similar to the above described technique, a 9-Fr peel-away sheath was introduced into the pelvicalyceal system, through which, a compatible semi-rigid foreign body retrieval forceps ("Alligator" foreign body retriever / Karl Storz) was inserted and removal of the ureteral double-J stent was followed. Assisted by the guidewire, an angiographic stent with a dilation balloon (compliant balloon 14 atm-4.3mm) was advanced to the strictured part of the ureter. A progressive dilation of 1-2 min duration was performed followed by instillation of normal saline solution under pressure and placement of an 8-Fr ureteral double-J stent (**Figs 5-8**). The imaging study confirmed the calculi expulsion.

### **Comment**

The use of catheters with incorporated dilation balloon (Fogarty type) does not actually represent a widely used practice in urology. In the majority of the cases, they have been used in managing congenital strictures of the ureteropelvic junction (UPJ). Relatively uncommonly, they have been used as an auxiliary medium for the removal of foreign bodies from the ureter or the prevention of calculi reflux during nephrolithotripsy<sup>3,4</sup>. Recently, they were used in the diagnosis of ureteral strictures during laparoscopic pyeloplasty<sup>5</sup>, as well as in the dilatation of a strictured anastomosis of ureter and neobladder<sup>6</sup>. The limited experience in the use of Fogarty type catheters for the treatment of ureteral strictures is mainly explained by the availability of most effective techniques that are not available in our hospital. Of note, the modern trend for the final management of such strictures is primarily the laser-assisted endoscopic incision. Long-term success rates of endoscopic incision range between 60 to 70 % and, in general terms, they rank higher than those managed with a balloon dilatator. In the present case, the patient background -that ruled out the open surgical management- and the lack of laser equipment in our hospital, rendered the above

described method as the only available treatment approach. Notably, it delivered satisfying results given that no recurrence was manifested during the 8-month follow up. Regarding the placement of a respectively large diameter ureteral double-J stent for the preservation of the treatment outcome, it should be mentioned that it consists an established practice in reconstructive procedures<sup>7</sup>. Usually, the introduction of ureteral stents for ureteral orifice dilatation maintenance is antegrade, (cystoscopically assisted through the vesicoureteral orifice) however, in our case, no such possibility was present given that our hospital is not equipped with a C-Arm.

In conclusion, percutaneous, placement of ureteral stents, as described above, is an alternative image-guided technique allowing for the successful placement of the ureteral double-J stent in order to avoid ureteral perforation. By using the refined interventional radiology material (coaxial insertion systems, peel-away sheaths etc), the maneuvers are safer and better tolerated ensuring thus the precise placement into the drainage system of the kidney. Of particular importance is the initial access site to the pelvicalyceal system which should be performed through the middle or upper calyces. Lower calyx access is not preferred since it is accompanied by increased angulation of the introducers, wires, and catheters, which consequently impede easy advancement inside the ureter<sup>8</sup>. Finally, balloon dilation next to the calculi (**Fig. 2, 5 & 7**) should be avoided, for it may induce a potential ureteral perforation.

## Περίληψη

Η καταστροφή του ουρητηρικού στομίου κατα την διάρκεια εκτεταμένης διουρηθρικής εκτομής όγκων της ουροδόχου κύστεως είναι μια σχετικά σπάνια επιπλοκή που μπορεί να οδηγήσει σε διάταση του υπερκείμενου τμήματος της αποχετευτικής οδού. Στην αναφορά αυτή περιγράφουμε μια περίπτωση ορθόδρομης διάνοιξης ουρητηρικού στομίου με χρήση μπαλονιού διαστολής και τοποθέτηση ουρητηρικού stent τύπου double-J σε ασθενή με πλήρη καταστροφή του στομίου, διάταση του υπερκείμενου τμήματος της αποχετευτικής οδού και υδρονέφρωση που επιπλέχθηκε με πολλαπλή λιθίαση.

## Λέξεις ευρητηριασμού

ουρητηρικό στόμιο, ουρητηρικός αθητήρας, μπαλόνι διαστολής, λιθίαση

## References

1. Collado A, Chechile GE, Salvador J, Vicente J. Early complications of endoscopic treatment for superficial bladder tumors. J Urol. 2000;164:1529-1532.

2. Mydlo JH, Weinstein R, Shah S, Soliday M, Macchia RJ. Long-term consequences from bladder perforation and/or violation in the presence of transitional cell carcinoma: Results of a small series and a review of the literature. *J Urol.* 1999;161:1128-1132.
3. Nieder AM, Meinbach DS, Kim SS, Soloway MS. Transurethral bladder tumor resection: intraoperative and postoperative complications in a residency setting. *J Urol.* 2009;174:2307-2309.
4. Sasaki A1, Kasaya S, Ishikawa S, Tsuruta A. Removal of migrated ureteral stent with a Fogarty catheter. *Hinyokika Kyo.* 1993;39(1):65-7
5. Gallego-Grijalva JE, Jaimes-Jimenez R, Alvarado-Garcva R, Terriquez-Rodrguez S. Hydropneumatic dilatation of the ureter. A technical option in ureteropyeloplasty. *Cir Cir.* 2003;71(4):296-9
6. Tsuji Y, Kinukawa T, Suzuki A, Ishida S, Fujita T, Komatsu T, Kimura T, Tanaka K, Hattori R. Identification of the narrow lumen of the ureter using a Fogarty catheter during laparoscopic pyeloplasty. *Int J Urol.* 2013;20(4):445-7.
7. Bar K, Szewczyk W, Szkodny G, Praisner A, Szkodny M. Fogarty's catheter in dilatation of ureteric stricture applied at anastomosis of ureter and neobladder. A case study. *Urologia Polska* 2001;4(1):11-5.
8. Ahallal Y, Khallouk A, El Fassi MJ, Farih MH. Risk factor analysis and management of ureteral double-j stent complications. *Rev Urol.* 2010;12(2-3):e147-51
9. Papanicoalou N. Uroradiological Intervention. In: Watkinson A, Adam A (eds) *Interventional Radiology. A practical guide.* Radcliff Medical Press Inc. New York 1996:108-112

## Bci and booi versus wfmax and ura.

Which combination of urodynamic parameters is more sensitive and specific in the urodynamic evaluation of detrusor contractility and benign prostatic obstruction, respectively?

Mytilekas Konstantinos Vaios<sup>(1)</sup>, Jesus Salinas Casado<sup>(2)</sup>

<sup>(1)</sup> Private urologist. Fellow at San Carlos Complutense University Hospital, Madrid, Spain

<sup>(2)</sup> Professor of Neurourology, Urology Department San Carlos Complutense University Hospital, Madrid, Spain.

Corresponding contributor:

Konstantinos Vaios Mytilekas, E - mail: vaiosmytilekas@gmail.com

### Abstract

#### Objectives:

The purpose of this retrospective study was to evaluate and compare the recommended BOOI and BCI with the urodynamic parameter URA and Watts graph, respectively. Is URA more sensitive and/or specific than BOOI in the diagnosis of BOO? Does the Watts factor graph give us more information on detrusor contractility than BCI?

**Methods:** Based on the hypothesis, that the specificity of two ideal urodynamic parameters which are used to independently calculate detrusor function and anatomic outlet resistance is increased when there is no correlation between them, we compared each other to the following urodynamic parameters: Bladder Outlet Obstruction Index(BOOI), Bladder Contractility Index (BCI), Urethral Resistance Factor (URA), Watts factor maximum (WFmax). Linear Passive Urethral Resistance Relation (LPURR), uroflow maximum flow (Qmax) and uroflow Post Void Residual (PVR) were also included in the analysis among 32 males with urodynamic diagnosis of benign prostatic obstruction (BPO) and recommendation for surgical treatment.

**Results:** Using the combination of urodynamic parameters  $P_{det}Q_{max} \geq 45$  cmH<sub>2</sub>O and  $Q_{max} < 12$  ml/sec as the gold standard of obstruction, the total sensitivity of  $BOOI \geq 40$  and  $URA \geq 29$  in the diagnosis of BPO was 87,5 % and 96,9%, respectively. Strong positive linear correlation, statistical significant was found between: URA-LPURR ( $P < 0.0001$ , Pearson  $r = 0.77$ ), BOOI-LPURR ( $P < 0.0001$ , Pearson  $r = 0.75$ ), BOOI-BCI ( $P < 0.0001$ , Pearson  $r = 0.85$ ).



Moderate negative linear correlation, statistical significant was found between: URA-Qmax ( $P < 0.0001$ , Pearson  $r = -0.60$ ). Moderate positive linear correlation, statistical significant was found between: URA-PVR ( $P < 0.0001$ , Pearson  $r = 0.63$ ). Weak positive linear correlation, not statistical significant was found between: WFmax-Qmax ( $P = 0.0214$ , Pearson  $r = 0.4053$ ), BOOI-PVR ( $P < 0.0336$ , Pearson  $r = 0.3766$ ). Weak negative linear correlation, not statistical significant was found between: WFmax-PVR ( $P < 0.03$ , Pearson  $r = -0.3754$ ). No correlation was found between: BCI-Qmax, BCI-PVR, BOOI-Qmax, WFmax-URA.

**Conclusions:** Based on our results, the strong positive linear correlation, statistically significant between BOOI and BCI, automatically reduces the specificity in both of them. On the contrary, we recommended the combination of URA and WFmax due to the absence of any correlation between them, an observation which theoretically increases the specificity in both of them in the differential diagnosis between obstruction and detrusor underactivity, respectively.

### Key words

Bladder Outlet, Obstruction Index, (BOOI), Bladder, Contractility Index (BCI)

### Περίληψη

**Σκοπός-Υπόθεση:** Η ειδικότητα δύο ουροδυναμικών παραμέτρων οι οποίες χρησιμοποιούνται για να αξιολογήσουν ανεξάρτητα την λειτουργία του εξωστήρα και τις παθητικές αντιστάσεις στην ροή των ούρων, αυξάνεται θεωρητικά όταν δεν υπάρχει συσχέτιση μεταξύ τους.

**Ασθενείς και Μέθοδος:** Αναδρομικά σε 32 ασθενείς με διάγνωση καλοήθους προστατικής απόφραξης (Benign Prostatic Obstruction, BPO) και σύσταση για χειρουργική αντιμετώπιση αυτής συσχετίστηκαν μεταξύ τους οι ουροδυναμικές παράμετροι της μελέτης πίεσης ροής BOOI (Bladder Outlet Obstruction Index)-LPURR (Linear Passive Urethral Resistance Relation), URA (Urethral Resistance Factor) -LPURR, BOOI-Qmax, BOOI-PVR, URA-Qmax, URA-PVR, BCI (Bladder Contractility Index) -Qmax, BCI-PVR, URA-Qmax, URA-PVR, BOOI-BCI και URA-WFmax (Watts Factor maximum). Η στατιστική ανάλυση έγινε με την χρήση του λογισμικού graphpadprism 5 logistics (Linear regression analysis και Pearson's correlation analysis.)

**Αποτελέσματα:** Ισχυρή θετική γραμμική συσχέτιση, στατιστικά σημαντική παρατηρήθηκε μεταξύ: URA-LPURR ( $P < 0.0001$ , Pearson  $r = 0.77$ ), BOOI-LPURR ( $P < 0.0001$ , Pearson  $r = 0.75$ ), BOOI-BCI ( $P < 0.0001$ , Pearson  $r = 0.85$ ). Μέτρια αρνητική γραμμική συσχέτιση, στατιστικά σημαντική βρέθηκε μεταξύ: URA-Qmax ( $P < 0.0001$ , Pearson  $r = -0.60$ ). Μέτρια θετική γραμμική συσχέτιση, στατιστικά σημαντική βρέθηκε μεταξύ: URA-PVR ( $P < 0.0001$ , Pearson  $r = 0.63$ ). Ασθενής θετική γραμμική συσχέτιση, μη στατιστικά σημαντική βρέθηκε μεταξύ: WFmax-Qmax ( $P = 0.0214$ , Pearson  $r = 0.4053$ ), BOOI-PVR ( $P < 0.0336$ , Pearson  $r = 0.3766$ ). Ασθενής αρνητική γραμμική συσχέτιση, μη στατιστικά σημαντική βρέθηκε μεταξύ: WFmax-

PVR ( $P < 0.03$ , Pearson  $r = -0.3754$ ). Απουσία συσχέτισης βρέθηκε μεταξύ :BCI-Qmax, BCI-PVR, BOOI-Qmax, WFmax-URA.

**Συμπέρασμα:** Στο μικρό αυτό δείγμα ασθενών, η παρουσία θετικής γραμμικής συσχέτισης μεταξύ των παραμέτρων BOOI και BCI ενώ η απουσία οποιασδήποτε συσχέτισης μεταξύ των παραμέτρων URA και WFmax φαίνεται να ενισχύει την άποψη ότι ο συνδυασμός των URA και WFmax είναι πιο ειδικός από τον συνδυασμό των BOOI και BCI στην διαφορική διάγνωση υποσυστολίας και απόφραξης κατά την διάρκεια της μελέτης πίεσης ροής.

## Λέξεις ευρητηριασμού :

Δείκτες υποκυστικής απόφραξης και υποσυστολίας

## INTRODUCTION

The most reliable method for investigating reduced urinary output in men with Lower Urinary Tract Symptoms (LUTS) is the Pressure-Flow study (P-F study). Internationally, it is considered as the gold standard in the differential diagnosis between Bladder Outlet Obstruction (BOO) and Detrusor Underactivity (DU)<sup>1</sup>. According to the International Continence Society (ICS), the urodynamic evaluation of BOO is supported by the Bladder Outlet Obstruction Index (BOOI =  $P_{det}Q_{max} - 2 Q_{max}$ ) while, at the same time, the detrusor contractility should be assessed by the Bladder Contractility Index (BCI =  $P_{det}Q_{max} + 5Q_{max}$ ). BOOI  $\geq 40$  is considered as BPO and BCI  $\geq 100$  as normal detrusor contractility<sup>2</sup>. The Urethral Resistance Factor (URA) with a value  $\geq 29$  is also regarded as obstruction suggestive<sup>3</sup>. The maximum Watts factor, WF max value  $\geq 10.85$ , is considered as normal detrusor isometric contraction whereas the factor's negative value W80-W20 as fading contraction<sup>4</sup>. The purpose of the present retrospective study was the comparative evaluation of all the aforementioned urodynamic indices and factors only in a sub-category of patients presenting anatomic prostatic obstruction, in men with confirmed BPO-induced prostate and clinical indications of surgical management, in accordance with the American Urological Association (AUA) and the Society of Urodynamics, Female Pelvic Medicine & Urogenital Reconstruction (SUFU). The latter advises the P-F study solely prior to the surgical management of LUTS in male patients with Grade B evidence strength (AUA/SUFU Guidelines Statement 17, Grade B)<sup>5</sup>.

## MATERIALS & METHODS

Retrospectively, the collection of the material necessary for the conduction of the study was elaborated in the functional urology office archives at the Urology Department, San Carlos Complutense University Hospital, Madrid, Spain. The search of patients was based on two criteria: the urodynamic diagnosis of BPO and the medical advice for surgical management; the urodynamic evaluation of the patients dated from 12/2009 to 4/2010. The aim of the

study was the comparison of urodynamic indices of an as much as possible homogenous sub-category of patients with BOO, namely that of BPO. Patients with other anatomic obstructions like urethral stricture or patients with functional urinary obstruction due to failure of the pelvic floor muscle to relax were not included in the study. Out of 43 archived patients who met the above criteria, 5 patients were excluded due to lack of urine output (micturition) during the P-F study and 6 more were excluded because of insufficient recorded values, [URA, BOOI, BCI, WFmax, W80-W20, Linear Passive Urethral Resistance Relation (LPURR grade), maximum urine outflow on uroflowmetry (free Qmax), post-void residual on uroflowmetry (free PVR)], required for the study of the urodynamic factors in the urodynamic investigation (**Fig. 4**). The remaining 32 male subjects were synchronously subjected to voiding cystourethrography (VCUG); benign prostatic hyperplasia (BPH) was determined as the cause of urinary obstruction (prostatic urethra lumen lengthening and narrowing). The urodynamic study was conducted via a 6Ch pressure recording intravesical catheter and an 8Ch pressure recording intrarectal catheter. The bladder filling rate with normal saline in room temperature was moderate (50ml/min). All patients, following a second filling cystometry (FCM) and retrieval of the pressure recording intravesical catheter, were then subjected to free uroflowmetry. The activity of the pelvic floor was recorded during FMC as well as during the P-F study and also in free uroflowmetry with surface electromyography (SEMG) of the pelvic floor. The statistical analysis was performed on GraphPad Prism 5 logistics software (Linear regression analysis and Pearson's correlation analysis).

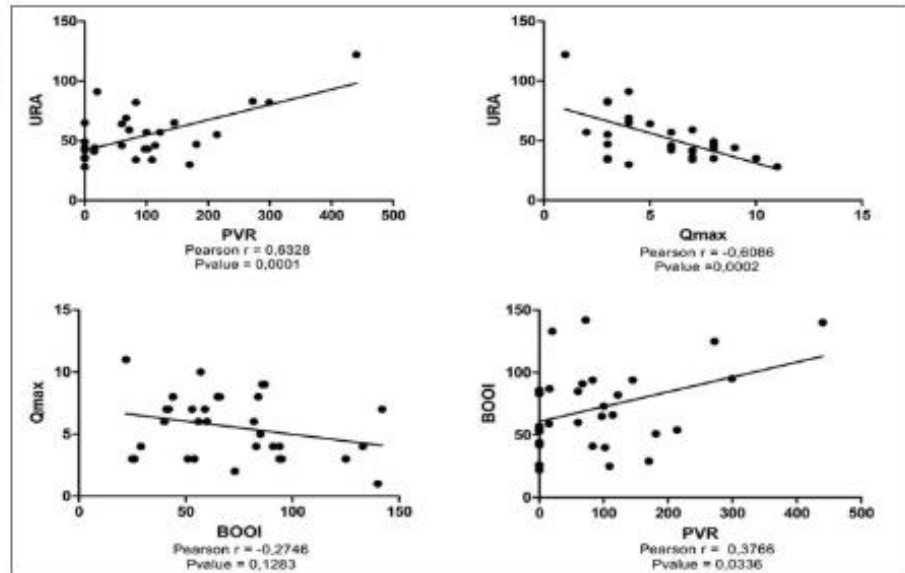
## RESULTS

All patients exhibited obstruction according to the urodynamic criteria of Jensen KME et al. [Maximum detrusor pressure ( $P_{detmax} > 45 \text{ cmH}_2\text{O}$ ) and maximum urinary output rate ( $Q_{max} < 12 \text{ ml/sec}$ )]<sup>6</sup>. Strong positive linear correlation, statistically significant was reported between: URA-LPURR ( $P < 0.0001$ , Pearson  $r = 0.77$ ), BOOI-LPURR ( $P < 0.0001$ , Pearson  $r = 0.75$ ) and BOOI-BCI ( $P < 0.0001$ , Pearson  $r = 0.85$ ). Moderate negative linear correlation, statistically significant was found between: URA- $Q_{max}$  ( $P < 0.0001$ , Pearson  $r = -0.60$ ). Moderate positive linear correlation, was statistically significant between: URA-PVR ( $P < 0.0001$ , Pearson  $r = 0.63$ ). Weak positive linear correlation, not statistically significant was reported between: WFmax- $Q_{max}$  ( $P = 0.0214$ , Pearson  $r = 0.4053$ ), BOOI-PVR ( $P < 0.0336$ , Pearson  $r = 0.3766$ ). Weak negative linear correlation, not statistically significant was found between: WFmax-PVR ( $P < 0.03$ , Pearson  $r = -0.3754$ ). Absence of correlation was found between: BCI- $Q_{max}$  ( $P = 0.1435$ , Pearson  $r = 0.2645$ ), BCI-PVR ( $P = 0.8334$ , Pearson  $r = 0.038$ ), BOOI- $Q_{max}$  ( $P = 0.1283$ , Pearson  $r = -0.2746$ ) and WFmax-URA ( $P = 0.5336$ , Pearson  $r = 0.1142$ ). (**Fig. 1, 2 and 3**).

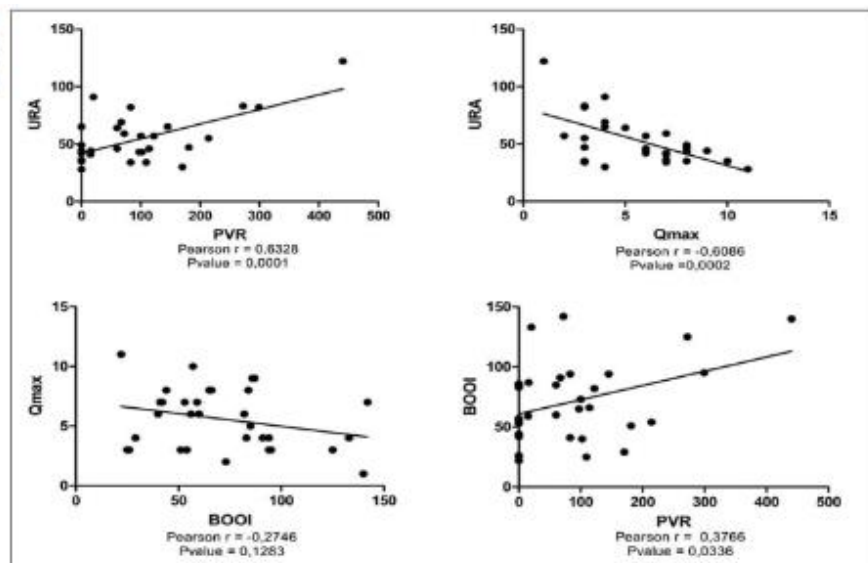
The urodynamic diagnosis of DU, based on the proposed published urodynamic evaluation parameters, is depicted in **Table 1**. If only isometric contraction is regarded as confirmed DU ( $WF_{max} < 10.85$ ), then only 18.75% ( $v = 6/32$ ) of our cohort would have manifested

synchronous BOO and DU in contrast with the 37.5% ( $v=12/32$ ) calculated according to the index  $BCI < 100$ . Despite the absence of a statistically significant difference (fishers exact test, two tailed,  $p=0.16$ ), possibly due to the extremely low sample of patients, we observe a difference in the rates based on these two definitions of urodynamic hypocontractility. It is

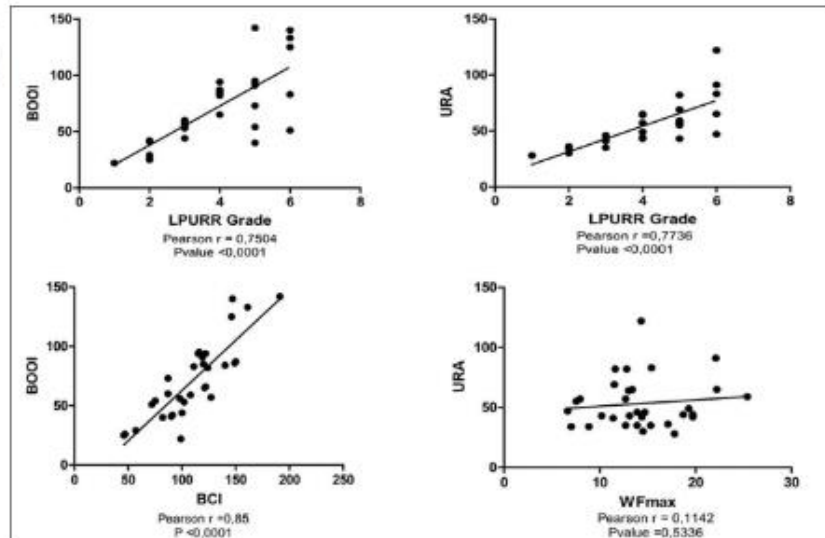
**Figure 1:** Correlation between Wfmax-Qmax, Wfmax-PVR, BCI-Qmax and BCI-PVR



**Figure 2:** Correlation between URA-Qmax, URA-PVR, BOOI-Qmax and BOOI-PVR



**Figure 3:** Correlation between BOOI - LPURR, URA - LPURR, BOOI - BCI and URA - WFmax



Theoretic urodynamic diagnosis of hypocontractility	
Theoretic urodynamic criteria of detrusor contractility	Theoretic hypocontractility rate(%)
Bladder Contractility Index ( $BCI = PdetQ_{max} + 5Q_{max}$ ) < 100	37.5% (v=12/32)
$Wf_{max} < 10.85 + W80 - W20 \geq 0$ (Isolated isometric contraction)	6.25% (v=2/32)
$Wf_{max} \geq 10.85 + W80 - W20 < 0$ (Isolated fading contraction)	53.13% (v=17/32)
$Wf_{max} < 10.85 + W80 - W20 < 0$ (Combined isometric & fading contraction)	12.5% (v=4/32)

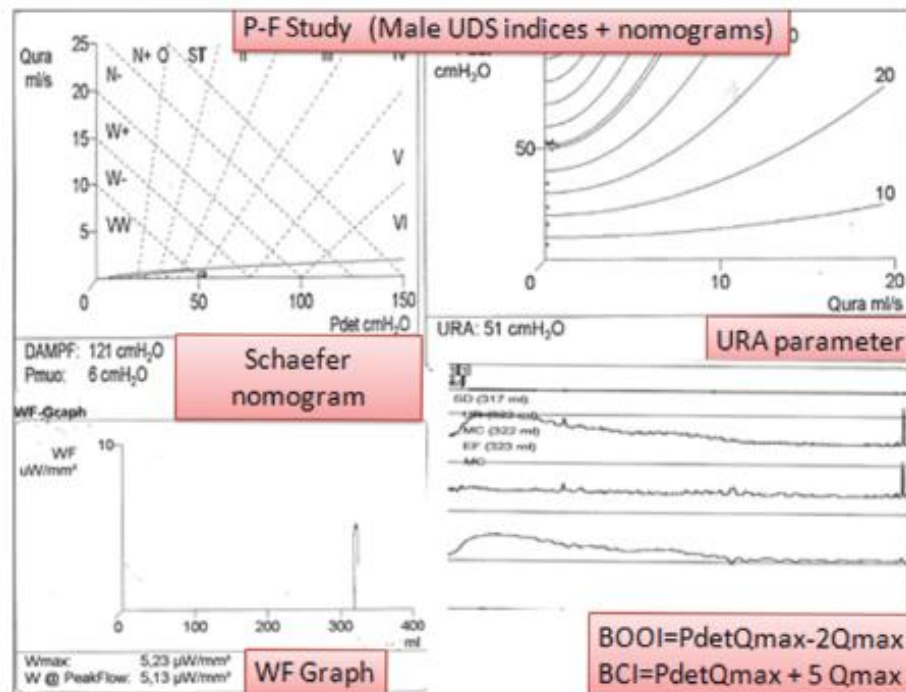
worth mentioning that all patients with  $WF_{max} < 10.85$  simultaneously had  $BCI < 100$ . It is also important to note that all 5 patients with  $LPURR \leq 2$ , according to Schafer's nomogram, had  $BCI < 100$ . Three of them exhibited normal isometric and fading contraction according to the Watts Factor graph, with mean PVR 5.6ml in free uroflowmetry, whereas the remaining 2 patients manifested combined isometric and fading hypocontractility with mean PVR 96ml. Out of the 5 patients with heavy BOO ( $LPURR = 6$ ), one had  $BCI = 72$  and  $WF_{max} = 6.64$  with PVR 181ml in uroflowmetry whereas the remaining four had  $BCI > 100$  but mean PVR 228.25ml. One out of these four patients presented normal isometric and fading contraction according to the Watts Factor graph and PVR 0ml in comparison with the remaining three patients who exhibited isotonic hypocontractility with PVR 304ml.

By  $LPURR \geq 3$  determining BOO based on Schafer's nomogram, the sensitivity of the  $BOOI \geq 40$  and  $URA \geq 29$  was 100%. With  $Pdet_{max} \geq 45$  and  $Q_{max} < 12 \text{ ml/sec}^6$  defining BOO, the total sensitivity of the parameters  $BOOI \geq 40$  and  $URA \geq 29$ , was calculated at 87.5% (v=28/32) and 96.9% (31/32), respectively. In the sub-group of the 5 patients with  $LPURR \leq 2$ , the sensitivity of  $BOOI \geq 40$  and  $URA \geq 29$  was calculated at 20% (v=1/5) and 80% (v=4/5), respectively. However, all 5 patients of this group were relatively obstructed based on the index of Kransé R and Van Mastricht R (Relative BOO =  $URA/W20 > 0.82$ )<sup>7</sup>.

## DISCUSSION

Even though low urinary output is mainly suggestive of obstruction, whereas any PVR volume is mainly suggestive of underactivity, the ideal BOO index should correspond to a strong positive linear correlation to PVR and at the same time to a strong negative linear correlation to the maximum flow for a theoretically confirmed and stable production by the detrusor muscle and gradual increase of resistances in urinary flow. On the contrary, the ideal index for detrusor contractility should reflect a strong positive linear correlation to maximum flow and simultaneously a strong negative linear correlation to PVR for a theoretical stable and consistent resistance to flow and gradually increased detrusor contraction strength. Based on the hypothesis and our study's outcomes, the parameter  $URA \geq 29$ , with the moderate negative linear correlation to the maximum flow and the moderate positive linear correlation to PVR, reaches the ideal BOO index compared to

**Figure 4:** Urodynamic indices and nomograms in evaluating P-F study in men



$BOOI \geq 40$  with no correlation to the maximum PVR and weak positive linear correlation to PVR. Respectively, the  $WF_{max}$  factor, with its weak negative linear correlation to PVR, reaches the ideal detrusor contraction index (DCI) to a greater extent than the bladder contractility index (BCI), exhibiting no correlation to the maximum urinary output and the PVR.  $BOOI$  and  $BCI$  urodynamic indices, albeit their great advantage (easy calculation), share the same two statistical parameters: detrusor pressure at maximum flow ( $P_{det}Q_{max}$ ) and maximum flow ( $Q_{max}$ ). The application of the same statistical parameters in the differential diagnosis between obstruction and underactivity, theoretically reduces the specificity in both of them. The strong positive linear correlation of these two factors in the present study, confirms the theory that they interact though they reduce their specificity in this way.

Conversely, the absence of any correlation between WFmax and URA, enhances their specificity in the differential diagnosis between hypocontractility and BOO, respectively.

In the most complicated cases treated by functional urologists, i.e. male patients with debatable obstruction ( $LPURR \leq 2$ ),  $URA \geq 29$  was found more sensitive compared to  $BOOI \geq 40$ . Aganovic et al. reached the same conclusion after a urodynamic investigation of 102 patients with benign prostatic enlargement (BPE)<sup>8</sup>.

According to R. Van Mastrigt et al., while significant statistical correlation was established between pre- and post-operative WFmax value to post-operative PVR, no significant correlation was found to pre-operative PVR<sup>9</sup>. Likewise, in our study, only a weak correlation was identified between the pre-operative WFmax and pre-operative PVR. The observation seems logical, since pre-operative PVR in BOO patients depends on the obstruction grade as well as on detrusor contractility. In fading contraction ( $W80-W20 < 0$ ), in cases with debatable obstruction ( $LPURR \leq 2$ ), it increases the sensitivity and specificity in DU diagnosis. In the present study, all patients with fading contraction and  $LPURR \leq 2$ , manifested synchronous isometric contraction ( $WFmax < 10.85$ ). In such cases, we can safely attribute fading contraction to structural detrusor failure and speculate the presence of zero or minimal post-operative contractility improvement. In contradistinction, in cases of heavy obstruction,  $LPURR \geq 5-6$ , an isolated fading contraction should not be diagnosed as DU for it is a consequence of severe BOO and not of detrusor contraction insufficiency. In cases of moderate obstruction,  $LPURR = 3-4$ , we cannot ascertain if the negative value of the  $W80-W20$  factor is induced by obstruction or hypocontractility; the WFmax value will clarify the condition. If WFmax is  $< 10.85$ , we can then diagnose obstruction accompanied with possible DU. However, in the present study no patient with moderate obstruction and fading contraction presented concurrent isometric hypocontractility. It seems that in BPO, isotonic hypocontractility precedes fading and if BOO is not early managed then the next stage is non-reversible isometric hypocontractility. As a result, the non-compensation of obstructive urination is evident by PVR and further reduction in maximum outflow. According to Cucchi et al., idiopathic DU seems to develop in two stages; the first stage, insufficient contraction duration, precedes that of additional reduction in the contraction strength<sup>10</sup>. If this is the case in non-obstructed patients, then it should also be confirmed in obstructed patients. BCI appears to approach only the isometric detrusor contraction and merely in cases of moderated and severe obstruction. BCI was within normal range,  $BCI > 100$ , in 80% (4/5) of the patients with severe obstruction ( $LPURR = 6$ ). But the fact is not particularly helpful. In patients with  $LPURR = 5-6$ , we need neither BCI nor WFmax. By definition, the patients in question present normal contractility ( $Pdetmax \geq 75$  cmH<sub>2</sub>O). Additionally, BCI, as a statistical value, provides us with no information on fading contraction; we cannot evaluate the total detrusor behaviour throughout the micturition phase, as the case is with the Watts graph.

The remark that the WFmax factor is independent from the BOO degree, has already been highlighted by Lecamwasam et al., in adult canine models<sup>11</sup>. They concluded that any

increase in the WFmax value in patients with chronic outlet obstruction reflects the true increase in detrusor contractility. According to Ronchi Pet al.<sup>12</sup> and Abrams P. et al.<sup>13</sup>, in patients with simultaneous detrusor overactivity (DO) and DU<sup>12</sup> and simultaneous DO and BOO<sup>13</sup>, who were managed with antimuscarinics (solifenacin and tolterodine, respectively), a BOOI reduce was observed during the urodynamic follow up while on antimuscarinic medication. Consequently, the administration of antimuscarinics either improves, even to a certain extent, the anatomic urinary obstruction (?) or BOOI is not duly specific to index anatomically increased flow resistances. So, acknowledging that BOOI cannot identify mild resistance increase in urine flow due to dysfunctional voiding, functional obstruction from anatomic obstruction, the encouraging results of Kaplan et al. regarding the safety of antimuscarinics and  $\alpha$ -blockers combined medication in obstructed urination could be tempered<sup>14</sup>. It is reminded that in the above study of Kaplan et al., the weak definition of obstructed urination assessed by BOOI (cut-off value 20) and the non-measurement of the prostate gland may have also included, in the final analysis of the results, a significant number of male subjects not with anatomic but rather with moderate dysfunctional obstructed voiding. Also, according to Al-Hayek S et al., BCI was higher in conservatively managed obstructed patients compared to surgically managed obstructed patients upon their 10-year urodynamic follow up<sup>15</sup>. The remark constitutes indirect evidence that BCI is significantly affected by obstruction. Surgical treatment of BOO, possible results in low detrusor pressures urination with subsequent BCI value reduction. It is a theoretical paradox that BOO transurethral treatment reduces the true detrusor contractility, as it seems to happen in ageing<sup>16</sup>, whereas conservative treatment of obstruction preserves it, according to Al-Hayek S et al.

Despite the limited number of BPO patients and the study's retrospective aspect, URA and WFmax urodynamic factors possibly approximate the theoretical ideal obstruction and contractility index to a higher degree than BOOI and BCI, respectively. Moreover, the absence of any linear correlation between URA and WFmax, theoretically increases their specificity in contrast with the strong linear correlation of BOOI and BCI which reduces the differential diagnostic specificity of their combination (obstruction versus hypocontractility). In our opinion, the rename of BCI from Bladder Contractility Index to Bladder Compensate Index, with prognostic value upon the post-operative outcome, would correspond better to the facts. Also in theory, it seems to have limited value in the assessment of detrusor contractility, secondary to obstruction surgical treatment, because it presumably directly and linearly depends on the obstruction degree. Recently, Elliott CS and Comiter CV reached to a similar conclusion during the video-urodynamic (VU) study of isometric detrusor contraction in males with urinary incontinence following radical prostatectomy, i.e. the procedure with the greatest possible reduction of passive resistances exercised by the prostate during micturition<sup>17</sup>. Detrusor contractility after the surgical treatment of obstruction should possibly be evaluated only according to the Watts graph.



## CONCLUSION

Based on the present study, the values of parameters  $URA \geq 29$  and  $BOOI \geq 40$  were found equally sensitive to the diagnosis of pure obstruction ( $LPURR \geq 3$ ), with URA being more sensitive in cases of debatable obstruction. In addition, URA is closer to the theoretically ideal evaluation index of passive resistances in urine flow. At the same time, WFmax factor is seemingly closer to the ideal evaluation index of detrusor contractility. Albeit the small cohort, it appears that the combination of URA-WFmax parameters is more specific compared to BOOI-BCI combination and we suggest its inclusion in the P-F study assessment, especially in cases of debatable BOO.

## REFERENCES

1. W.Schafer , H. Rubben , R. Noppney , F-J Deutz Obstructed and unobstructed prostatic obstruction. A plea for urodynamic objectivation of bladder outflow obstruction in benign prostatic hyperplasia. World J Urol (1989) 6:198-203.
2. P. Abrams Bladder outlet obstruction index, bladder contractility index and bladder voiding efficiency: three simple indices to define bladder voiding function. P. Abrams BJU International (1999) 84, 14-15.
3. P. Abrams Objective evaluation of bladder outlet obstruction.. British Journal of Urology (1975) , 76 .Suppl. 1,11-15.
4. Rosier PF, de Wildt MJ, de la Rosette JJ, Debruyne FM, Wijkstra H. Analysis of maximum detrusor contraction power in relation to bladder emptying in patients with lower urinary tract symptoms and benign prostatic enlargement.J Urol. 1995 Dec;154(6):2137-42.
5. Winters JC, Dmochowski RR, Goldman HB, Herndon CD, Kobashi KC, Kraus SR, Lemack GE, Nitti VW, Rovner ES, Wein AJ; American Urological Association; Society of Urodynamics, Female Pelvic Medicine & Urogenital Reconstruction.J Urol. 2012 Dec;188(6 Suppl):2464-72.
6. Jensen KME, Bruskevitz RC, Iversen P, Madsen PO. Predictive value of voiding pressures in benign prostatic hyperplasia. Neurourol. Urodyn 1983;2:117.
7. Kranse R, Van Mastricht R. Relative bladder outlet obstruction. J Urol. 2002 Aug; 168(2):565-70.
8. Aganovic D. The urodynamic nomogram in defining the degree of obstruction in patients with benign prostatic enlargement-defining clear obstruction. MedArt. 2003;57(2):81-6. Abstract

9. R. Van Mastricht, H.J. Rollema. The prognostic value of bladder contractility in transurethral resection of the prostate The Journal of Urology April 1992 , 24
10. Cucchi A, Quaglini S, Guarnaschelli C, Rovereto B. Urodynamic findings suggesting two-stage development of idiopathic detrusor underactivity in adult men. Urology. 2007 Jul;70(1):75-9.
11. Lecamwasam HS , Yalla SV , Cravalho EG , Sullivan MP The maximum watts factor as a measure of detrusor contractility independent of outlet resistance. Neurourol.Urodyn. 1998 ;17(6):621-35
12. Ronchi P, Gravina GL, Galatioto GP, Costa AM, Martella O, Vicentini C. Urodynamic parameters after solifenacin treatment in men with overactive bladder symptoms and detrusor underactivity. Neurourol Urodyn. 2009;28(1):52-7.
13. Abrams P, Kaplan S, De Koning Gans HJ, Millard R. Safety and tolerability of tolterodine for the treatment of overactive bladder in men with bladder outlet obstruction. J Urol. 2006 Mar;175(3 Pt 1):999-1004;
14. Kaplan SA, He W, Koltun WD, Cummings J, Schneider T, Fakhoury A. Solifenacin plus tamsulosin combination treatment in men with lower urinary tract symptoms and bladder outlet obstruction: a randomized controlled trial. Eur Urol. 2013 Jan;63(1):158-65.
15. Al-Hayek S, Thomas A, Abrams P. Natural history of detrusor contractility--minimum ten year urodynamic follow-up in men with bladder outlet obstruction and those with detrusor underactivity. Scand J Urol Nephrol Suppl. 2004; (215):101-8.
16. K.V. Mytilekas, M. Kalaitzi, E. Ioannidis, A. Apostolidis Prospective analysis of independent factors in males with refractory to initial pharmaceutical treatment lower urinary tract symptoms. Focus on quality of life. Hellenic Urology 2013, 25 :271-283
17. Elliott CS, Comiter CV. Maximum isometric detrusor pressure to measure bladder strength in men with postprostatectomy incontinence. Urology. 2012 Nov;80(5):1111-5.

# **Distal ureterectomy techniques in Laparoscopic Nephroureterectomy (LNU) and Robotic-assisted Laparoscopic Nephroureterectomy (RALNU) - A Review of the Literature.**

*Komninos Christos, Manolas Victor, Stravodimos Konstantinos.*

A' Urological Clinic, School of Medicine, National and Kapodistrian University of Athens, "Laiko" University Hospital, Attica

## **Corresponding author**

Komninos Christos, A' Urological Clinic, School of Medicine, National and Kapodistrian University of Athens, "Laiko" University Hospital, 17, Ag.Thoma street, PC 11527, Athens, Attica, Greece, Tel. 2132060800, Email:chrkom@yahoo.gr

## **Abstract**

Laparoscopic Nephroureterectomy and Robotic-Assisted Laparoscopic Nephroureterectomy are reported as alternative procedures to the open approach in the management of Upper Tract Transitional Cell Carcinoma (UTCC). Although, they are considered to be equivalently effective to Open Nephroureterectomy (ONU), controversy still exists regarding the best method for managing the distal ureter and bladder cuff during the laparoscopic and robotic-assisted laparoscopic approach.

This review describes the surgical steps, the advantages and disadvantages of several techniques used for ureter and bladder cuff resection including open excision, transurethral resection of ureteral orifice ('Pluck' Technique), ureteric intussusception and total laparoscopy or robotic-assisted laparoscopy. Although, the existing data does not confirm the superiority of one technique over another, total laparoscopic and robotic-assisted laparoscopic nephroureterectomy with complete laparoscopic dissection and suture reconstruction of ureter and bladder cuff seem to be better tolerated than open nephroureterectomy providing equal efficacy and without deteriorating the oncological outcome. Transurethral resection of the ureteric orifice and the bladder cuff after occlusion of the ureter with a balloon catheter seems to be an attractive alternative option for low

stage, low grade tumors of the renal pelvis and the proximal ureter, in case we would like to avoid a low abdominal incision.

### **Key words:**

*Distal Ureterectomy, Laparoscopic Nephroureterectomy, Robotic-Assisted Laparoscopic Nephroureterectomy, Bladder Cuff excision.*

## **Introduction**

Upper Tract Transitional Cell Carcinoma (UTTCC) accounts for 5% of all renal tumors and 5% of all urothelial tumors<sup>1</sup>. It commonly develops as multifocal, related to low grade disease and with increased recurrence rates<sup>2</sup>. Given the above disease characteristics, Open Nephroureterectomy (ONU) with bladder cuff excision constitutes the treatment choice of the urothelial carcinoma, irrespectively of the tumor's localization<sup>3</sup>.

Laparoscopic Nephroureterectomy (LNU) was initially reported back in 1991 as an alternative approach to ONU<sup>4</sup>. Though LNU is considered equivalent to ONU<sup>5</sup>, controversy still exists over the treatment of the ureter's distal part during LNU and Robotic-Assisted Laparoscopic Nephroureterectomy (RALNU). Until today, none of the said techniques prevails over another in terms of perioperative morbidity and oncological outcomes, and so the management of the distal part of the ureter is subject to the surgeon's discretion<sup>6</sup>.

In surgical oncology, the en bloc resection of the distal part of the ureter and bladder cuff represents the preferred method in managing urinary tract cancer, independently of the technique followed, i.e. ONU, RALNU or LNU<sup>7</sup>. Additionally, it is of great importance that the ureter is clipped prior to ureterectomy to avoid cancer cells dissemination in the perivesical space<sup>8</sup>.

The present review describes the surgical steps followed in every technique for the resection of the distal part of the ureter and bladder cuff when LNU or RALNU is performed and compares the advantages and disadvantages among them.

## **Advantages of Lnu and Ralnu**

Both LNU and RALNU offer the benefits of the minimally invasive techniques; less blood loss, reduced administration of post-operative analgesia and shorter hospitalisation<sup>9</sup>. Moreover, the Da Vinci Robotic System, with its advantageous properties, such as the 7 degrees of freedom, 3-dimensional imaging and tremor stabilization, is featured to significantly reduce the technical difficulty of the intra-corporeal suturing. The robotic instruments provide the surgeon with the ability to EndoWrist, which is of essential significance in the preparation and dissection of the distal ureter and bladder cuff since these anatomic elements are not easily approached due to the narrow width of the pelvic

cavity. However, despite the fact that the robot offers significant facilitation in resecting the ureter's distal part, the patient's re-positioning and the robot's re-docking are time-consuming processes and they prolong operation time.

## **Ureterectomy Techniques**

Total ureterectomy with the resection of the bladder cuff, the ipsilateral ureteral orifice and the surrounding vesical wall is deemed necessary, given it reduces the recurrence rate of the disease<sup>2, 10</sup>. The removal of an en block 'closed' system, followed by ureteral orifice occlusion, reflects the ideal method for ureter removal. The avoidance of urine leak is considered a significant parameter in the reduction of any possible cancer cells dissemination.

Several techniques have been reported in the resection of the distal ureter, such as open ureterectomy, ureteral orifice transurethral resection (TUR) ('pluck' technique), ureteric intussusception and total LNU or total RALNU<sup>11</sup>. The oncologic outcomes of the above techniques are summarized in **Table 1**.

## **Open Ureterectomy Technique**

Open ureterectomy technique is the gold-standard technique to which all the rest techniques are compared. It is usually performed subsequently to nephrectomy. The patient is put in a supine position and a modified Pfannenstiel or Gibson incision is performed. The distal ureter is initially clipped and then resected followed by the bladder cuff. The bladder cuff can be removed either extravesically or via posterior cystotomy, however, the intravesical approach is judged as the most reliable approach in the complete removal of the bladder cuff of the ureter. Subsequently, the bladder is stitched with continuous sutures in 2 layers. The specimen is removed through the same incision. Open ureterectomy can be combined with LNU as well as with RALNU<sup>12</sup>.

This particular technique is an excellent choice when managing tumors at the distal part of the ureter and conditions for accurate histological examination. Early ureter clipping reduces any possible cancer cells dissemination. Blind extravesical clipping of the ureter should be dealt with special care; the contralateral ureteral orifice may be damaged and the complete removal of the ureter's distal part is not guaranteed<sup>5</sup>. In addition, transvesical removal of the ureteral orifice should be avoided when the urinary bladder nests an active tumor.

The open transvesical method may deliver sufficient resection of the ureter's distal part and bladder cuff, yet, it violates the continuation of the wall of the urinary bladder both at the cystoscopy and the incision sites. Ureteral orifice TUR constitutes an attractive technique in avoiding the condition.

## Ureteral Orifice TUR ('Pluck' Technique)

The endoscopic resection of the ureteral orifice has been suggested as supplementary time in ONUs or LNUs, aiming to avoid low abdominal incisions<sup>13</sup>. It is achieved either by transurethral resection of the ureter's intra-wall segment via the resectoscope's loop or by an orbicular incision of the ureteral orifice using a Collins knife. The ureteral orifice's resection is performed in depth, up to the perivesical fat, allowing for the unrestricted extravesimal retraction of the ureter. It usually precedes LNU or RALNU, for which the patient has to be re-positioned on his/her side.

Termed as 'pluck' technique, this procedure is suggested as oncologically safe in patients with low stage tumors of the proximal ureter<sup>14</sup>. However, it does not constitute the applicable technique in multifocal diseases, tumors detected at the lower tertile of the ureter and in extensive carcinoma in situ, due to the increased possibility of cancer cells dissemination, local recurrence and positive surgical margins (+SM)<sup>15</sup>. Furthermore, the procedure is not advised in patients who underwent pelvic radiation and manifest active inflammatory conditions of the urinary bladder.

The non-occlusion of the ureter prior to its incision raises concerns over the possibility of cancer cells dissemination or extraperitoneal recurrences. To avert such condition, various modifications have been postulated<sup>16-19</sup>.

Tan et al. proposed that the LNU and the ureter's clipping should precede and then proceed with the ureteral orifice TUR with the Collins knife<sup>20</sup>.

Author	Y	f/u (m)	N	+SM (%)	VR (%)	PR (%)	Mean hospitalisation (d)	ToP
Palou <sup>13</sup>	1995	20	31	ND	0	0	ND	Pluck
Laguna <sup>17</sup>	2001	ND	129	ND	24	4	ND	Pluck
Wong <sup>23</sup>	2002	8	14	ND	14.2	0	2	Pluck no re-positioning
Nanigian <sup>30</sup>	2006	6	10	0	16	0	3	Robotic transvesical approach
Tsivian <sup>28</sup>	2007	11.6	13	0	0	0	3.8	Ligasure stapling
Agarwal <sup>19</sup>	2008	15	13	0	38	0	7.3	Pluck-Endoloop
Park <sup>22</sup>	2009	ND	5	0	ND	ND	8.4	RALNU, Hybrid port, no re-positioning
Zou <sup>17</sup>	2010	18	6	0	0	0	8	Transvesical
Hemal <sup>13</sup>	2011	Short-term	15	0	0	0	2.7	RALNU- no re-positioning of the patient or robot redocking
Giannakopoulos <sup>22</sup>	2012	31	10	ND	30	0	ND	Transvesical
Cormio <sup>18</sup>	2013	39.8	13		30.1	0	8.1	Pluck-occlusion balloon

(Y: Year, f/u: mean follow up, N: number of patients, +SM: Positive surgical margins, VR: vesical recurrence, PR: pelvic recurrence, ToP: type of procedure, ND: No data, RALNU: Robotic-assisted Laparoscopic Nephroureterectomy)

Another original technique was described by Agarewal et al. They suggested partial orbicular resection of the ureteral orifice with the Collins knife at first and then the insertion

of a PDS Endoloop through the cystoscope to ligate the ureteral orifice and finally to completely dissect it <sup>16</sup>.

Cormio et al.<sup>18</sup> recently described an innovative technique with the endoscopic placement of a 5-Fr Fogarty balloon catheter prior to the orbicular ureteral orifice TUR. The technique obstructs the affected ureter and urine leak is avoided. Complete ureteral obstruction is intraoperatively checked by intravenous instillation of 5ml of indigo carmine. According to their outcomes, the mean operative time of orifice TUR was 21 minutes; all subjects had negative surgical margins (-SM) and the resection site and the perivesical space were recurrence-free. The authors suggest the above technique as a simple and effective management choice of the intra-wall segment of the ureter during nephroureterectomy for it observes the oncological principle on extravesical cancer cells dissemination avoidance.

In 1999, Gill et al.<sup>19</sup> suggested an original albeit complex method of safe removal of the intra-wall part of the ureter using two 5mm laparoscopic trocars transvesically placed. In this modified 'pluck' technique, a ureteral catheter is introduced inside the affected ureter and an orbicular transurethral incision of the ureter with the Collins knife is performed. Next, the orifice is ligated with a transvesically placed Endoloop through the two trocars. Afterwards, the ureteral orifice is completely resected. The authors reported that the technique in question observes the basic oncologic principles of complete and controlled en bloc resection with minimal urine leak. Comparable techniques, though using 3 trocars but with similar outcomes, have been demonstrated by other authors as well <sup>21, 22</sup>.

Zou et al.<sup>17</sup> simplified Gill et al's technique by using a laparoscopic trocar in the bladder, through which an Hem-O-Lock clip was inserted for the ureter's obstruction. In this technique, assisted by a resectoscope, via which CO<sub>2</sub> is insufflated, pneumovesicum was established (10-12mmHg). The ureteral orifice and the bladder cuff are resected with the Collins knife. Next, a 10mm trocar is introduced inside the bladder, right above the symphysis pubis and under direct vision with the resectoscope. Then, using the forceps through the trocar, the resected ureteral orifice and the bladder cuff are retrieved to facilitate the placement of 1 or 2 Hem-O-Lock clips to occlude the ureter. The bladder defect is usually not sutured. The technique's results showed that no patient developed local or distant recurrence during their 18-month follow up. The authors reported that the use of air inside the bladder is presumed to minimize the possibility of cancer cells dissemination compared to the use of liquids, since no floating cells are present in the bladder.

In most of the aforementioned techniques, the extravesical management of the distal ureter can be realized with hand-assisted LNU. Wong et al.<sup>23</sup> described a hand-assisted LNU technique with cystoscopic en bloc resection of the distal ureter and the ureteral orifice, avoiding the introduction of a trocar in the bladder and the re-positioning of the patient. The patient is placed in a modified lithotomy position and his/her side, where the tumor is detected, is raised by 30° angle. Thusly, we are able to transvesically place the resectoscope for the resection of the ureteral orifice. The first step of the technique includes the transperitoneal LNU, subsequent to the clip placement in the ureter to avoid cancer cells

migration. The rest ureteral part is prepared endoscopically. In particular, while the surgeon provides hand-assisted extravesical tension on the ureter via a low abdominal incision, a second surgeon resects the ureteral orifice transurethrally with the Collins knife allowing for the manual en block removal of the specimen. In this technique, the bladder is not sutured whereas any cancer cells leakage can be averted with the occlusion of the distal ureter either via clips or manually. The authors stated that no patient relapsed after a 10,6-month follow up period.

Similar techniques, avoiding patient re-positioning, have been reported by Vardi et al.<sup>24</sup> with the use of a flexible cystoscope combined with a 5F electrode.

### **Ureteric intussusception**

Various modifications of this approach have been reported<sup>25,26</sup>; generally, a ureteral catheter is endoscopically inserted at the beginning of the procedure, seconded by nephrectomy. The ureter is prepared up to the bladder, ligaments are placed at the tip of the ureteral catheter to ensure its safety and then the ureter is resected above the catheter. In continuance, the patient is placed in a lithotomy position and the ureter is intravesically intussuscepted, exercising alternating stress on the ureteral catheter. Synchronously, a resectoscope is inserted alongside the reversed ureter to resect the orifice.

Ureteric intussusception is counter-indicated for intraureteral tumors and limited to low stage renal pelvic tumors.

### **Total LNU and total RALNU**

Total LNU and total RALNU include the technique of the laparoscopic or robotic-assisted preparation of the distal ureter, which is either extravesically resected- low 'stapling' technique- or is totally retrieved along with the surrounding vesical wall. The trocar spacing is similar to that of nephrectomy, albeit differentiated in that all the trocars are moved slightly caudally to ensure better access to the distal ureter. Mainly, they are used in the management of high stage tumors or endoscopically untreatable low stage extensive diseases.

Distal ureter extravesical laparoscopic resection staple-assisted technique has been proposed in an effort to reduce the operative time, while maintaining a dry urinary tract system and avoiding cancer cells dissemination. The technique comprises the initial placement of ureteric clips, followed by the preparation of the ureter up to the ureterovesical junction (UVJ); last, a stapling device (GIA stapler or large Hem-O-Lock clips) is laparoscopically inserted to perform a synchronous resection of the distal ureter and suturing of the vesical segment. If needed, complementary cystoscopic detachment of the ureteral orifice may be performed<sup>27</sup>. Respectively, the surrounding vesical wall can be laparoscopically staple-free resected with LigaSure<sup>28</sup>.



A simpler variation of the 'stapling' technique is the hand-assisted laparoscopic en bloc ureterectomy via a harmonic lancet, which seems to be time-effective<sup>29</sup>. During the 'stapling' technique, the surgeon must be very careful not to compromise the contralateral ureteral orifice or leave any residual parts of the ureter.

Several techniques have been reported on complete resection of the distal ureter, the bladder cuff and the bladder's suturing. Various combinations, such as total LNU or laparoscopic nephrectomy and robotic excision of the distal ureter<sup>30</sup> or total RALNU with or without re-positioning of the patient<sup>31,32</sup> or re-docking of the robot<sup>33</sup> have been reported to reduce operation time without limiting the visualisation and exposure of the distal ureter and the suturing of the bladder cuff. The basic principles of the above technique include the preparation of the distal ureter, the extravesical orbicular resection of the surrounding bladder deficit and finally the double-layer suturing of the bladder deficit. Commonly, the integrity of the suturing is assessed by filling the bladder with 120 ml of normal saline.

Nanigian et al.<sup>30</sup>, in an attempt to portray open ureterectomy, described a transvesical technique, using the robot to complete the ureterectomy. In this technique, laparoscopic nephrectomy precedes and then, the bladder is filled with 250ml of normal saline, followed by a robotic incision at the bladder dome and intravesical resection of the ureteral orifice. The bladder deficit is robotically sutured.

In total RALNU, as described by Tracy C.R<sup>31</sup>, a 12-mm trocar is laterally placed at the level of the umbilicus to facilitate the camera view and 3 8-mm robotic trocars are inserted in the midclavicular line 2-3 cm below the costal arch (A), in the anterior axillary line at the height of the camera's trocar (B) and in the midclavicular line approximately 8 cm below the camera's trocar (C), respectively. For the assistant working port, a fifth 12-mm trocar is placed in the median line, 5-8 cm supraumbilically. If the tumor is detected on the right side, an extra (sixth) 5-mm trocar can be placed in the median line below the xiphoid process to retract the liver. Subsequent to the completion of nephrectomy, the robotic arms are detached from the trocars (un-docking) while the patient maintains position. Next, the instrumentation is relocated so that trocar B houses the unipolar scissors converting into the surgeon's right hand and trocar C which houses the bipolar forceps converting into the surgeon's left hand. Trocar A is used as a 4<sup>th</sup> arm to assist in cystotomy and final restoration. The ureter is prepared up to the UVJ, a supportive suture is placed anteriorly the ureteral orifice's surface and the distal ureter and bladder cuff resection follow.

Park et al.<sup>23</sup> announced an innovative technique of total RALNU using a hybrid trocar. They inserted a 12-mm trocar supraumbilically to accommodate the camera and two robotic 8-mm trocars, the first in the lateral rectus margin, 3-4 mm infraumbilically and the second in the median line between the umbilicus and the xiphoid process. Additionally, a double-use assistant 12-mm hybrid trocar was introduced midway between the umbilicus and the symphysis pubis. The hybrid trocar houses the insertion of an 8-mm robotic trocar. After the completion of the robotic nephrectomy, the configuration of the trocars changed, i.e. the trocar for the first robotic arm during nephrectomy shifted into an assisting trocar for the

distal ureter management, the trocar for the second robotic arm during nephrectomy replaced the first robotic instrument for the ureter's resection and the assistant trocar during nephrectomy shifted into a second robotic instrument. The authors announced reduction of the total operative time by 50 minutes compared to patients re-positioned to lithotomy position, better exposure of the lower ureter and facilitation in suturing the bladder deficit.

Hemal et al.<sup>33</sup> revealed surgical secrets and described an original technique of total RALNU with bladder cuff excision not requiring re-positioning of the patient or re-docking of the robot. Surgical secrets for a successful procedure include the strategic configuration of the trocars to access the kidney, the ureter and the bladder and the early placement of ureter clips immediately after the ligation of the renal arteries. In this way, we minimize the risk of cancer cells dissemination during renal management, the wide bladder cuff excision, in cases where the tumor is detected in the ureter, and the placement of 'guiding sutures' laterally to the UVJ. In this technique, at the level of the umbilicus and laterally to the rectus sheath, one 12-mm trocar is placed for the camera and three 8-mm trocars are placed laterally to the rectus abdominal and 7-8cm cephalic to the camera trocar (A), laterally to the rectus abdominal and 7-8cm caudal to the camera trocar (B) and cephalic to the iliac crest in the anterior axillary line (C), respectively. A fifth assistant trocar is placed in the median line, 2-3cm cephalic or caudal to the umbilicus. For the nephrectomy and lymphadenectomy, trocar A is used as the right hand (unipolar scissors) and trocar C as the left hand (Maryland bipolar forceps). Trocar B is an assistant, useful in renal retraction (Prograsp forceps). Following the completion of nephrectomy, the Maryland bipolar forceps is attached to trocar B, the unipolar scissors to trocar C and the Prograsp forceps to trocar A. The instrumentation rearrangement assists in the easy management of the lower ureter. The authors reported that the certain technique produces excellent oncologic outcomes and reduces operative time.

Finally, a novel and promising nephroureterectomy technique is the Laparoendoscopic single-site surgery (LESS), which seems to deliver both operative and aesthetic favourable outcomes. In this particular technique, as described by Lim et al.<sup>34</sup>, one port wrapped by a No7 glove, is supraumbilically placed via an incision measuring 4-5 cm. Two 8-mm robotic trocars and two 12-mm assistant trocars are inserted through the 4 fingers of the glove. Nephroureterectomy is completed without re-positioning of the patient while the distal part of the ureter is extravesically removed along with the bladder cuff. Given the LESS technique is the most recent approach in nephroureterectomy, several other studies should be conducted in order to obtain safer conclusions.

### **Comparison of the Techniques**

The ideal procedure for nephroureterectomy is the removal of the whole ureter, avoiding the extravesical urine leak containing cancer cells, in reasonable operative time and with

fewer operative complications. A less radical treatment, leaving a residual ureteral abutment, is correlated with recurrence in one third of the patients<sup>35</sup>. All techniques should be compared to open ureterectomy, which remains the gold-standard technique.

Open ureterectomy can be performed either extravesically or intravesically. Li et al.<sup>36</sup> compared the two approaches to the 'pluck' technique and concluded that neither of them falls short in lower ureter and bladder cuff excision.

It is not clear whether distal ureter TUR allows for the +SM-free wide ureteral orifice excision. Local recurrence after the 'pluck' technique has been reported in a number of cases<sup>15, 37, 38</sup>. On the contrary, Palou et al.<sup>13</sup> reported that 31 patients who had undergone 'pluck' ureterectomy, manifested no local recurrence after a median follow up period of 20 months. The above outcomes stress the need for the conduction of randomized studies.

An interesting multicenter retrospective study was conducted on 2.681 patients by Xylinas et al.<sup>39</sup>. They compared 3 different approaches in distal ureter management and bladder cuff excision: intravesical, transvesical and extravesical. The study concluded that the endoscopic removal delivers a significantly higher rate of intravesical recurrences compared to the other two equivalent approaches. However, cancer-specific survival (CSS) and overall survival (OS) were the same in all three groups. Furthermore, the study assumes that the laparoscopic approach may constitute an independent factor of increased vesical recurrences. The hypothesis is established in a recently published retrospective study elaborated by the same author both in terms of single factor analysis (SFA) and multiple factor analysis (MFA)<sup>40</sup>.

It is still a matter of consideration whether the bladder defect should be sutured following the bladder cuff excision<sup>41</sup>. Brown et al's findings<sup>41</sup>, raise worries over the oncologic outcome when the cystotomy remains open, particularly in patients ailing in the lower ureteral tertile or the contralateral ureter or in patients with a history of urinary bladder neoplasm.

Comparing the 'pluck' technique to that of ureteric intussusceptions, Geavlete et al<sup>42</sup>, alleged that the two techniques share operative time, complications and oncologic outcomes. Their findings were also reproduced by other authors<sup>37</sup>.

Gill et al<sup>19</sup>, announced the distal ureter TUR assisted by two transvesically placed trocars, to achieve early ureter occlusion. Yet, the possibility of metastases at the incision sites creates preoccupation. Also, comparing the technique with the laparoscopic stapling technique, they reported that in the 'stapling' technique, +SM, local recurrences and distant metastases, albeit more frequent, were statistically insignificant<sup>43</sup>.

The laparoscopic stapling technique avoids cystotomy and consequently cancer cells dissemination is minimized. Nevertheless, the possibility of residual ureteral mucus, may lead to a higher frequency of +SM. Additionally, any remaining exposed staplers inside the bladder predispose for stone formation<sup>44</sup>; moreover, no histological assessment of the

TABLE 2		Comparative studies on ureterectomy techniques						
Author	Y	ToP	f/u (m)	N	+SM (%)	VR (%)	PR (%)	Mean hospitalisation (d)
Xylinas39	2012	Pluck vs extravesical vs transvesial	36 52 61	85 785 1811	ND	34 20 21 p=0.02	29 25 21 p=ND	ND
Brown41	2005	Pluck vs open vs Staple vs HAL	24 24 24 24	16 3 7 29	0 0 29 10 p=ND	ND	0 0 0 3 p=ND	ND
Matin43	2005	Pluck transvesical vs Lap Stapling	22 19	36 12	2.8 25	13.9 41.7 p=0.096	5.6 8.3 P=0.99	ND
Geavlete42	2007	Pluck vs intussusception	44 44	72 28	ND	17.9 23.6 p=ND	0 0	10 11 p=ND
Romero46	2007	Lap Stapling vs Open	54 39	12 12	25 0 p=0.1	50 33 p=0.23	25 8.3 p=0.24	3.8 4.2 p=0.56
Ko38	2007	Open vs Pluck	23.2 22.1	27 19	ND	22.2 26.3 p>0.05	0 0 p>0.05	7.8 7.3 p>0.05
Li36	2010	ONU (intravesical) vs ONU (extravesical) v Pluck	33 39 30	81 129 91	ND	23.5 24 17.6 P=0.48	7.4 7.8 5.5 P=0.79	ND
Ritch50	2011	Open vs Lap Stapling vs Total LNU	16 21 7	10 14 12	10 14 0 p=ND	20 29 0 p=ND	ND	3.5 2.7 2 P<0.05

(Y: Year, f/u: mean follow up, N: number of patients, ToP: type of procedure, +SM: Positive surgical margins, VR: vesical recurrence, PR: pelvic recurrence, , ND: No data, ONU: Open Nephroureterectomy, LNU: Laparoscopic Nephroureterectomy, HAL: Hand-Assisted Laparoscopic Nephroureterectomy)

margins can be carried out<sup>45</sup>. Many authors have compared several ureterectomy

techniques and reported higher rates of +SM and local recurrence in the laparoscopic stapling technique<sup>41,46</sup>. However, Tsivian et al. described a variation of the laparoscopic stapling; they used LigaSure Atlas in 13 patients and reported that the approach did not induce any local recurrence<sup>28</sup>.

Hand-assisted LNU is advocated as an intermediary technique between ONU and total LNU. In a prospective study, patients who had undergone hand-assisted LNU had less complications, shorter hospitalization and comparable oncologic outcomes in relation to ONU<sup>47</sup>. In a retrospective study comparing hand-assisted LNU to the laparoscopic stapling technique and the transurethral 'pluck' technique, Brown et al.<sup>41</sup> reported that the operative time was 60 to 90 minutes longer, the estimated blood loss and the duration of the catheterization were doubled or tripled in the 'pluck' technique, whereas the stapling technique exhibited higher rate of +SM compared to the other two groups. The authors suggested that the hand-assisted laparoscopic en bloc ureterectomy with bladder deficit suturing provides excellent control over the disease and can be performed without cystoscopy, thusly reducing the operative time.

Total LNU is not widely accepted at present. Disseminated tumor cells (DTCs) via the trocars continue to raise worries although, thankfully, it is uncommon and cited only in case reports<sup>48</sup>. However, recent data show similar oncologic outcomes between LNU and ONU; LNU prevails given the advantage of a minimally invasive technique<sup>7,49</sup>. LNU is reported as equivalent to ONU regarding the negative surgical margins (-SM), the frequency of local recurrences or metastases and CSS<sup>5</sup>. Total LNU can be performed either with total laparoscopic distal ureter and bladder cuff excision or with extravesical 'stapling'. The laparoscopic resection of the distal ureter followed by intracorporeal suturing of the bladder deficit theoretically combines the benefits of a minimally invasive technique with the oncologic outcome of the open technique. Ritch et al.<sup>50</sup> undertook a retrospective study in 36 patients. They compared open ureterectomy to the laparoscopic 'stapling' technique and the total laparoscopic distal ureter and bladder cuff excision. The study findings showed that the laparoscopic 'stapling' technique and the total laparoscopic distal ureter and bladder cuff excision require less operative time and shorter hospitalization compared to open ureterectomy. They also reported that in 50% of the patients who had undergone the 'stapling' technique, a residual ureteral orifice was present; the other two groups had no such patient. The authors concluded that patients with extensive disease of the lower ureter should be managed with open ureterectomy, whereas patients with low stage disease should better be managed with total laparoscopic ureterectomy.

The comparative studies of the several nephroureterectomy techniques are outlined in **Table 2**.

## **Conclusions**

Distal ureter excision constitutes an integral part of radical nephroureterectomy however the best technique to manage the distal ureter and bladder cuff resection remains questionable.

Current data do not confirm the superiority of one technique over another. Every technique has advantages and disadvantages; given that the majority of the data derives from case reports or retrospective studies, the conduction of prospective, randomized studies is deemed necessary. Moreover, there is a lack in studies directly comparing LNU to RALNU. In any case, total LNU and total RALNU with whole distal ureter and bladder cuff excision apparently provides equal efficacy and is better tolerated than open nephroureterectomy even though the latter remains the gold-standard, especially when expanded disease of the distal ureter is present. And with the strategic placement of the trocars, there is no need for patient re-positioning or robot re-docking. Similarly favourable results are cited for the hand-assisted laparoscopic nephroureterectomy.

Alternatively, in case we wish to avoid low abdominal incision, the ureteral orifice TUR, secondary to the placement of a balloon catheter for ureteral occlusion, appears to be an attractive choice in the management of low stage diseases in the renal pelvis and the

proximal ureter. However, intravesical approaches always bear the risk of increased intravesical recurrences. Laparoscopic ‘stapling’ technique presents a rather increased risk of +SM, excluding the cases where LigaSure is used.

## Περίληψη

Η Λαπαροσκοπική Νεφροουρητηρεκτομή και η Ρομποτικά Υποβοηθούμενη Λαπαροσκοπική Νεφροουρητηρεκτομή αναφέρονται ως εναλλακτικές επιλογές της Ανοικτής Νεφροουρητηρεκτομής στη διαχείριση ασθενών με Καρκίνο Αποχετευτικής μοίρας του Ουροποιητικού Συστήματος. Παρόλο που όμως θεωρούνται ισοδύναμες επεμβάσεις με την Ανοικτή Νεφροουρητηρεκτομή, παραμένει αμφιλεγόμενο ποιος τρόπος είναι ο καλύτερος όσον αφορά την αντιμετώπιση του άπω τμήματος του ουρητήρα και την εκτομή της ενδοκυστικής μοίρας αυτού.

Η παρούσα ανασκόπηση περιγράφει τα χειρουργικά βήματα και τα πλεονεκτήματα και Μειονεκτήματα των διάφορων τεχνικών που χρησιμοποιούνται για την εκτομή του τελικού τμήματος του ουρητήρα, όπως είναι η ανοικτή ουρητηρεκτομή, η διουρηθρική εκτομή του ουρητηρικού στομίου (‘pluck’ τεχνική), η τεχνική εγκολεασμού του ουρητήρα και η ολική Λαπαροσκοπική ή ολική Ρομποτικά-Υποβοηθούμενη Λαπαροσκοπική εκτομή του ουρητήρα. Αν και οι υπάρχουσες μελέτες δεν επιβεβαιώνουν την ανωτερότητα κάποιας τεχνικής συγκριτικά με κάποια άλλη, η ολική Λαπαροσκοπική και η ολική Ρομποτικά-Υποβοηθούμενη Λαπαροσκοπική Νεφροουρητηρεκτομή με καθολική εκτομή της ενδοκυστικής μοίρας του ουρητήρα και του κυστικού τοιχώματος που τον περιβάλλει φαίνεται να είναι καλύτερα Ανεκτές σε σχέση με την ανοικτήν νεφροουρητηρεκτομή, παρέχοντας ισοδύναμη αποτελεσματικότητα, χωρίς να επηρεάζουν το Ογκολογικό αποτέλεσμα. Εναλλακτικά, σε περίπτωση που θέλουμε να αποφύγουμε τη Χαμηλή κοιλιακή τομή, η διουρηθρική εκτομή του ουρητηρικού στομίου, μετά από τοποθέτηση ουρητηρικού καθετήρα με μπαλόνι απόφραξης, φαίνεται να αποτελεί μια καλή επιλογή για νόσους χαμηλού σταδίου της νεφρικής πυέλου και του εγγύς μωρητήρα.

## Λέξεις ευρητηριασμού

Άπω ουρητηρεκτομή, Λαπαροσκοπική Νεφροουρητηρεκτομή, Ρομποτικά –Υποβοηθούμενη Λαπαροσκοπική Νεφροουρητηρεκτομή, εκτομή κυστικού τμήματος ουρητήρα

## References

1. J. J. Munoz, L. M. Ellison. Upper tract urothelial neoplasms: incidence and survival during the last 2 decades. The Journal of Urology 2000; 164(5):1523–1525.

2. M. C. Hall, S. Womack, A. I. Sagalowsky, et al. Prognostic factors, recurrence, and survival in transitional cell carcinoma of the upper urinary tract: a 30-year experience in 252 patients. *Urology* 1998; 52(4): 594–601.
3. Roupret M, Zigeuner R, Palou J, et al. European guidelines for the diagnosis and management of upper urinary tract urothelial cell carcinomas: 2011 update. *Eur Urol* 2011; 59: 584–594.
4. Clayman RV, Kavoussi LR, Figenschau RS, Chandhoke PS, Albala DM. Laparoscopic Nephroureterectomy: initial clinical case report. *J Laparoendosc Surg* 1991; 1: 343–349.
5. Tsujihata M, Nonomura N, Tsujimura A, Yoshimura K, Miyagawa Y, Okuyama A. Laparoscopic Nephroureterectomy for upper tract transitional cell carcinoma: comparison of laparoscopic and open surgery. *Eur Urol* 2006; 49: 332–336.
6. Viprakasit DP, Macejko AM, Nadler RB. Laparoscopic Nephroureterectomy and management of the distal ureter: A review of current techniques and outcomes. *Adv Urol* 2009:721371.
7. Klingler HC, Lodde M, Pycha A, Remzi M, Janetschek G, Marberger M. Modified laparoscopic nephroureterectomy for treatment of upper urinary tract transitional cell cancer is not associated with an increased risk of tumour recurrence. *Eur Urol* 2003; 44: 442–447.
8. Kurzer E, Leveillee RJ, Bird VG. Combining hand assisted laparoscopic nephroureterectomy with cystoscopic circumferential excision of the distal ureter without primary closure of the bladder cuff-is it safe? *J Urol* 2006; 175: 63–67.
9. Keeley FX Jr, Tolley DA. Laparoscopic Nephroureterectomy: making management of upper – tract transitional cell carcinoma entirely minimally invasive. *J Endourol* 1998; 12: 139–142.
10. D. M. Murphy, H. Zincke, W. L. Furlow. Management of high grade transitional cell cancer of the upper urinary tract, *The Journal of Urology* 1981,125; 1: 25–29.
11. Macejko AM, Pazona JF, Loeb S, Kimm S, Nadler RB. Management of distal ureter in laparoscopic Nephroureterectomy - a comprehensive review of techniques. *Urology* 2008; 72 : 974–981.
12. Rose K, Khan S, Godbole H, Olsburgh J, Dasgupta P. Robotic-assisted retroperitonscopic nephro-ureterectomy- first experience and the hybrid port technique. *Int Clin Pract* 2006; 60: 12–14.
13. Palou J, Caparro's J, Orsola A, et al. Transurethral resection of the intramural ureter as the first step of nephroureterectomy. *J Urol* 1995; 154: 43–44.
14. Phe V, Cussenot O, Bitker MO, Roupret M. Does the surgical technique for management of distal ureter influence the outcome after nephroureterectomy? *BJU Int* 2011; 108: 130–138.
15. Arango O, Bielsa O, Carles J, Gelabert-Mas A. Massive tumor implantation in the endoscopic resected area in modified nephroureterectomy. *J Urol* 1997; 157: 1839.

16. Agarwal DK, Khaira HS, Clarke D, Tong R. Modified transurethral technique for the management of distal ureter during laparoscopic assisted nephroureterectomy. *Urology* 2008; 71: 740–743.
17. Zou X, Zhang G, Wang X, Yuan Y, Xiao R, Wu G, Long D, Xu H, Wu Y, Liu F. A one-port pneumovesicum method in en bloc laparoscopic nephroureterectomy with bladder cuff resection is feasible and safe for upper tract transitional cell carcinoma. *BJU Int* 2011;108: 1497–1500.
18. Luigi Cormio, Oscar Selvaggio, Giuseppe Di Fino, Paolo Massenio, Pasquale Annese, Jean de la Rosette, Giuseppe Carrieri. Transurethral Distal Ureter Balloon Occlusion and Detachment: A Simple Means of Managing the Distal Ureter During Radical Nephroureterectomy. *J Endour* 2013; 27:139-142.
19. Gill IS, Soble JJ, Miller SD, Sung GT. A novel technique for management of the en bloc bladder cuff and distal ureter during laparoscopic nephroureterectomy. *J Urol* 1999; 161: 430–434.
20. B. J. Tan, M. C. Ost, B. R. Lee. Laparoscopic nephroureterectomy with bladder-cuff resection: techniques and outcomes. *J Endour* 2005; 19: 664-676.
21. Cheng CW, Ng CF, Mak SK, Chan SY, Wong YF, Chan CK, Chan LW, Laparoscopic Transvesical Resection of an En Bloc Bladder Cuff and Distal Ureter during Nephroureterectomy. Pneumovesi- cum method in en-bloc laparoscopic nephroureterectomy with bladder cuff resection for upper-tract urothelial cancer. *J Endour* 2007; 21: 359–363.
22. Stilianos Giannakopoulos, George Toufas, Charalampos Dimitriadis, et al. Laparoscopic Transvesical Resection of an En Bloc Bladder Cuff and Distal Ureter during Nephroureterectomy. *Scientific World Journal*. 2012; doi: 10.1100/ 2012/ 658096.
23. C. Wong, R. J. Leveillee. Hand-assisted laparoscopic nephroureterectomy with cystoscopic en bloc excision of the distal ureter and bladder cuff. *J Endour* 2002; 16(6): 329–332.
24. I. Y. Vardi, J. A. Stern, C. M. Gonzalez, S. Y. Kimm, R. B. Nadler. Novel technique for management of distal ureter and en block resection of bladder cuff during hand-assisted laparoscopic nephro-ureterectomy. *Urology* 2006; 67 (1): 89–92.
25. R. V. Clayman, G. L. Garske, P. H. Lange. Total nephroureterectomy with ureteral intussusception and transurethral ureteral detachment and pull-through. *Urology* 1983; 21(5) :482–486.
26. S. Roth, H. van Ahlen, A. Semjonow, L. Hertle. Modified ureteral stripping as an alternative to open surgical Ureterectomy. *The Journal of Urology* 1996; 155(5):1568–1571.
27. McDougall EM, Clayman RV, Elashry O. Laparoscopic nephroureterectomy for upper tract transitional cell cancer: The Washington University experience. *J Urol* 1995;154: 975–980.



28. A. Tsivian, S. Benjamin, A. A. Sidi. A sealed laparoscopic nephroureterectomy: a new technique. *European Urology* 2007; 52 (4):1015-1019.
29. McGinnis DE, Trabulsi EJ, Gomella LG, Strup SE. Hand assisted laparoscopic nephroureterectomy: description of technique. *Tech Urol* 2001; 7: 7–11.
30. Nanigian DK, Smith W, Ellison LM. Robot Assisted laparoscopic Nephroureterectomy. *J Endour* 2006; 20: 463-465.
31. Tracy C.R Robotic Assisted Laparoscopic Nephroureterectomy Technique. <http://emedicine.medscape.com/article/2036769>.
32. Park SY, Jeong W, Ham WS, Kim WT, Rha KH. Initial experience of robotic nephroureterectomy: a hybrid-port technique. *BJU Int.* 2009; 104(11): 1718-1721.
33. Hemal AK, Stansel I, Babbar P, Patel M. Robotic-assisted nephroureterectomy and bladder cuff excision without intraoperative repositioning. *Urology* 2011; 78(2): 357-364.
34. Lim SK, Shin TY, Rha KH. Current status of robot assisted laparoscopic radical nephroureterectomy for management of upper tract urothelial carcinoma. *Curr Urol Rep.* 2013;14(2):138-46.
35. Cummings KB. Nephroureterectomy: rationale in the management of transitional cell carcinoma of the upper urinary tract. *Urol Clin North Am* 1980; 7: 569-78.
36. Li WM, Shen JT, Li CC, Ke HL, Wei YC, Wu WJ, Chou YH, Huang CH. Oncologic outcomes following three different approaches to the distal ureter and bladder cuff in nephroureterectomy for primary upper urinary tract urothelial carcinoma. *Eur Urol* 2010; 57(6): 963-969.
37. M. P. Laguna and J. J. M. C. H. de la Rosette. The endoscopic approach to the distal ureter in nephroureterectomy for upper urinary tract tumor. *The Journal of Urology* 2001; 166(6): 2017–2022.
38. R. Ko, B. H. Chew, D. R. Hickling, H. Ravzi, P. Luke, J. Chin, J. Izawa, S. Pautler. Transitional-cell carcinoma recurrence rate after nephro- ureterectomy in patients who undergo open excision of bladder cuff v transurethral incision of the ureteral orifice. *J Endour*; 21(7): 730–734.
39. Xylinas E, Rink M, Cha EK, et al. Impact of Distal Ureter Management on Oncologic Outcomes Following Radical Nephroureterectomy for Upper Tract Urothelial Carcinoma. *Eur Urol.* 2012. doi:10.1016/j.eururo.2012.04.052.
40. Xylinas E et al. Intravesical recurrence after radical nephroureterectomy for upper tract urothelial carcinomas: predictors and impact on subsequent oncological outcomes from a national multicenter study. *World J Urol* 2013;31:61-8.
41. J.A Brown, S. Strup, E. Chenven, D. Bagley, L. Gomella. Hand - Assisted Laparoscopic Nephro- ureterectomy: Analysis of distal ureterectomy technique, margin status and surgical outcomes. *Urology* 2005; 66(6): 1192-1196.
42. Geavlete P, Georgescu D, Bancu S, Mirciulescu V. Endoscopic ureteral procedures for one-step nephroureterectomy: experience in 100 cases. *J Endour* 2007; 21(9): 1019-1024.

43. Matin SF, Gill IS. Recurrence and survival following laparoscopic radical nephroureterectomy with various forms of bladder cuff control. *J Urol* 2005; 173: 395–400.
44. Baughman SM, Sexton W, Bishoff JT. Multiple intravesical linear staples identified during surveillance cystoscopy after laparoscopic nephroureterectomy. *Urology* 2003; 62: 351.
45. Venkatesh R, Rehman J, Landman J, Lee D, Ragab ME, Sundaram CP, Humphrey PA, Clayman RV. Determination of cell viability after laparoscopic tissue stapling in a porcine model. *J Endour* 2005; 19(6): 744–747.
46. R. Romero, E. M. Schaeffer, M. Muntener, B. Trock, L. R. Kavoussi, and T. W. Jarrett. Oncologic outcomes of extravesical stapling of distal ureter in laparoscopic nephroureterectomy. *J Endour* 2007; 21(9): 1025–1027.
47. B. D. Seifman, J. E. Montie, J. S. Wolf Jr. Prospective comparison between hand-assisted laparoscopic and open surgical nephroureterectomy for urothelial cell carcinoma. *Urology* 2001; 57(1): 133–137.
48. A. M. Ong, S. B. Bhayani, C. P. Pavlovich. Trocar site recurrence after laparoscopic nephroureterectomy. *The Journal of Urology* 2003; 170(4): 1301.
49. Schattemann P, Chatzopoulos C, Assenmacher C, et al. Laparoscopic nephroureterectomy for upper urinary tract transitional cell carcinoma: results of a Belgian retrospective multicentre survey. *European Urology* 2007; 51(6): 1633–1638.
50. C. R. Ritch, J. T. Kearns, A. C. Mues, G. W. Hruby, M. C. Benson, J. M. McKiernan, J. Landman. Comparison of distal ureteral management strategies during laparoscopic nephroureterectomy. *J Endour* 2011; 25 (7):1149–1154.

# Pathophysiology and severity based proposed urodynamic classification of detrusor bladder neck dyssynergia.

Mytilekas K.V., Kalaitzi M., Ioannidis E., Apostolidis A.

2nd Department of Urology. Aristotle University of Thessaloniki, Greece

Corresponding author:

Konstantinos Vaios Mytilekas, E - mail: vaiosmytilekas@gmail.com

## Abstract

**Aims :** to propose a novel urodynamic classification of neurogenic bladder neck dysfunction due to suprasacral lesions.

**Material and Methods:** Thirty three male patients with suprasacral infrapontine lesion and detrusor bladder neck dyssynergia confirmed upon cystourethrography were classified as following: Group O [Pdetopen prior to Pdetmax , Tqmax  $\geq$  1/3 Tq at free uroflow, incomplete bladder neck opening during cystourethrography], Group IA (increased Topen, high amplitude terminal neurogenic detrusor overactivity –TNDO-, Pdetopen after Pdetmax with abdominal straining during pressure flow study), Group IB (increased Topen, high amplitude TNDO, Pdetopen after Pdetmax without abdominal straining during pressure flow study), Group II (high pressure and high velocity TNDO with Pdetopen after Pdetmax) and Group III (active reduced compliance with detrusor leak point pressure at or after Pdetmax).

**Results:** Absence of free urination was reported at 0% (0/2), 16.67% (2/12), 66.67% (4/6), 100% (4/4) and 100% (9/9) of group O, IA, IB, II and III, respectively. Mean value of maximum free flow (Qmax) was 17.4, 12.4 and 4.1 ml/sec for group O, IA and IB, respectively. Interrupted voiding pattern during free uroflow, at percentage greater than 50% of all the recorded flows per patient, was 0% (0/2), 100% (10/10) and 100 % (2/2) respectively. Spastic paraplegia was present in 0%(0/2), 8.3%(1/12), 83.3%(5/6), 100%(4/4) and 100%(9/9), bilateral normal perineal sensation (PS) was recorded at 50%(1/2), 25%(3/12), 16.7%(1/6), 0%(0/4), 0%(0/9) while “normal” bladder sensation during cystomanometry was found at 100%(2/2), 50% (6/12), 20%(1/6), 0%(0/4), 0%(0/10) of groups O, IA, IB, II and III, respectively.

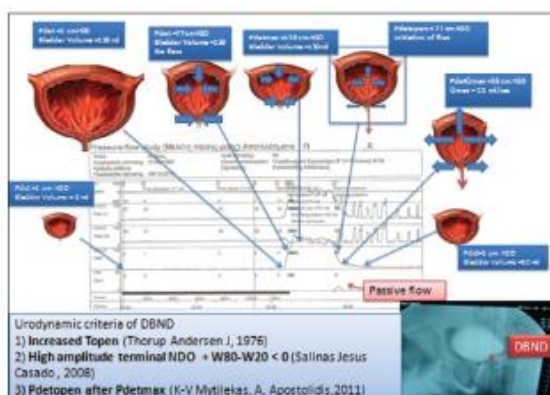
**Conclusions:** The classification proposed in this pilot study represents five increasing severity degrees of NDO with progressively increased degree of detrusor bladder neck dyssynergia.

**Key Words :**

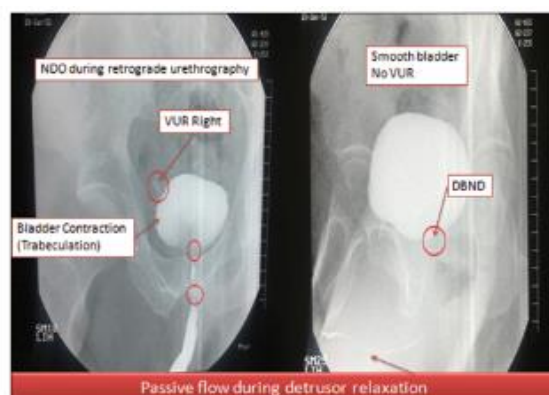
Detrusor Bladder Neck Dyssynergia, Urodynamic Classification

**Introduction:**

As detrusor bladder neck dyssynergia (DBND) is defined the simultaneous active bladder neck contraction during neurogenic detrusor contraction <sup>(1), (2)</sup>. Delayed relaxing and non-relaxing bladder neck are other distinct aspects of neurogenic bladder neck dysfunction <sup>(3)</sup>. Detrusor external sphincter dyssynergia (DESD) or detrusor pelvic floor dyssynergia is the result of instable contraction of external sphincter (ES) or pelvic floor muscles during urination causing fluctuations at free uroflow <sup>(4)</sup>. It is well known that all of these situations are observed in patients with suprasacral infrapontine lesions. In such a case, the sympathetic and parasympathetic centre of urination are totally intact but the coordination between them by the pontine center of micturition is lost. They may coexist on the same patient but they are not synonymous. It is also known that normal reflexes are responsible for pelvic floor and bladder neck contraction during any sudden increase in intravesical pressure in order to avoid incontinence. It is an assumption that DBND and DESD is the result of an excessive stimulation of those guarding reflexes with active bladder neck contraction and pelvic floor muscles contraction to any increase of intravesical pressure. It seems logical, the degree of DBND to be increased with the established degree of supra-sacral infrapontine spinal cord lesion. Current urodynamic observations at patients with DBND is the increased opening time (Topen) <sup>(5)</sup>, the high amplitude of terminal neurogenic detrusor overactivity (NDO), the isotonic (W80-W20 negative value) detrusor underactivity (DU) <sup>(6)</sup> and, the proposed by the authors, detrusor opening pressure following the detrusor maximum pressure (Pdetopen after Pdetmax) <sup>(7)</sup>.



**Figure 1.** Proposed pathophysiology and urodynamic criteria of detrusor bladder neck dyssynergia



**Figure 2.** Flow during DBND is actually passive in nature during simultaneous detrusor and bladder neck relaxation

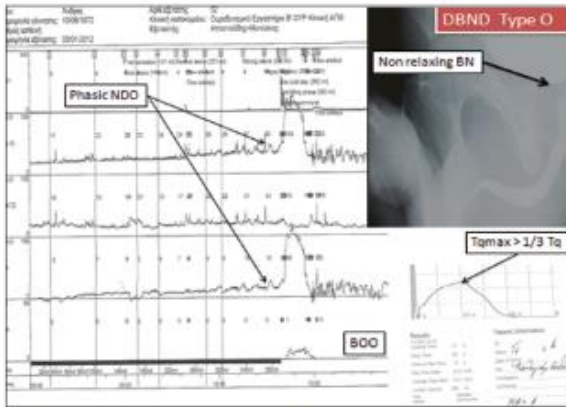
DBND Types		UDS criteria	Neurological Examination	Free Urination
Type O	Non relaxing or delayed relaxing BN	High pressure Pdetopen (>40) Phasic + terminal NDO Pdetopen prior to Pdetmax Normal Bladder Sensation	BCR: Present VCAS: Normal or Reduced AT: Normal or Increased PS: Normal or Unilateral mild impaired	Yes ( $Tq_{max} > 1/3 Tq$ )
Type IA	Active contraction of BN during NDO	Increased Topen High amplitude terminal NDO Pdetopen after Pdetmax Sensation of NDO Abdominal Straining	BCR: Present VCAS: Absent AT: Normal or Increased PS: Normal or Unilateral mild impaired	Yes/No (Interrupted flow pattern) (Distal voiding BVE < 80%)
Type IB	Active contraction of BN during NDO	Increased Topen High amplitude terminal NDO Pdetopen after Pdetmax Severely reduced or non specific sensation of NDO No abdominal straining	BCR: Present VCAS: Absent AT: Normal or Increased PS: Bilateral severe impaired	No/Yes
Type II	Active contraction of BN during NDO	High velocity terminal NDO Pdetopen after Pdetmax Absence or non specific sensation of NDO No abdominal straining	BCR: Present VCAS: Absent AT: Normal or Increased PS: Bilateral severe impaired	No
Type III	Active contraction of BN during NDO	Reduced compliance (Active) High Pressure DLPP at or after Pdetmax Absence or non specific sensation of NDO No abdominal straining	BCR: Present VCAS: Absent AT: Normal or Increased PS: Bilateral severe impaired	No

**Figure 3.** Proposed classification of neurogenic detrusor bladder neck dysfunction

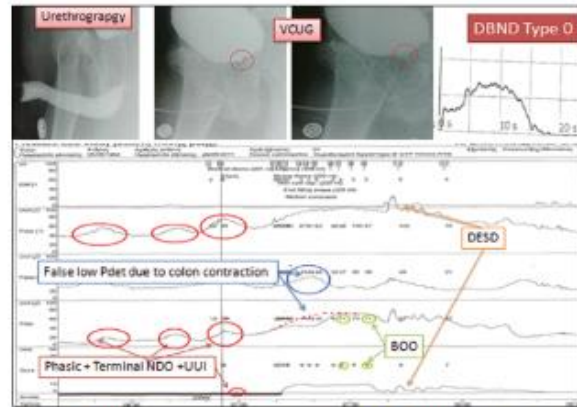
**Material Study:** Thirty three male patients with neurologic and MRI diagnosis of suprasacral infrapontine spinal cord lesion and one patient with mild spastic paraparesis under neurological evaluation whose MRI scan was normal, were retrospectively evaluated. Inclusion criteria were: the availability of the urodynamic study (UDS), normal or increased anal tone during basic neurological examination and at least two recorded free uroflow and voiding cystourethrography examinations of patients with ability to void. Patients with ability to void were sub-classified as Group 1 while patients with urination disability were sub-classified as Group 2. Patients main classification, based on urodynamic criteria, was the following: **Group O (n=2)** (Pdetopen >40cmH<sub>2</sub>O prior to Pdetmax, bladder neck dysfunction during voiding cystography, continuous free flow with  $Tq_{max} > 1/3 Tq$ ), **Group IA (n=12)** (Pdetopen after Pdetmax, increased Topen, high amplitude terminal NDO, abdominal straining during pressure flow study), **Group IB (n=6)** (Pdetopen after Pdetmax, increased Topen, high amplitude terminal NDO, without abdominal straining), **Group II (n=4)** (high velocity NDO with Pdetopen after Pdetmax) and **Group III (n=9)** (active reduced compliance with DLPP >40cm H<sub>2</sub>O at or after Pdetmax).

## Results:


Patient's sub-classification to group 1 included 2 patients of group O (2/2 or 100%), 10 patients of group IA (10/12 or 83.3%) and 2 patients of group IB, (2/6 or 33.3%) respectively. Mean value of maximum free flow (Q<sub>max</sub>) was 17.4, 12.4 and 4.1 ml/sec, respectively. Mean value of bladder voiding efficiency (BVE=  $VV/(VV+PVR) \times 100$ ) during free uroflow was 74.7%, 45% and 26%, respectively. Interrupted voiding pattern during free uroflow, at percentage greater than 50% of all the recorded flows per patient was 0% (0/2), 100% (10/10) and



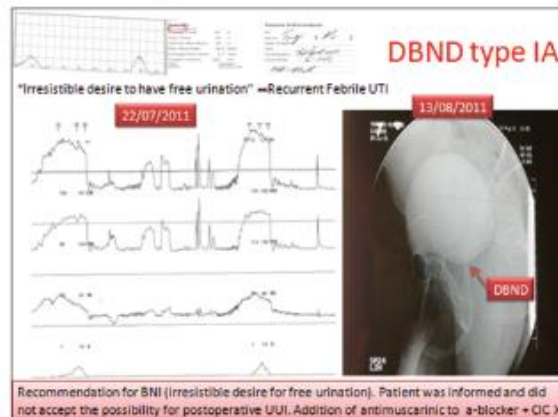
**Figure 4.** Detrusor bladder neck dysfunction type 0. Non-relaxing bladder neck



**Figure 5.** Detrusor bladder neck dysfunction type 0. Delayed incomplete relaxing bladder neck

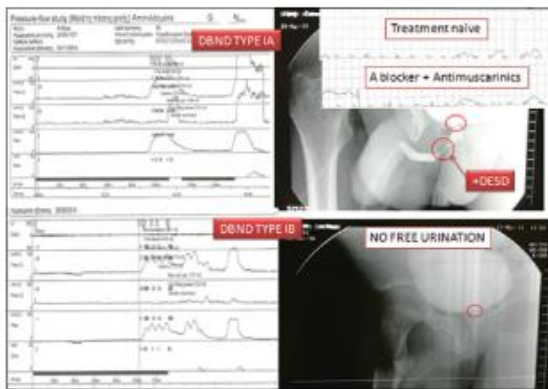


**Figure 6.** Pattern of detrusor bladder neck dyssynergia type I with terminal high amplitude NDO, increase Topen and Pdetopen after Pdetmax

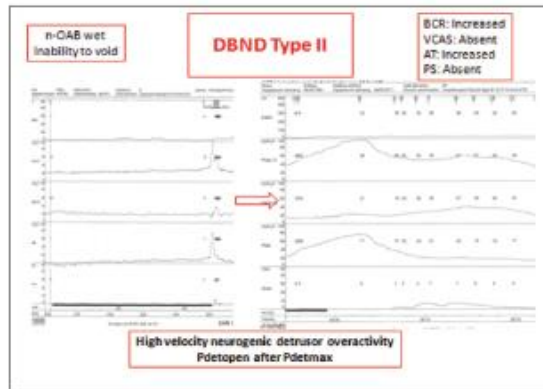


**Figure 7.** DBND Type IA. Abdominal straining during voiding. History of free urination with bladder voiding efficiency (BVE) <60%

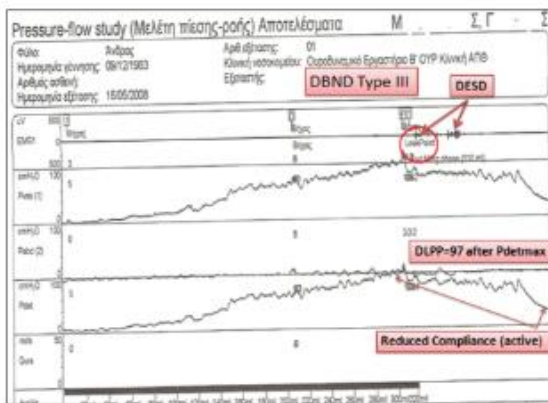
100%(2/2) respectively. At patient's group 2, was sub-classified the 16.7 % (2/10), 66.7% (4/6), 100% (4/4) and 100% (9/9) of patients of groups IA, IB, II and III, respectively. Spastic paraplegia (wheelchair patients) was present at 0%(0/2), 8.3%(1/12), 83.3%(5/6), 100%(4/4) και 100%(9/9) of groups O, IA, IB, II and III, respectively. Unobservable (reported by the patient) motility impairment was present only at group O, while all the rest patients with observable motility impairment and spastic paraparesis were already classified at group IA, 91.17%(11/12) and group IB 16.7%(1/6), respectively. Present or increased bulbocavernosum reflex (BCR), totally absent voluntary control of anal sphincter (VCAS), normal or increased anal tone (AT) was recorded at 100%, 93.9% (31/33) and 100% of all patients, respectively. One patient at group O and one patient at group IA had reduced but present VCAS. Bilateral normal perineal sensation (PS) was recorded at 50%(1/2), 25%(3/12), 16.7%(1/6), 0%(0/4), 0%(0/9) of groups O, IA, IB, II and III, respectively. Unilateral reduced PS was found at 50% (1/2), 33.3% (4/12), 16.7 (1/6), 25% (1/4), 11.1% (1/9) of groups O, IA, IB, II and III, respectively. Severe bilateral reduced PS was found at 0%(0/2), 16.7%(2/12), 33.3%(2/6), 25%(1/4), 22.2%(2/9) of groups O, IA, IB, II and III, respectively. Totally absent PS




**Figure 8.** DBND Type I with abdominal straining (Type IA) and without abdominal straining (Type IB)



**Figure 9.** DBND Type II




**Figure 10.** DBND Type III. Active reduced compliance with high detrusor leak point pressure after Pdetmax. Obstructive uropathy

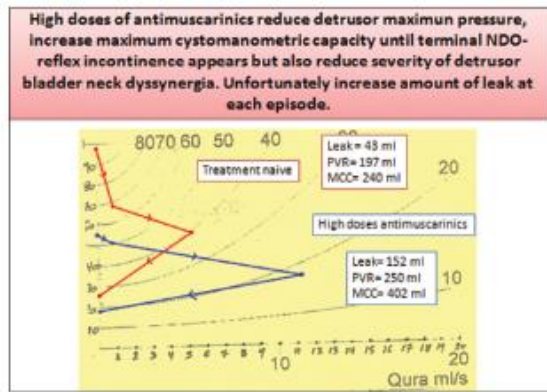


**Figure 11.** Interrupted flow pattern with continues flow time <20 sec. Incomplete bladder emptying


was found at 0%(0/2), 25%(3/12), 33.3%(2/6), 50%(2/4), 66.7%(6/9) of groups O, IA, IB, II, and III, respectively. During filling cystomanometry, “normal” bladder sensation was found at 100%(2/2), 50% (6/12), 20%(1/6), 0%(0/4), 0%(0/9), “reduced” at 0%(0/2), 41.7%(5/12), 66.7% (4/6), 25%(1/4), 0%(0/9) and “non-specific” at 0%(0/2), 8.3% (1/12) 16.7%(1/6), 75%(3/4) ,100%(9/9) of groups O, IA, IB, II and III, respectively. Mean values of urodynamic parameters during pressure – flow study (P-F) were the following: [Pdetmax: 96.5, 85.17, 94.43, 80.5, 56.1 cmH2O], [Pdetclos : 20.5, 26.8, 27.8, 18.5, 36.5 cmH2O], [BOOI : 43.5, 22.9, 40, 13.25, 40.9], [BCI :110, 87.4, 83.2, 83.25, 48.3] for groups O, IA, IB, II and III, respectively. Mean value of flow time (Tq) was 79, 15.54, 16.8 and 15.5 sec for group’s O, IA, IB and II respectively. Mean value of Pdetopen (after Pdetmax) was 60.6, 70.3, 47.8 cmH2O for group’s IA, IB and II, respectively, while mean DLPP (at or after Pdetmax) at group III was 43.5 cmH2O. Mean value of Pdetopen (prior to Pdetmax) was 64.5 cmH2O for group O. URA value above or equal to 29 was observed at 50%(1/2), 33.3%(4/12), 66.7%(4/6), 0%(0/4) και 88.9%(8/9) of groups O, IA, IB, II and III, respectively.




**Figure 12 A.** High doses of antimuscarinics reduce bladder outflow active resistance with observed reduction of Pdetopen, URA and Pdetclos



**Figure 12 B.** High doses of antimuscarinics reduce bladder outflow active resistance with observed reduction of Pdetopen, PdetQmax, URA and Pdetclos



**Figure 13.** Detrusor leak point pressure alterations after treatment with botulinum toxin instillation to detrusor



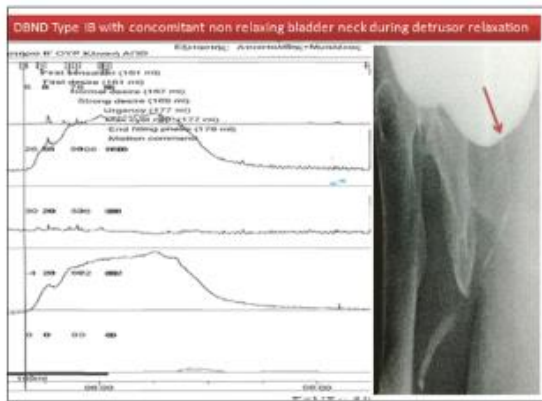
**Figure 14.** Isolated botulinum toxin instillation to external sphincter. Treatment failure due to DBND

## Discussion:


### Pathophysiology of DBND

Urinary flow during DBND is actually a passive flow. Maximum flow (Qmax) and flow time (Tq) are gradually reduced as the severity of DBND increased. Urinary flow begins during detrusor relaxation and not during the active detrusor contraction. Bladder neck active contraction is terminated when the detrusor muscle begins to relax. During detrusor contraction, if bladder sensation is adequately preserved, sensation of NDO push patients to try to urinate, but bladder neck is actively close and opens only when NDO is terminated. This maybe explains the “paradoxical” bladder neck closure during the attempt to void according to Andrade<sup>(8)</sup>. Urinary flow begins when the already established high intravesical pressure (from the simultaneous detrusor and bladder neck contraction) exceeds during detrusor relaxation the bladder neck active resistance (Pdetopen). Urinary flow (actually passive) is terminated when the intravesical pressure falls, due to both detrusor relaxation and passive urinary flow, below the baseline (rest) resistance of bladder neck (Pdetclos). Fading contraction (W80-W20 negative value) is the result of the passive flow and is more obvious at patients with increased Pdetclos. Pdetclos is increased according to the severity of suprasacral lesion. Reduced bladder voiding efficiency (BVE=V.V. /V.V.+PVR) is actually






**Figure 15.** Detrusor bladder neck dyssynergia with non relaxing bladder neck during detrusor's relaxation



**Figure 16** Concomitant DBND with non relaxing bladder neck during detrusor relaxation may be estimated by the latency time between Pdetmax and Pdetopen



**Figure 17.** Medical treatment, especially high doses of antimuscarinics and/ or botulinum toxin to the detrusor, may modify urodynamic observations

due to the passive nature of flow and not due to real detrusor underactivity (DU) <sup>(6), (8)</sup> (Fig 1,2). In those patients any leak or urination actually represent urge incontinence (NDO with sensation) or reflex incontinence (NDO without or with non-specific sensation) during bladder filling. Voluntary voiding phase of micturition is totally absent even if patients with sensation of NDO deny to accept it since they want to have free urination. These patients are actually trying to empty the bladder with

abdominal straining during NDO or even with repeatedly provoke NDO. High doses of antimuscarinics or botulinum toxin to detrusor muscle, unmask the really absent voluntary voiding phase of micturition, resulting detrusor acontractility (DA) and urinary retention. Neurogenic detrusor bladder neck dysfunction due to upper motor neuron lesion type S2-S4 can be classified as following (fig 3):

### Type O

Patients with mild spastic paraparesis without or with mild (unobservable) motility impairment, with n-OABdry symptoms (frequency, nocturia, urgency) and difficult voiding. Episodes of urge urinary incontinence may occasionally appear when immediate access to toilet is impossible. Urinary flow is continues with delayed time to maximum flow ( $T_{qmax} > 1/3 T_q$ ). Basic neurological examination is almost normal without or with unilateral mild perineal sensation impairment. **Phasic NDO was observed only in those patients.** During pressure flow study there was obstructing voiding pattern, with high pressure ( $>40 \text{ cm H}_2\text{O}$ )

Pdetopen prior to Pdetmax. A - blockers is the initial treatment of choice. Bladder sensation is normal. Isolated non relaxing or delayed relaxing bladder neck, without concomitant DBND, it is the mildest form of upper motor neuron detrusor bladder neck dysfunction (Fig.4,5).

### **Type IA.**

Patients with moderate motility impairment (observable) and n-OABwet symptoms. They report difficult voiding together with abdominal straining. Present bulbocavernosum reflex (BCR) is accompanied by severely impaired (absent) voluntary control of anal sphincter (VCAS) and at least unilateral mild reduced PS. Intermittent urinary flow with pathologic post void residual (PVR) is generally the rule. Continuous flow during free urination is almost never above 20 sec. During P-F study, Pdetopen is following Pdetmax and urinary flow is accompanied by abdominal straining due to patient sensation of NDO. Treatment of choice is antimuscarinics at low dose in order to improve, not only NDO and storage symptoms, but also to reduce DBND. High doses of antimuscarinics may unmask the reflex nature of voiding and may result urinary retention (real DA) with patient's dissatisfaction. A- blockers may also improve voiding symptoms by reducing further the bladder neck outlet resistance. Monotherapy with a-blockers, frequently dissatisfy patients with high expectations. In fact, a - blockers alone does not have any impact at NDO and does not effectively reduce active bladder neck contracture during NDO. In cases of excessive PVR after combination therapy, a limited number of clean intermittent catheterizations (CIC X 1-2), may further improve urinary symptoms but may increase the possibility of febrile urinary tract infections (Fig.6,7 )

### **Type IB**

Patients with moderate or severe motility impairment and n-OABwet symptoms. They may refer free urination. Incontinence and frequently enuresis without nocturia is the consequence of a more serious bladder hyposensitivity. PS is moderate to severely impaired. During P-F study, Pdetopen is following Pdetmax as at patients with DBND type IA, but there is no abdominal straining due to bladder hyposensitivity. If there is any free urination, maximum flow and bladder voiding efficiency is relatively decreased compared to patients with DBND Type IA. High doses of antimuscarinics with CIC is the initial treatment of choice. (Fig.6,8)

### **Type II**

Wheelchair patients with high velocity, high pressure NDO (>40 cmH<sub>2</sub>O) and Pdetopen after Pdetmax. Severe perineal sensation impairment is accompanied with severe bladder hyposensitivity and absence of free urination. (Fig.9)

### **Type III**

Wheelchair patients, with excessive spastic lower limbs, with no sensation of urinary incontinence and daily enuresis without nocturia. Severe bilateral impairment or totally absent PS is accompanied with totally absent or non specific bladder sensation. Active reduced compliance is the rule with high detrusor leak point pressure (DLPP > 40 cm H<sub>2</sub>O), frequently after Pdetmax. High doses of antimuscarinics with CIC are the initial treatment of choice. This is the worst form of upper motor neuron detrusor bladder neck dysfunction, with DBND and non relaxing bladder neck during detrusor relaxation. Those patients are in increased risk for upper urinary tract deterioration.(Fig. 10)

### **The significance of basic neurological examination**

The presence of bulbocavernosum reflex (BCR) reflects a normal sensory input and motor output of S2-S4 parasympathetic micturition center. Reduced perineal sensation (PS) after painful perineal puncture in those patients reflects a suprasacral sensory input lesion. Totally absent PS reflects more advanced suprasacral lesion than unilateral reduced or bilateral mild to moderate impaired PS. Absence of voluntary control of anal sphincter (voluntary contraction and relaxation of anal sphincter, VCAS) with normal or increased BCR also reflects suprasacral lesion. Anal tone (AT) is severely reduced only in severely impaired S2-S4 motor output (denervation pattern of motor unit potentials S2-S4 during invasive periurethral cn-EMG) <sup>(9)</sup>. As a consequence, at neurogenic patients with history of suprasacral lesion, increased or present the BCR, absent the VCAS, increased or normal AT, and impaired PS we can predict, with high accuracy, the presence of NDO and UUI or reflex incontinence, even without urodynamic study<sup>(10)</sup>.

### **Recurrent urinary tract infection (UTI)**

According to our retrospective study, febrile UTIs were frequent at patients with DBND and “irresistible desire to have free urination” and avoidance of CIC. Intravesical pressure was extremely high on those patients as a consequence of both high pressure NDO and strong abdominal straining. Their wiliness to have free urination pushed them to urinate with excessive abdominal straining. They were trying to compensate the functional obstruction with abdominal straining (Fig. 7). Sensation of NDO does not help them to realize that their voiding is actually reflex in nature and they refuse treatment with antimuscarinics and CIC. Five patients with DBND Type I, recurrent febrile urinary tract infections and initial irresistible desire to have free urination were asked for bladder neck incision (BNI) but they were also informed about the possibility of UUI worsening after the procedure. None of them accept BNI. Two of them gradually accepted the combination of high doses antimuscarinics and intermittent catheterization and abandoned free urination. Febrile UTIs was cured after that maneuver. Asymptomatic bacteriouria was persisting due to CIC but without febrile symptomatic infection.(fig.7)

## **Uroflow parameters**

Interrupted voiding pattern can be attributed to the repeated passive flows (usually shorter than 20 sec) during reflex repeated NDO or to patient ability to provoke NDO with simultaneous abdominal straining or by other ways (stimulation of genital organs). Pathologic bladder voiding efficiency (BVE) can be explained by the passive nature of flow, detrusor's exhaustion after repeated provocation of NDO and impaired bladder sensation (termination of abdominal straining when the patient falsely feels empty his bladder). (fig. 11)

## **Reduction of Detrusor Leak Point Pressure (DLPP) after treatment with high doses of antimuscarinics and botulinum toxin instillation to detrusor.**

High doses of antimuscarinics (fig 12) or botulinum toxin to detrusor may not only increase the maximum cystomanometric capacity (MCC) and may not only improve the active reduced compliance but may also reduce the active component of bladder outflow resistance at patients with DBND (fig 13). DLPP after instillation of 300 IU of botox in three patients with DBND Type III, was almost at the same level of Pdetclos before botox . DLPP was lower than Pdetclos in one patient with concomitant instillation of 20IU of botulinum toxin to the bladder neck. The possible pathophysiologic mechanism of this urodynamic observation is that antimuscarinics and/or botox to detrusor, not only reduce the severity of neurogenic detrusor overactivity (amplitude and bladder volume at appearance) but also reduce the severity of sphincters overactivity. We can therefore assume, that both antimuscarinics and botulinum toxin to detrusor acts at least partially, as an iatrogenic down regulator of the excessive stimulated guarding reflexes. We may also hypothesize that **they act as a down regulator of the bladder "decompression valve" (sphincters overactivity)**, protecting by that way the upper urinary tract system from high intravesical pressures, although patients will not achieve voluntary control of urination for sure and –unfortunately– may not become, totally dry. In the majority of the cases, without upper urinary tract complications, instillation of 200 IU instead of 300 IU botulinum toxin to detrusor theoretically produce a moderate instead of a severe reduce of DLPP in an acceptable way to control reflex incontinence between CIC. On the contrary, on patients with DBND Type III (active reduce compliance with non relaxing bladder neck during detrusor's relaxation), with concomitant upper urinary tract impairment, 300 IU may be of benefit by reducing even more the DLPP, although episodes of incontinence may be more frequently observed, due to the maximum down regulation of sphincters overactivity. Additionally, based on pathophysiological evidences, it seems that patients with DBND have no indication for isolated botulinum toxin instillation to external sphincter (fig 14).

## **Urodynamic parameters and DBND Type I-III**

Detrusor's insufficiency probably should not be diagnosed based to bladder contractility index ( $BCI = P_{det}Q_{max} + 5Q_{max}$ ) and W80-W20 negative value, due to the passive nature of flow, even at patients with ability to void.  $P_{detopen}$  after  $P_{detmax}$ , BOOI value  $\geq 40$  and URA value  $\geq 29$  together with a high value of  $P_{detclos}$  are diagnostic of detrusor – active bladder neck dyssynergia with concomitant non relaxing bladder neck during detrusor relaxation in the absence of benign prostatic enlargement (fig.15). Severity of concomitant non relaxing bladder neck during detrusor relaxation can be evaluated by the latency time between  $P_{detmax}$  and  $P_{detopen}$  (fig 16). It should be noted that, at patients with DBND Type IA, with concomitant excessive abdominal straining, URA, BOOI,  $P_{detmax}$ ,  $P_{detopen}$ ,  $P_{detclos}$ , should be used with caution during urodynamic diagnosis. Excessive abdominal pressure contributes equally or even greater than detrusor pressure during urinary flow (Fig.7).

## **Conclusions:**

Despite the limited number of male patients, the current proposed novel classification possibly reflects five progressive severity degrees of the same pathophysiologic identity, neurogenic DO with progressively increased degree of detrusor bladder neck dysfunction. Patient's motility, spasticity of lower limbs, perineal sensation, bladder sensation, ability to void and severity of neurogenic bladder neck dysfunction, are all progressively worsening from type 0 to type III. It should be noted that this classification is easier at treatment naïve patients because antimuscarinics and botulinum toxin may modify urodynamic observations (fig13, 17).

The above study was awarded with the best poster session article commendation by the Hellenic Urologic Association, at the 21th Panhellenic Congress.

## **Περίληψη**

**Σκοπός:** Ουροδυναμική ταξινόμηση της νευρογενούς δυσσυνέργειας εξωστήρα κυστικού αυχένα (DBND).

**Υλικό - Μέθοδος:** Αναδρομικά, 33 άντρες με επιβεβαιωμένη (MRI σπονδυλικής στήλης) υπερειρή υπογεφυρική βλάβη του νωτιαίου μυελού ταξινομήθηκαν με βάση τις ουροδυναμικές παρατηρήσεις στην ομάδα O [ $P_{detopen} (\geq 40 \text{ cm H}_2\text{O})$  πριν την  $P_{detmax}$ ,  $Tq_{max} > 1/3 Tq$  στην ελεύθερη ουροροομετρία και ατελής ή καθυστερημένη διάνοιξη του κυστικού αυχένα στην κυστεοουρηθρογραφία κατά την ούρηση], την ομάδα IA [αυξημένο  $T_{open}$ , μεγάλου εύρους τελική νευρογενή υπερλειτουργία του εξωστήρα (TNDO) και κοιλιακή συμμετοχή στην ούρηση], την ομάδα IB [αυξημένο  $T_{open}$ , μεγάλου εύρους τελική νευρογενής υπερλειτουργία του εξωστήρα (TNDO) δίχως κοιλιακή συμμετοχή στην

ούρηση], την ομάδα II (υψηλών πιέσεων και σύντομης διάρκειας TNDO) και την ομάδα III (δυναμική ελαττωμένη ευενδοτότητα με πίεση διαφυγής εξωστήρα (DLPP) υψηλών πιέσεων κατά ή μετά την Pdetmax.

**Αποτελέσματα:** Ελεύθερη ούρηση παρουσίασε το 100% (2/2), 83.3% (10/12) και 33.3% (2/6) των ομάδων O, IA και IB, αντίστοιχα. Η μέση μέγιστη ροή των ούρων στην ελεύθερη ουροροομετρία υπολογίστηκε στο 17.4, 12.4 and 4.1 ml/sec, αντίστοιχα. Διακοπτόμενη ούρηση σε ποσοστό μεγαλύτερο του 50% των καταγεγραμμένων ουρήσεων ανά ασθενή, παρατηρήθηκε στο 0% (0/2), 100% (10/10) και 100% (2/2), αντίστοιχα. Σπαστική παραπληγία παρατηρήθηκε στο 0%(0/2), 8.3%(1/12), 83.3%(5/6), 100%(4/4) και 100%(9/9), αμφοτερόπλευρα φυσιολογική αισθητικότητα περιπρωκτικά (PS) καταγράφηκε στο 50%(1/2), 25%(3/12), 16.7%(1/6), 0%(0/4), 0%(0/9) ενώ φυσιολογική αισθητικότητα της κύστεως διαπιστώθηκε στο 100% (2/2), 50% (6/12), 20% (1/6), 0% (0/4), 0% (0/10) των ομάδων O, IA, IB, II και III, αντίστοιχα.

### Λέξεις ευρετηριασμού

Ουροδυναμική ταξινόμηση της νευρογενούς δυσσυνέργειας εξωστήρα κυστικού αυχένα (DBND)

### References:

- 1) Yamanishi T, Yasuda K, Sakakibara R, Hattori T, Tojo M, Ito H. J The nature of detrusor bladder neck dyssynergia in non-neurogenic bladder dysfunction. *Auton Nerv Syst.* 1997 Oct 13;66(3):163-8.
- 2) Schurch B, Yasuda K, Rossier AB. Detrusor bladder neck dyssynergia revisited *J Urol.* 1994 Dec;152(6 Pt 1):2066-70.
- 3) EAU Guidelines 2011. Guidelines on neurogenic lower urinary tract dysfunction. p16
- 4) De EJ, Patel CY, Tharian B, Westney OL, Graves DE, Hairston JC. Diagnostic discordance of electromyography (EMG) versus voiding cystourethrogram (VCUG) for detrusor-external sphincter dyssynergy (DESD). *Neurourol.Urodyn.* 2005;24(7):616-21.
- 5) Thorup Andersen J, Jacobsen O, Gammelgaard PA, Hald T. Dysfunction of the bladder neck: a urodynamic study. *Urol Int.* 1976; 31(1-2):78-86.
- 6) Salinas J, Pelaquin H, Prieto S, Dambros M, Viudez, I, Virseda M, Silmi A. Changes in detrusor contractility in bladder hyperreflexia . *Arch Esp Urol* 2008,Jun,01;61(5):603-10;
- 7) Mytilekas KV, Kalaitzi M, Ioannidis E, Apostolidis A. Urodynamic criteria for diagnosing detrusor bladder neck dyssynergia. e- Poster section 8<sup>th</sup> Macedonian Urologic Symposium, 3-5/11/2011 Thessaloniki, Greece.
- 8) Andrade MJ. Lower urinary tract dysfunction in familial amyloidotic polyneuropathy, Portuguese type. *Neurourol Urodyn.* 2009; 28(1):26-32

- 9) Mytilekas KV, Salinas JC Urodynamic evaluation of men with neurogenic bladder dysfunction after vertebral column surgery. Best article at the Poster Section of the 20th Panhellenic Urological Congress 23-27/10/2010 Lemesos, Cyprus.
- 10) K.V. Mytilekas, M. Kalaitzi, E. Ioannidis, A. Apostolidis. Acquired spinal cord pathology. Prospective correlation between basic neurological examination and urodynamic observations. Preliminary results. Hellenic Urology 2013, 25: 201-212

# Successful restoration of deep open rupturing penile trauma from cutting instrument with complete urethral dissection without microsurgical technique.

Christos D. Kyratsas, Christos G. Papachristou, Konstantinos E. Livadas

2<sup>nd</sup> Department of Urology, Medical School of Athens, "Sismanogleion" General Hospital of Athens.

**Corresponding author:**

Christos D. Kyratsas, E - mail: christok@hol.gr

## Summary

Penile trauma presents a challenge for the urologist, since correct and prompt surgical treatment can guarantee the successful outcome of the reconstruction. We present the case of a young man with a deep trauma of the ventral aspect of the penile shaft involving the urethra, as a result of a failed attempt of amputation by another person, who was managed with urgent surgical reconstruction without microsurgical techniques and had a perfect aesthetic and functional outcome. Although microsurgical correction is considered the treatment of choice for such injuries, in centers with no such facilities and in selected cases classic surgical techniques offer an excellent alternative.

## Keywords:

**penile trauma, urethral injury, plastic reconstruction**

## Introduction

Penile trauma commonly occurs from all-causes accidents. Other cases include iatrogenic penile traumas during circumcision surgery procedure (especially in countries where they are performed for religious reasons) and intentional self-harm of psychotic patients. Criminal acts, committed by third parties, are also reported as in our case **(1), (2), (3), (4)**.

Penile traumas, though relatively rarely encountered in daily urological practice, require immediate assessment of the trauma extent, in order to select the applicable



correction procedure, for an aesthetically and functionally restoration of the phallus and in many cases of the urethra.

TABLE 1	
<i>Classification of penile traumas</i>	
Grade*	Trauma description
I	Cutaneous laceration/contusion
II	Buck's fascia (cavernosum) laceration, without tissue loss
III	Cutaneous avulsion/laceration. Rupture of the balanus or the outer urethral orifice. Cavernosal or urethral defect <2 cm.
IV	Partial penectomy. Cavernosal or urethral defect ≥2 cm.
V	Total penectomy

\* Advance one grade for multiple lesions up to grade (source: *The American Association for the Surgery of Trauma*)

Penile dissections are classified into total and partial, in case they regard only a part of the organ. In the latter, the affected aspect of the penis (ventral or dorsal) and the extent of the trauma, significantly contribute in deciding upon the applicable treatment. The reason is that, depending on the trauma surface and apart from the imperative suturing of the corpora cavernosa, either the neurovascular bundle or the urethra may also require correction.

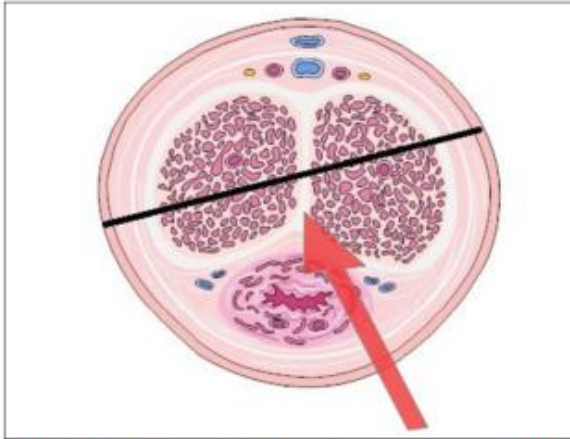
### Case description

We hereby present a case of a 34-year-old male who was admitted to the our hospital's Emergency Department with a deep open rupturing penile trauma from cutting instrument, following the attempt of his ex-wife to amputate his penis.

Upon arrival at the hospital, the patient was pale and in a state of shock; blood pressure 120/80 mm Hg, 110 beats per minute (BPM) and his wound was packed with gauzes. Unpacking the wound, we identified a particularly deep trauma located on the ventral aspect and in the midway of the penile shaft, vertically oriented to the longitudinal axis of the phallus. The trauma edges were sharp, without any cutaneous lesions. The patient had mild haemorrhage and thusly we proceeded with intermittent constriction at the base of the penis prior to anaesthesia administration. Blood tests revealed mild leukocytosis [14000 polymorphonuclear leukocytes (PMN)], haemoglobin 13.9g/dl and haematocrit (HCT) 40.7%.

The patient was immediately taken to the operation room (OR), where we established total dissection of the anterior urethra, dissection of the left corpus cavernosum by 2/3 of its thickness and of the right corpus cavernosum by 1/3 of its thickness (**Fig. 1**). After the application of a tourniquet at the base of the penis, we expanded the existing incision by 1cm longitudinally on the ventral aspect, directed towards the balanus.

Subsequent to the preparation of the corpora cavernosa, we restored their continuity by suturing their tunicae albugineae with isolated Vicryl 2-0 sutures. Next, we performed an end-to-end urethral anastomosis with isolated absorbable Vicryl 5-0 sutures above an 18-Fr Foley urinary catheter. We then proceeded with suturing the Buck fascia and the skin. The



**Figure 1:** Schematic illustration of trauma (transverse - section). The black line represents the margin of the open rupturing trauma which included the whole corpus spongiosum and parts of corpora cavernosa bilaterally. The arrow shows the direction of the trauma



**Figure 2:** Picture of the trauma five weeks after surgical correction. The aesthetically excellent healing of the ventral aspect of the penis is clearly distinct

trauma was classified as 4<sup>th</sup> grade, according to the scoring scale of the American Association for the Surgery of Trauma (**Table 1**). The patient was post-operatively administered with antibiotics (cefoxitin and netilmicin), he exhibited stable post-operative progress and was discharged with an 18-Fr urinary catheter 5 days after his admission.

Three weeks later, the surgical site was excellently healed and the urinary catheter was removed. The patient urinated with ease and the uroflow examination showed a normal plateau-free urine flow curve,  $Q_{max}=32.5$  ml/sec and no post void residual (PVR). Two weeks after the first post-operative follow up, the patient reported easy urination and normal erections while the aesthetic result of the surgical restoration of his penis was remarkable (**Fig. 2**). He was subjected to uroflowmetry anew, the results of which were within normal ranges ( $Q_{max}=33$  ml/sec). Unfortunately, the patient missed his scheduled follow up and thusly no new information exists on his further progress.

## Discussion

Early surgical management of penile traumas and the surgeon's experience constitute important factors upon which successful restoration depends. The result of the reported case demonstrates that surgical restoration of a deep trauma on the ventral aspect of the penis from cutting instrument is treatable without microsurgery techniques and the outcomes can be aesthetically and functionally outstanding both for erection and urination.

Haemorrhage, which accompanies corpora cavernosa dissection, is the main reason for emergency operations and while haemodynamic stability should be the primary concern, it should not delay the decision process upon the applicable surgical procedure or the procedure itself. In any case, whatever the applicable technique, the urologist has to bear two significant parameters in mind: the functional restoration of the organ and the aesthetic outcome (2),(5),(6).

The first recorded case of amputated penis replantation traces back in 1929 by Enrich. In 1968, McRoberts described some cases managed with conventional approaches, without microsurgery techniques, which involved the correction of the urethral continuation and the corpora cavernosa; the potential to suture the dorsal vein of the penis and the need to depress the organ into the scrotum in severe skin lesion cases are reported as well (1),(3),(4). In a large series of patients in Thailand, many patients were also managed without microsurgery and exhibited good results (2).

The first microsurgery restoration cases were documented in 1977. Currently, microsurgery, is considered the most advisable treatment method of such traumas (1),(2),(3),(6). However, in certain cases, non-microsurgery management can deliver comparable outcomes (2),(4).

Studies revealed that the restoration of the organ's haematosi s following a macroscopic replantation is performed via the spongy tissue of the corpora cavernosa, albeit, in our case, the dorsal artery and vein remained intact and consequently the restoration of haematosi s and the -equally important- venous return, were not particularly challenging postoperatively (3),(7). Even in cases of microsurgical replantation, the restoration of the cavernous arteries' continuity is not advised due to its technical difficulty, especially if the trauma is peripheral. Moreover, it still remains to be established whether the end-to-end anastomosis significantly contributes to the restoration of haematosi s. On the contrary, when the dorsal artery is dissected, the effort to restore its continuity is recommended (1), (2), (4). In addition, microsurgical management is neither advocated as imperative for the preservation of the phallic sensitivity and the erectile function nor does it guarantee it (5), (6). It is noteworthy that desirable functional outcomes after restoration without microsurgery technique have been reported even on neonates (7).

With regard to urethral restoration, it is of great significance to early identify the trauma type and the assault instrument, where applicable (6),(7). In the present case study, the dissection of the urethra was particularly sharp, vertically oriented to its longitudinal axis, facilitating the end-to-end anastomosis. During surgery, the need for the mobilization of the urethra to a certain extent to accommodate suturing may arise. Nevertheless, the preparation needs not to be extensive; while the anastomosis can be sutured in a tension-free fashion since the rich haematosi s of the corpus spongiosum favors the accurate healing of such traumas. Careful suturing of the corpus spongiosum and overlying skin is very important in the prevention of fistula development (8).

The main immediate postoperative complications a surgeon should consider include trauma infection and cutaneous necrosis. To avoid such conditions, meticulous irrigation of the affected area during surgery, debridement of the trauma edges and perioperative antibiotic coverage are essential (3),(4),(5),(6).

To conclude, the early and anatomically correct restoration of deep open rupturing penile traumas constitutes the 'corner-stone' in their management. Delaying the surgical procedure, in case no microsurgery means are available to treat the case, may not result to the patient's benefit given that, in certain cases, classic surgical techniques may deliver comparable results. Certain trauma localization as well as dorsal artery or neurovascular bundles dissection necessitate the use of microsurgical techniques.

## Περίληψη

Οι τραυματικές κακώσεις του πέους αποτελούν πρόκληση για τον ουρολόγο καθώς η σωστή και έγκαιρη αντιμετώπισή τους διασφαλίζει την αποκατάσταση του οργάνου. Παρουσιάζουμε την περίπτωση νέου άνδρα ο οποίος, μετά από απόπειρα ακρωτηριασμού από έτερο άτομο, προσήλθε με τραύμα της κοιλιακής επιφάνειας του πέους που συμπεριλάμβανε και την ουρήθρα, το οποίο αντιμετωπίστηκε με επείγουσα χειρουργική αποκατάσταση χωρίς μικροχειρουργική τεχνική, με άριστο αισθητικό και λειτουργικό αποτέλεσμα. Αν και η μικροχειρουργική αποκατάσταση θεωρείται η αντιμετώπιση εκλογής σε τέτοιους τραυματισμούς, σε κέντρα όπου δεν υπάρχει τέτοια δυνατότητα και σε επιλεγμένες περιπτώσεις οι κλασικές χειρουργικές τεχνικές αποτελούν μία άριστη εναλλακτική μορφή αντιμετώπισης.

## Λέξεις ευρετηριασμού:

**τραύμα πέους, κάκωση ουρήθρας, πλαστική αποκατάσταση**

## References

1. Jordan G.H. Management of Penile Amputation. In: Hohenfellner M, Santucci RA (eds) Emergencies in Urology, Springer-Verlag Berlin Heidelberg, 2007, 270-5
2. Jezior JR, Brady JD, Schlossberg SM. Management of penile amputation injuries. World J Surg. 2001, 25(12):1602-9.
3. Babaei AR, Safarinejad RM. Penile replantation, science or myth? A systematic review. Urol J. 2007, 4(2): 62-5
4. Kochakarn W. Traumatic amputation of the penis. Braz J Urol. 2000, 26: 385-9
5. Lowe MA, Chapman W, Berger RE. Repair of a traumatically amputated penis with return of erectile function. J Urol. 1991, 145(6): 1267-70.

6. Li GZ, He F, Huang GL, Man LB, Liu K, Shen YM. Penile replantation: report of two cases and review of the literature, *Chin J Traumatol*. 2013, 6(1): 54-7
7. Haldar P, Mukherjee PP, Ghosh TJ, Shukla RM, Mukhopadhyay B. Animal bite of penis in a neonate and macroscopic repair. *J Indian Assoc Pediatr Surg*. 2011, 16(4): 163–4.
8. Chapple CR, Png D. Contemporary management of urethral trauma and the post-traumatic stricture. *Curr Opin Urol*. 1999, 9(3):253-60.

# Surgical Complete Androgen Blockade (SCAB) in the prostate cancer: A treatment from the past with future perspectives

Christos Char. Sidiropoulos

Urological Surgeon

**Abstract:** The dependence of prostatic cell from androgens is widely known. Until recently, the dominant belief was that the complete androgen blockade of the cancerous prostatic cell was successfully achieved by drugs and for that reason, the unresponsive to hormone treatment disease was characterized as “hormone refractory prostate cancer” or “hormone resistant”. However, over the last years, modern endocrine, biology and pharmacology, through clinical trials, concluded that pharmaceutical androgen blockade is not as complete as we considered it to be. As result of this conclusion, the modern term is “*castration resistant prostate cancer*” (CRPC) in contradistinction with “*hormone refractory prostate cancer*”. The present paper analyses and explains the steroidogenesis cascade of androgens and their interaction pathways with the prostatic cell. Likewise, the basic pharmaceutical hormone manipulations in metastatic prostate cancer are mentioned and the causes of their deficiency in achieving complete androgen blockade are explained. Also, Surgical Complete Androgen Blockade (SCAB) is analysed in detail and a modern application of this alternative therapy is proposed. Furthermore, based on statistics, the advantages regarding the estimated cost of the SCAB are elaborated as opposed to the pharmaceutical cost in Greece. In addition, powered by facts from the past and the present, a safe trial of SCAB is proposed on selective patients in terms of a modern investigational protocol.

## Key words:

prostate cancer, hormone therapy, androgen blockade, bilateral adrenalectomy, androgen receptors.

## Introduction

In Europe, prostate cancer is the most common type of solid neoplasm with an incidence of 214 cases per 1000 males<sup>1</sup>. It also constitutes the 2<sup>nd</sup> most common cause of death (COD)

from cancer in males<sup>2</sup>. The close relation of the prostate gland with the testicular function was perceived at the end of the 19<sup>th</sup> century by J.W. White who, in 1893 in Philadelphia, suggested the orchiectomy in men with prostatic hyperplasia<sup>3</sup>. In 1941, C. Huggins established the major dependence of the prostatic cell from androgens and made the following statement: *"It is now perceived that racial hormones affect certain types of cancers. The impact may be manifested either as acceleration or retardation of their progress. So, the androgens seem to accelerate the progress of prostate cancer and the oestrogens retard it"*. (C. Huggins, 1941)<sup>4</sup>. To the present day, endocrine has, to a certain degree, elucidated the way in which the androgens interact with the prostatic cell. It seems that the blockade of androgen production and their interference with the androgen receptors (ARs) of the prostatic cell are the primary factors in the prostate cancer's hormonal control.

### **The role of the Androgen Receptors (ARs)**

ARs are localized inside the prostatic cell's cytoplasm, bound to heat shock proteins (HSPs) unable to bind to DNA. They are activated after binding androgens and translocate to the nucleus of the prostatic cell inducing DNA transcription and replication, RNA action with gene transcription and eventually cell proliferation<sup>5</sup>. Hormonal manipulations aim to block these effects of the ARs and subsequently inhibit uncontrolled proliferation of the prostatic cells. The main way to achieve it is the blockade of the ARs from the androgens activating them.

### **The steroidogenesis cascade of androgens**

Androgen production starts at the mitochondria of the Leydig cells of the testis and the endocrine cells of the adrenal cortex by converting acetic acid to cholesterol and then to pregnenolone by desmolase enzyme (C20-22 lyase). Pregnenolone is converted to progesterone and by 17-alpha-hydroxylase CYP17 to 17OH pregnenolone and then to dehydroepiandrosterone (DHEA). by the enzymatic activity of 17-alpha-hydroxylase, progesterone in the Leydig cell is converted into 17-OH progesterone and by C 17-20 lyase of the CYP17 to androstenedione (AED). DHEA also converts to androstenedione by 3BHS-1. However, in the adrenal endocrine cell, the progesterone can follow another metabolic pathway and convert to corticosterone (CORT) and eventually to aldosterone (Fig. 1)

DHEA is the first androgen formed in the chain of enzymatic reactions. It converts to AED and this in turn converts by 17-ketoreductase to testosterone (T). By 5-alpha reductase (5-AR), testosterone eventually transforms into the most active molecule, dihydrotestosterone (DHT). Androstenedione, testosterone and dihydrotestosterone are able to associate with ARs, activating them for prostatic cell proliferation. Moreover, a close relation of mutant AR types resulting in their activation by DHEA has been observed in vitro<sup>6,7</sup>.

## **The effect of modern drugs in androgen blockade**

In the treatment of metastatic prostate cancer, the urologist's primary goal is to stop the proliferation of the cancer prostatic cells. The main way to attain it is to deprive ARs from the androgens activating them. The urologist's armory in clinical practice includes:

Luteinizing hormone-releasing hormone (LHRH) analogs (busereline, gosereline, leuproreline, triptoreline): They induce pharmaceutical castration by acting as negative feedback to the hypothalamic-pituitary system and causing the reduction of LH secretion from the anterior lobe of the pituitary resulting in the abrogation of steroidogenesis in the Leydig cells.

LHRH antagonists (abarelix, degarelix): They directly bind and deactivate the LHRH receptors in the anterior lobe of the pituitary by blocking the LH secretion; the result is comparable to that of the LHRH analogs.

Antiandrogens (bicalutamide, flutamide, nilutamide, cyproterone acetate, megestrol acetate, enzalutamide, RD162): They act directly on ARs, obstructing their binding with the androgens that continue to synthesize in the adrenal cortex, given that LHRH analogs and LHRH antagonists target solely the testicular Leydig cells. The combination of antiandrogens and LHRH analogs or LHRH antagonists is called maximum or complete androgen blockade (CAB).

Oestrogens (Diethylstilboesterol-DES): They also lead to negative feedback to the pituitary and the outcome is respective to that of the LHRH analogs or LHRH antagonists but with increased risk of cardiovascular events.

Abiraterone: It binds with CYP17 and deactivates it. Its primary goal is to stop the androgen biosynthesis cascade after the pregnenolone and progesterone stage<sup>8,9</sup>. It acts both on the adrenal synthesis of androgens as well as on the Leydig cell.

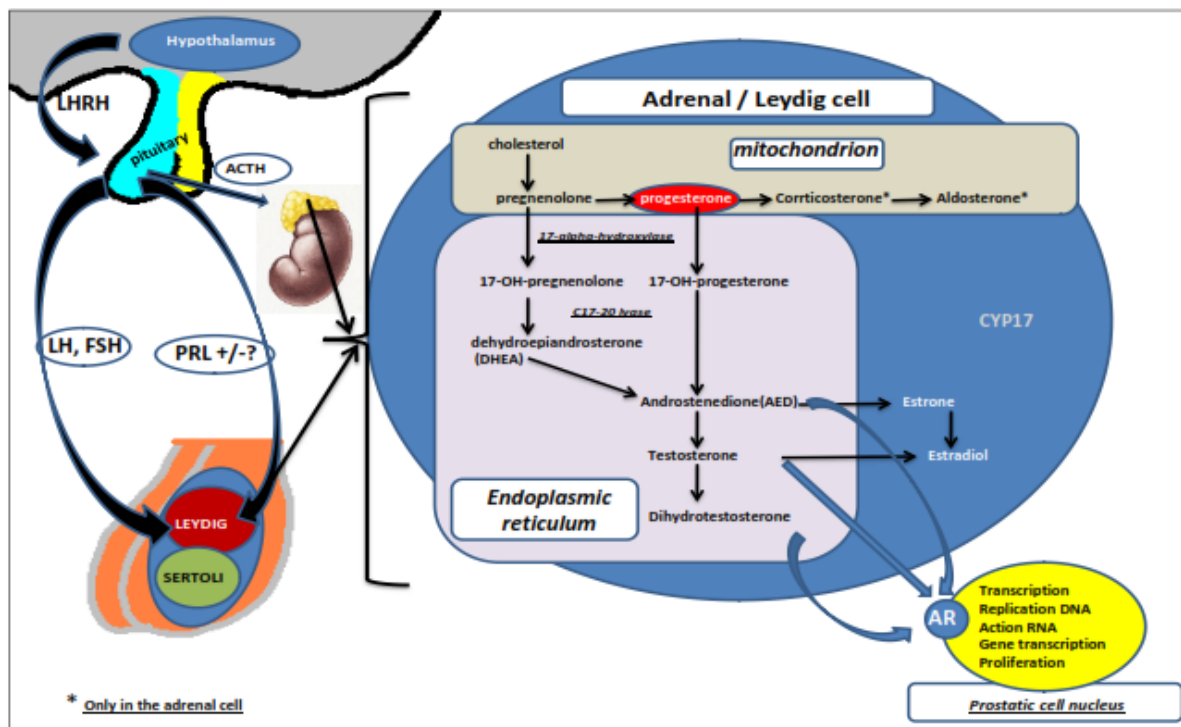
Ketoconazole: It is an antifungal agent that inhibits various enzymes of cytochrome P450, including CYP17. Its action is analogous to abiraterone but with less specificity and weaker affinity to CYP17 and thusly, reduced effects compared to abiraterone<sup>10</sup>.

## **Reasons behind medication insufficiency in managing SCAB**

The discovery of CYP17 inhibitors action such as abiraterone, pregnane and androstane<sup>11</sup> caused the term of the formerly known as "*hormone refractory prostate cancer*" to change into "*castration resistant prostate cancer*" (CRPC) given the establishment that despite its progress under castration, it continues to respond to hormonal manipulations for the reduction of androgens production. The above was confirmed by the clinical efficacy of abiraterone use which was documented by the increase of the overall survivorship (OS) in CRPC patients<sup>12</sup>. However, the disease progress, albeit the stopping of steroidogenesis, beyond the stage of pregnenolone and progesterone, means that there are other AR



activation pathways as well. It has been showed that certain AR mutations contribute to their inability to be deactivated by the antiandrogens and to be activated by progesterone and oestrogens or even by the antiandrogens themselves<sup>13,14,15</sup>. Also, in patients with castration levels of serum testosterone, androgens are detected within the prostatic cancer cells at a rate of 10-25% of the respective androgenic patients who receive no treatment. These androgen levels can activate the ARs and result to gene expression and cellular proliferation<sup>16</sup>. The androgens, including testosterone, derive from de novo synthesis from progesterone and the conversion of AED within the prostatic cell<sup>17</sup>. Androgens are also produced by progesterone in the Setoli cells of the testes<sup>18</sup>. It is thusly concluded that steroids comprising precursor molecules for the formation of androgens, act directly as androgens on the prostatic cancer cell. Progesterone is their primary representative.



*The steroidogenesis cascade of androgens and its hormonal regulation. Created & Designed by Christos Sidiropoulos*

Progesterone is a steroid which forms by pregnenolone in the mitochondrion of the Leydig cell and the adrenal cell. To up to date hormonal therapeutic manipulations do not affect the synthesis of this significant steroid which has the property of directly and indirectly enhancing the prostatic cell proliferation. Abiraterone, acting at a higher level compared to any other substance on the steroidogenesis cascade, acts against 17-alpha-hydroxylase and C17- 20 lyase – enzymes belonging to CYP17 of cytochrome P450 and are traced in the endoplasmic reticulum (ER). The result is that pregnenolone and progesterone synthesize in the mitochondria but are not affected by abiraterone. Modern endocrine has proven that

the so-called “*hormone refractory prostate cancer*” is initially castration-resistant and that the adrenal steroids continue to act upon the prostatic cancer cell. Surgical removal of the androgen production sources constitutes a way of complete deprivation of ARs from androgens. This is achieved by bilateral orchiectomy and synchronous bilateral adrenalectomy and is called SCAB.

### **SCAB: A safe and effective treatment**

Orchiectomy for castration purposes in managing the prostatic cancer cell has been known since the 18<sup>th</sup> century and is safely performed within a few minutes. Bilateral adrenalectomy in prostatic metastatic cancer was first carried out by the gifted Huggins, though the outcomes were disappointing due to acute adrenal deficiency; cortisone had not been discovered at the time<sup>19</sup>. But with the discovery and use of acid cortisone, the procedure came back to the fore and, in 1960, Mac Farlane et al. published his patients' OS, the maximum being 46 months<sup>20</sup>. Seven years prior to Mac Farlane, Taylor had announced that out of 6 patients with prostatic metastatic cancer, who were managed with adrenalectomy, 5 exhibited subjective improvement and 3 objective. In particular, lectual patients were able to mobilize shortly after the procedure. The objective improvement was recorded as reduction in acid phosphatase values, decrement of the prostate size which at the same time became flaccid, lower limbs detumescence, osteoblastic lesions reduction shown in radiologic studies and body weight increase<sup>21</sup>. In 1974, Bhanalph et al., also reported objective remission of osseous metastases and alcalic phosphatase levels subsequent to bilateral adrenalectomy in metastatic prostatic cancer<sup>22</sup>. Finally, the same year, Merrin published an article for a stage D patient manifesting metastases even on the perineal skin, who was tumor-free 4 years after the bilateral adrenalectomy<sup>23</sup>. Today, bilateral adrenalectomy can be performed laparoscopically; mean operative time 308 minutes (190-440 min), mean blood loss 138 ml (30-300ml). The access is transperitoneal in flank position and postoperatively, the patients are daily administered hydrocortisone and fludrocortisones as restoration treatment due to their adrenal deficiency<sup>24</sup>. Furthermore, a retrospective study of 30 patients who had undergone synchronous laparoscopic bilateral adrenalectomy with no intraoperative complications and mean postoperative hospitalization 3.5 days concluded that, combined with glucocorticoids and metalocorticoids administration, it constitutes a safe method as restoration treatment under endocrine monitoring<sup>25</sup>. The same conclusions were reached by Castillio after 22 synchronous laparoscopic adrenalectomies that he performed in less than 210 min; mean blood loss 63ml, mean hospitalization 3.2 days<sup>26</sup>. With regard to OS of patients who were subjected to bilateral adrenalectomy, most information comes from the past, when the procedure comprised the main treatment of the Cushing syndrome. In a retrospective study, from 1953 to 1980, it is reported that 79 patients who had undergone open bilateral adrenalectomy, their 20- and 5-year survivorship reached 62 and 79%, respectively<sup>27</sup>. The rates are

particularly encouraging if we consider the means of endocrine monitoring and infection management of the time. Also, in 1997, a published case report described the case of a patient who, having undergone synchronous bilateral adrenalectomy for the resection of adrenal metastases because of lung cancer, received cytotoxic therapy and was disease-free for more than 9 years<sup>28</sup>.

The involvement of adrenal androgens in the progress of prostate cancer was perceived a long time ago, but now the clinical importance of the deprivation of the prostatic cell from them has been also established. The main proof is the prolongation of OS by abiraterone, which inhibits the steroidogenesis cascade of the androgens. Yet, there are still no medication inhibiting the biosynthesis of all steroids inducing prostatic cells proliferation directly or indirectly. Such a precursor steroid is progesterone. Bilateral adrenalectomy and synchronous bilateral orchiectomy would instantly deprive the prostatic cancer cell from all the steroids with potent androgenic properties and would result in the stopping of the proliferation and eventually to apoptosis. Laparoscopic bilateral adrenalectomy is the procedure with few complications and less postoperative hospitalization. Furthermore, the simplicity of bilateral orchiectomy is established for many years now. The OS in patients who had undergone synchronous bilateral adrenalectomy was significantly long in older trials despite the absence of current endocrine knowledge and modern therapeutic substitutions. As for the adrenalectomy attempts in patients with metastatic prostate cancer, these were performed when neither CT and MRI scans and bone scintigraphy nor PSA test or the Gleason grading system were available. The patients managed with those pioneering procedures were of terminal stage and the only means available for diagnosis and surveillance of the disease were clinical examination, acid phosphatase and plain x-rays. Contemporary methods of early diagnosis and prostate cancer surveillance in combination with advanced surgical techniques, serve for new perspectives in the application of early SCAB. Also, the existing chemotherapy drugs (docetaxel, mitoxantrone, estramustine, cisplatin, carboplatin) are not ruled out from the treatment scheme. A strategic application of cytotoxic therapy could be its immediate administration secondary to the patient's full recovery. Thusly, the patient would receive the greatest reduction in cancer burden for healing purposes. Another strategic application of cytotoxic therapy could observe current data by applyign it when prostate cancer is hormone-resistant. Finally, this new cancer treatment version does not exclude supportive care with diphosphonic acids or radionuclides. Even the use of abiraterone as a second- or third-line drug, would possible have a point because it has been shown that even within the prostatic cancer cell, it is possible to have androgens synthesis from substances like cholesterol with CYP17 involvement<sup>17</sup>.

## **Cost-effectiveness of SCAB**

The lack of statistics on prostate cancer in our country is an obstacle in the accurate estimation of the economic benefit the application of the method would have. The only statistical information that exists is that in Greece, 2.412 men are diagnosed with prostate cancer annually. According to the American National Cancer Institute (NCI) Cancer Center Program (Surveillance, Epidemiology, and End Results (SEER) Program), in the 4% of newly diagnosed prostate cancer in white males, the disease is not local. If we apply this information to the disease incidence in our country, we will see that approximately 100 patients are candidates for hormonal therapy. From them, the highest rate will have 5-year survivorship since the rates for N+ and M+ disease are 100% and 27%, respectively (SEER) with M+ falling short of the N+ disease at the time of the diagnosis. The annual CAB cost can be easily estimated by summing up the annual cost of daily bicalutamide intake (50 mg/per day X 45 euros X 12 months = 540 euro) and the annual cost of the LHRH analog. For example, Triptorelline/11,25mg, is administered every trimester and costs 247 euro X 4 trimesters = 988 euro per year. So, the annual CAB cost amounts to approximately 1.529 euro. The respective amount for a 5-year period is estimated at 7.640 euros per patient. Therefore, for the 100 new patients per annum the cost is 764.000 euro. According to the Diagnosis-related groups (DRGs) of the Greek Ministry of Health and Social Solidarity, the adrenalectomy costs 3.000 euro and the orchiectomy 300 euro. It is understood that the respective cost of a 5-year treatment plan with SCAB for 100 new patients amounts to 330.000, i.e. 2.3 times smaller compared to pharmaceutical CAB. The cost-effectiveness is even greater if we also consider the number of patients who are not included in any statistics and those who proceed with cytotoxic or abiraterone therapy, the cost of each amounts to 3.500 euro per month per patient. As for enzalutamide, a new molecule with antiandrogenic effect (acts against ARs) is still under investigation and costs approximately 150 euro/10mg; the daily dose used in clinical trials ranges between 30mg to 240mg, i.e. 450 to 1.000 euro per day. Accordingly, the monthly enzalutamide treatment is estimate at 13.500 to 30.000 euro per patient. Outpatient follow ups, laboratory surveillance cost and therapy-induced complication treatment costs were not included in the above estimations.

## **Conclusions**

SCAB within the framework of a modern research protocol would offer valuable information for the actual impact of the androgens in the progress of the disease. Also, in case of successful outcomes, it would constitute an economic approach in the effective treatment of metastatic patients, given the cost, apart from the procedure, is limited only to glucocorticoids and metalocorticoids intake which are of very low cost and the follow up which is burdened by the endocrine monitoring.

The modern trend of replacing the term “*hormone refractory prostate cancer*” with “*castration resistant prostate cancer*” (CRPC) is a consequence of the establishment that the prostatic cell should be 100% free from androgens before we use the term hormone-resistance. Current therapy seems inadequate to achieve this goal. SCAB is possibly the most effective and simultaneously the most economic method for maximum deprivation of the prostatic cancer cell from androgens and steroids with mitotic effect on it. With respect to the conditions under which it was tested in the past, the result at that time and the contemporary progress in surgical techniques, endocrine, pharmaceutical and laboratory support and the advancements in diagnosis and monitoring of prostate cancer from the modern urologist, we conclude that today, in terms of a research protocol, it could constitute a safe intervention with maximum oncologic benefit in certain patients.

## References

1. Grossfeld GD et al. Use of second treatment following definitive local therapy for prostate cancer: data from the CaPSURE database. *J Urol* 1998,160(4):1398-1404.
2. Lu-Yao GL et al. Follow-up prostate cancer treatments after radical prostatectomy: a population-based study. *J Natl Cancer Inst* 1996,88(3-4):166-73.
3. White J. W. The present position of the surgery of the hypertrophied prostate. *Ann. Surg.*1983,18: 152-188.
4. Huggins, C., and Hodges, C. V. Studies on prostatic cancer. 1. The effect of castration, of oestrogen and of androgen injections on serum phosphatases in metastatic carcinoma of the prostate. *Cancer Res.*1941,1: 293-7.
5. Chen Y, Sawers CL, Scher HI. Targeting the androgen receptor pathway in prostate cancer. *Curr Opin Pharmacol* 2008, 8:440-448
6. Culig Z et al. Activation of two mutant androgen receptors from human prostatic carcinoma by adrenal androgens and metabolic derivatives of testosterone. *Cancer Detect Prev* 1996,20(1):68-75

7. Tan J et al. Dehydroepian-drosterone activates mutant androgen receptors expressed in the androgen-dependet human prostate cancer xeno-graft CWR22 and LNCaP cells. *Mol Endocrinol* 1997, 11(4):450-9
8. Potter GA, Barrie SE, Jarman M, Rowlands MG. Novel steroidal inhibitors of human cytochrome P45017 alpha (17 alpha hydroxylase-C, 17,20-lyase): Potential agents for the treatment of prostatic cancer. *J Med Chem* 1995,38:2463-71
9. O'Donnel A et al. Hormonal impact of the 17alpha-hydroxylase/C(17,20)-lyase inhibitor abiraterone acetate (CB7630) in patients with prostatic cancer. *Br J Cancer* 2004,90:2317-25
10. Small EJ et al. Antiandrogen withdrawal alone or in combination with ketoconazole in androgen independent prostate cancer patients: a phase III trial . *J Clin Oncol* 2004,22: 1025-33
11. Haidar S, Ehmer PB, Barassin S, Batzl-Hartmann C, Hartmann RW. Effects of novel 17alpha-hydroxylase/c17,20-lyase (P45017, CYP17) inhibitors on androgen biosynthesis in vitro and in vivo. *J Steroid Biochem Mol Biol* 2003, 84: 555-62
12. Sumanta K, Oliver S. Phase III data for abiraterone in an evolving landscape for castration-resistant prostate cancer. *Maturitas*. 2011, 68(2): 103–105
13. Taplin ME et al. Mutation of the androgen receptor gene in metastatic androgen-independent prostate cancer. *N Engl J Med*. 1995,332(21):1393-1398
14. Edwards J, Krishna NS, Gricor KM, Bartlett JM. Adrogen receptor gene amplification and protein expression in hormone refractory prostate cancer. *Br J Cancer* 2003,89:552-6
15. Chen CD et al. Molecular deter-minants of resistance to antiandrogen therapy. *Nat Med* 2004,10:33-9
16. Shreya Shah, Charles Ryan. Abiraterone acetate for castration resistant prostate cancer. *Expert Opin. Invstig Drugs* 2010,19(4): 563-570

17. Montgomery RB et al. Maintenance of intratumoral androgens in metastatic prostate cancer: a mechanism for castration-resistant tumor growth. *Cancer Res* 2008,68(11):4447-4454

18. Παπαδήμας Ι. – Μανταλενακης Σ.Ι. Ενδοκρινολογία αναπαραγωγής στον άνδρα. Στο: Φυσιολογία των όρχεων.1<sup>η</sup> έκδοση. University Studio Press, Θεσσαλονικη 1993. Σελ 40

19. Huggins C and Scott M. Bilateral adrenalectomy in prostatic cancer: Clinical features and urinary excretion of 17ketosteroids and oestrogen. *Ann Surg* 1945,122:1031

20. MacFarlane D, Thomas L and Harrison J. A Survey of Total Adrenalectomy in Cancer of the Prostate. *Am. J. Surg.* 1960, 99:562

21. S . Taylor et al. Effect of surgical addison’s disease on advanced carcinoma of the breast and prostate. *Cancer* 1953,6:997-1007

22. Bhanalaph T, Varkarakis J, Murphy G. Current Status of Bilateral Adrenalectomy on Advanced Prostatic Carcinoma. *Ann Surg* 1974,179:17-22

23. Merrin C et al. Long-term survival after bilateral adrenalectomy. *Urology* 1974,3:223-225

24. Hasan R et al. Outcomes for Laparoscopic Bilateral Adrenalectomy. *Journal of Laparoendoscopic & Advanced Surgical Techniques.*2002, 12(4): 233-236.

25. Takata MC, Kebebew E, Clark OH, Duh QY. Laparoscopic bilateral adrenalectomy: results for 30 consecutive cases. *Surg Endosc.* 2008,22(1):202-7.

26. Castillo OA, López-Fontana G, Vitagliano G. Laparoscopic synchronous bilateral adrenalectomy. *Arch Esp Urol.* 2011,64(2):114-20

27. Welbourn RB. Survival and causes of death after adrenalectomy for Cushing's di-sease. *Surgery.* 1985,97(1):16-20.

28. Urschel JD, Finley RK, Takita H. Long-term survival after bilateral adrenalectomy for metastatic lung cancer: a case report. *Chest.* 1997,112(3):848-50

# The role of transarterial embolization of the renal cell carcinomas (RCC) in elderly and unfit for surgical treatment patients.

Stamatiou K<sup>1</sup>, Moschouris I<sup>2</sup>

1. Urology Department, Tzaneio General Hospital, Piraeus, Greece
2. Radiology Department, Tzaneio General Hospital, Piraeus, Greece

## Corresponding author:

Konstantinos N. Stamatiou, Tzaneio Hospital, Afendouli 1 Ave, 18536 Pireas, Attica - Greece,  
E-mail: stamatiouk@gmail.com

## Περίληψη

Ο σκοπός αυτής της μελέτης είναι να παρουσιάσει το ρόλο του χημειοεμβολισμού των νεφρικών καρκινωμάτων και να αξιολογήσει την αποτελεσματικότητά του ως ανακουφιστική θεραπεία των ανεγχείρητων ή/και χαμηλού σταδίου νεφροκυτταρικών καρκινωμάτων ασθενών ακατάλληλων για χειρουργείο. Η ομάδα μελέτης αποτελείτο από 8 διαδοχικούς ασθενείς (3 άνδρες και 5 γυναίκες, με εύρος ηλικίας 71-87 ετών), οι οποίοι υποβλήθηκαν σε παρηγορητικό εμβολισμό νεφρικών καρκινωμάτων μεταξύ Ιανουαρίου 2008 και Δεκεμβρίου 2013. Στις 7 απο τις 8 περιπτώσεις ο όγκος ήταν πρωτοπαθής ενώ στην μία ήταν δευτεροπαθούς προέλευσης. Σε 1 περίπτωση διαγνώστηκε αμφοτερόπλευρη νόσος. Σε 2 περιπτώσεις υπήρχαν περισσότεροι απο ένας όγκος στον πάσχοντα νεφρό. Σε 5 ασθενείς η νόσος ήταν ανεγχείρητη (3 σταδίου IVa και δύο σταδίου IVb) και σε 3 ήταν δυνητικά χειρουργήσιμη (2 σταδίου II, και ένας σταδίου IIIa). Ωστόσο, οι τελευταίοι 3 ασθενείς αυτοί ήταν ακατάλληλοι για χειρουργική επέμβαση λόγω σοβαρών συνυπαρχόντων προβλημάτων υγείας. Από όλους τους ασθενείς οι 3 παρουσιάστηκαν κυρίως με αιματουρία και οι υπόλοιποι ασθενείς με πόνο στην πλάγια κοιλιακή χώρα ενώ σε μία ασθενή συνυπήρχαν και τα δύο. Ο εμβολισμός των νεφρικών καρκινωμάτων διεξήχθη χρησιμοποιώντας σφαιρίδια και σπινάλ. Κατά το χρόνο της ανάλυσης, 4 ασθενείς έχουν πεθάνει και 4 ασθενείς είναι ακόμα ζωντανοί, με συνολική μέση επιβίωση 17,57 μήνες. Σε 3 απο τους ασθενείς με μακροσκοπική αιματουρία έγινε μετάγγιση μέχρι τη σταθεροποίηση του επιπέδου της αιμοσφαιρίνης πριν τον εμβολισμό. Επανεμφάνιση της αιματουρίας παρατηρήθηκε σε 2 από αυτούς τους ασθενείς. Στους 5 ασθενείς που παρουσιάστηκαν με πόνο, τα συμπτώματα βελτιώθηκαν σε δύο και υποχώρησαν 1σε 3. Η μέση διάρκεια παραμονής στο νοσοκομείο για όλους τους ασθενείς ήταν 5,25 ημέρες.



Συμπερασματικά, ο εμβολισμός των νεφρικών καρκινωμάτων είναι μια ασφαλής και ανεκτή λύση για τη διαχείριση ασθενών με ανεγχείρητο ή καρκίνωμα του νεφρού ως μέσο για την ανακούφιση των τοπικών συμπτωμάτων και τη βελτίωση της κλινικής κατάστασης, με χαμηλή νοσηρότητα και μικρή παραμονή στο νοσοκομείο.

### Λέξεις ευρετηριασμού

Φροκυτταρικό, ρκίνωμα, Αρτηριακός, εμβολισμός

### Abstract

The purpose of this study is to demonstrate the role of transarterial embolization of the renal cell carcinomas and to evaluate its effectiveness as a palliative treatment of patients with unresectable renal cell carcinoma and patients with low stage renal cell carcinoma who are unsuitable for surgery. The study group consisted of eight patients (3 males and 5 females between 71 and 87 years of age), who underwent palliative embolization of renal carcinomas between January 2008 and December 2013. Unresectable disease was present in 4 patients (3 stage Iva and 1 stage IVb). Potentially resectable disease was present in 3 patients (2 stage II and 1 stage IIIa), who were unsuitable for surgical treatment due to serious comorbidities. Metastatic tumor was present in 1 patient. Only 3 were presented with haematuria and the others presented with pain in the lateral abdomen. Embolization of renal tumors was performed using beads and coils. In 3 patients with macroscopic haematuria we performed transfusion to stabilize the hemoglobin level before embolization. In patients who presented with pain, symptoms improved in 2 and disappeared in 3. The average length of hospital stay for all patients was 5.25 days. In conclusion, the embolization of renal tumors is a safe and tolerated solution for the management of patients with unresectable disease, to relieve local symptoms and to improve clinical status with low morbidity and short hospitalization.

### Keywords:

renal-cell carcinoma, transarterial embolization

### Introduction

Transarterial embolization of the renal cell carcinomas (RCC) was first introduced in the clinical practice in the 1970s as an invasive procedure secondary to arteriography, the latter being the basic diagnostic method for renal tumors identification of the time<sup>1</sup>. In general, embolization is widely applied in the treatment of persistent haemorrhage, vascular lesions and tumors. In urology, it has been established in the management of iatrogenic complications-induced haemorrhage following various procedures<sup>2</sup>. Embolization aims to block the blood supply in an organ or a certain region and is performed via the introduction

of an angiographic catheter in a blood vessel and the subsequent use of obstruction materials. The materials used for RCC embolization include coils (spirals), beads, cyanoacrylate glues and alcohol solutions<sup>3</sup>. Blood flow blockade causes acute tissue necrosis which in turn results in acute phase response (APR). During its 40 years of use, RCC embolization has been applied as a neoadjuvant or palliative therapy in large or inoperable tumors as well as in the management of persistent haemorrhage and/or pain<sup>4</sup>. Although it mainly contributes in treating symptoms, there are indications that it may offer long-term survival. Indeed, certain studies concluded that RCC embolization may deliver stabilization and/or remission of distant metastases<sup>5</sup>. The exact mechanism explaining the above phenomenon is not known but it could be attributed to an immunoregulatory process. In such a case, embolization-induced tumor necrosis (TN) stimulates the immune system of the host as a response to tumor contracture.

## **Materials & Methods**

Eight consecutive patients (3 males and 5 females, aged 71-87), were subjected to palliative RCC embolization between January 2008 and December 2013. Unresectable tumors were present in 4 patients (3 stage IVa, 1 stage IVb). Potentially resectable tumors were present in 3 patients (2 stage II, 1 stage IIIa). One patient has metastatic disease induced by rectal adenocarcinoma. In this case the renal tumor measured 7.1 cm and it was located in the upper pole of the right kidney. Four out of the 8 patients of the study were unfit for surgical treatment since they suffered of serious cardiac and pulmonary conditions while one patient was unfit for surgical treatment due to metastatic disease. Haematuria was the main symptom in 3 patients, pain was the main symptom in 4 patients and in one female patient both symptoms co-existed.

The same procedure was followed for all patients who were included in the study: initially, infusion of local anaesthetic (xylocaine 1%) to the side of the catheter insertion was performed followed by catheterization of the femoral artery under radiologic guidance<sup>1</sup>. The angiographic catheter was then advanced up the ventral aorta (Seldinger procedure). Next, a selective catheterization of the renal arteries via a 5-Fr Cobra I hydrophilic catheter, assisted by infused contrast agent was done. Renography completed the first stage of the procedure. Afterwards, highly-selective catheterization of the nutrient arteries of the tumor was performed followed by embolization with intra-arterial infusion of irinotecan loaded microparticles (IAIRIM) (DC-Beads, Biocompatibles diam. 300-500  $\mu\text{m}$ , dosage: 50mg/ml microspheres) as well as with chemo-free microspheres (Embozene, Celonova, diam. 400  $\mu\text{m}$ ), complemented by the placement of a spiral, until the almost complete elimination of neovascularization. In case of multiple tumor vascularization, the same procedure is performed separately for each nutrient vessel. Absence of blood flow in the embolized area during angiography was determined as the standard for successful embolization<sup>1</sup>. The favourable outcome was confirmed by standard angiography or CT-scan or ultrasound study with contrast medium (SonoVue, Bracco).

The whole procedure lasted 30 to 60 minutes. In two cases the procedure was repeated. None of the patients presented serious complications other than post-embolization syndrome (PES): In four of the 8 patients temporary creatinine increase (up to 2.8 mg/dl) was occurred. All these patients were monitored after the procedure receiving hydration and IV antibiotics until the syndrome remitted and the renal function was restored. At the time of analysis, 4 patients were deceased and 4 patients are still alive. The median overall survival (OS) was 15.75 months. In 3 patients with macroscopic haematuria, we performed transfusion to stabilize the pre-embolization haemoglobin levels. Haematuria recurrence

Gender	Age	Stage	Symptom	Accompanying diseases
Male	77	IVa	Haemorrhage	No
Female	72	IVB	Pain	No
Male	81	IVa	Pain	No
Female	87	II	Haemorrhage	HF <sup>1</sup> , CRF <sup>2</sup>
Male	74	IVa	Pain	No
Female	78	IIIa	Haemorrhage	COPD <sup>3</sup>
Female	86	II	Pain	HF, COPD
Female	71	II	Pain	CC <sup>4</sup>

**Appendix:** <sup>1</sup> Heart Failure, <sup>2</sup> Chronic Renal Failure, <sup>3</sup> Chronic Obstructive Pulmonary Disease, <sup>4</sup> Colon Cancer

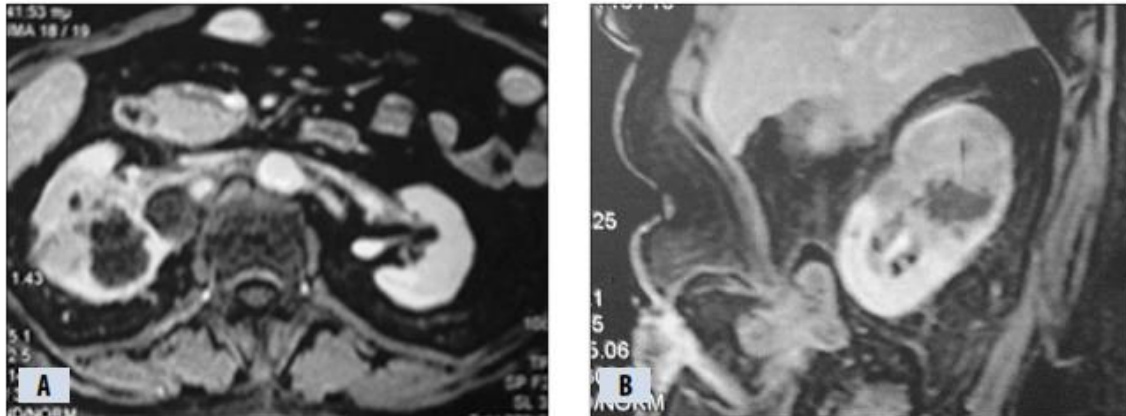
Hospital stay	Transfusion	Improvement	Fever	Pain	Outcome	Survival
8	yes	no	no	yes	A <sup>1</sup>	11
3	no	yes	no	yes	D <sup>2</sup>	6
2	no	yes	no	yes	D	9
12	yes	no	no	yes	A	38
3	no	yes	yes	yes	A	17
3	yes	yes	no	no	D	19
7	no	no	no	no	A	23
4	no	yes	yes	no	D	3

**Appendix:** <sup>1</sup>A= Alive, <sup>2</sup>D=Deceased


was identified in 2 of these patients. Out of the 5 patients presenting with pain, the symptoms improved in 2 and completely resolved in 3. Mean hospitalization for all study patients was 5.25 days.

While the value of RCC embolization in managing related symptoms like pain and haematuria is widely accepted, it is not established whether there is a true survival benefit. Provenza et al<sup>5</sup>, investigated the efficacy of RCC embolization in a small number of patients with stage III and stage IV RCCs. In total, mean survival was 8.5 months, whereas mean survival for stage III and stage IV RCC patients was 23 and 7 months, respectively. Onishi et al, compared two study groups with unresected disease (stageIV): 24 patients were subjected to embolization and 30 patients did not receive any treatment. Mean survival for the treatment group was 229 days and for the control group 116 days. The subjects who underwent treatment (embolization) manifested a significantly better outcome than those

who were not managed<sup>6</sup>. Other authors report that the mean survival for all patients subjected to embolization ranges between 4 and 8.4 months. This corresponds to a survival rate of 36.8 and 15.8% for 1 and 2 years, respectively<sup>7</sup>. In contradiction, Ridley et al support that embolization does not constitute a therapeutic approach and potentially it does not alter the natural progression of the disease to a great extent, but it palliates the symptoms related to advanced stage diseases<sup>8</sup>. The fact that RCC embolization could trigger a tumor necrosis-induced immunoregulation response is an intriguing perspective and in fact, in an experimental study, Nakano et al proved that the lymphocytes in RCC patients were



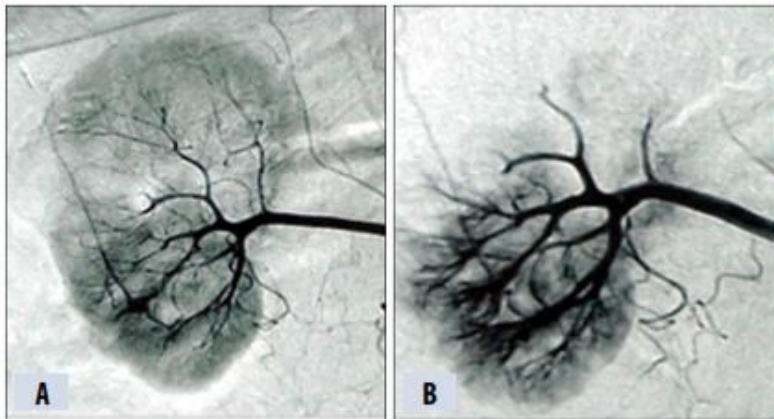
**Figure 1 (A, B):** Transverse and sagittal T1 - weighted contrast material - enhanced fat - suppressed magnetic resonance (MR) sequences, respectively, depicting lesion and necroses within



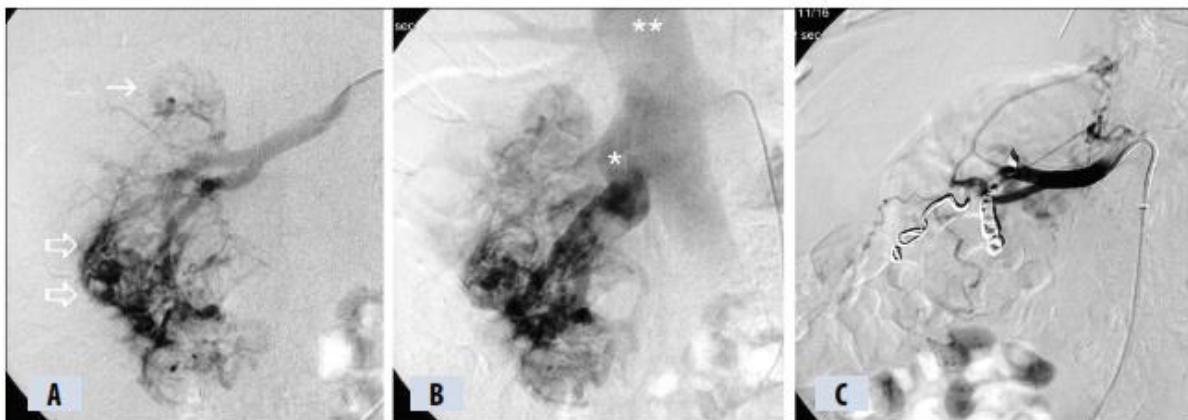
**Figure 2 (A, B):** Contrast medium - assisted ultrasound of the left renal upper pole tumor image prior - (A) and 15 - days post - chemoembolization (B), depicting the extensive lesion necrosis as non - opacified

embolization-stimulated in vitro<sup>9</sup>. Nonetheless, RCC embolization has not yet gained wide acceptance, possibly due to the lack of prospective randomized studies proving these presumable benefits. Effective embolization results in tissue or organ ischemic necrosis, which however generates a group of symptoms named post-embolization syndrome (PES) commonly developing within the first post-embolization days<sup>10</sup>. Patients with smaller or peripheral tumors and patients with long-term sizeable non-embolized normal parenchyma exhibit a greater risk of developing PES<sup>10</sup>. The syndrome includes: pain in the lumbar area, nausea and vomits, fever and arterial pressure fluctuations<sup>7</sup>. The symptoms are usually transient and their severity depends on the extension of ischemia in the kidneys region. In a

small percentage, embolization may result in serious complications mainly related to embolization material migration to another organ like the contralateral artery, the mesenteric arteries, the lower limbs arteries and spinal cord ischemic lesion<sup>11</sup>. The risk of serious complications is lower if embolization is duly performed and in most cases, as in our series, patients are discharged after short hospitalization.



**Figure 3 (A, B):** Selective right kidney digital ablative angiography of the renal metastasis in the right kidney upper pole, prior - (A) and post - chemoembolization (B). Post - chemoembolization image exhibits the almost complete elimination of lesion vascularization



**Figure 4 (A, B, Γ):** Selective right renal artery angiography in two right kidney RCC sites pre- (A, B) and post-chemoembolization (Γ). The early arterial phase reveals pathologic vascularization with new spiral vessels, more evident in the sizeable lower pole tumor (empty arrows) and subtle in the smaller upper pole tumor (arrow). A later image study (B) showed extensive arteriovenous communications (AVC) in the lower pole tumor, with early opacification of the renal vein (\*) and the inferior vena cava (IVC) (\*\*). After the embolization with coils and microspheres (Γ), we observe neovascularization and AVCs elimination.

## Conclusions

Currently available data suggest that RCC embolization is a relatively well-tolerated treatment option in patients with unresectable renal tumors or patients unfit for surgery or patients who do not wish to undergo a surgical procedure to palliate local symptoms and

improve their clinical status. Especially in elderly patients, radical nephrectomy (RN) may cause significant pre- and post-operative morbidity while in certain cases it also does not allow the application of a systemic treatment. Consequently, renal artery embolization seems to be a safe alternative for the aged patients compared to RN due to its low morbidity and limited range of complications.

## References

1. Hallscheidt PJ, Fink C, Haferkamp A, et al. Preoperative staging of renal cell carcinoma with inferior vena cava thrombus using multidetector CT and MRI: prospective study with histopathological correlation. *J Comput Assist Tomogr* 2005;29:64–8.
2. Maxwell NJ, Saleem Amer N, Rogers E, Kiely D, Sweeney P, Brady AP. Renal artery embolisation in the palliative treatment of renal carcinoma. *Br J Radiol* 2007;80:96-10.
3. Sauk S, Zuckerman DA. Renal artery embolization. *Semin Intervent Radiol*. 2011;28(4):396-40
4. Winokur RS, Pua BB, Madoff DC. Role of combined embolization and ablation in management of renal masses. *Semin Intervent Radiol*. 2014;31(1):82-5.
5. Provenza G, Sparagna A, Cunsolo GV, Tierno SM, Centanini F, Bellotti C, Mezzetti G. Renal artery embolization in a gross kidney neoplasm. *G Chir*. 2013;34(9-10):263-6.
6. Onishi T, Oishi Y, Suzuki Y, Asano K. Prognostic evaluation of transcatheter arterial embolization for unresectable renal cell carcinoma with distant metastasis. *BJU Int*. 2007;87(4):312-5.
7. Zielinski, H Syrylo T, Szmigielski S. Renal Artery Embolization in Treatment of Renal Cancer with Emphasis on Response of Immune System. In: *Renal Tumor*, edited by Jindong Chen, ISBN 978-953-51-0981-5.
8. Ridley SL, Culp SH, Jonascg F et al. Outcome of patients with metastatic renal cell carcinoma treated with targeted therapy without cytoreductive nephrectomy. *Ann Oncol* 2011; 22: 1048-53
9. Nakano H, Nihira H, Toge T. Treatment of renal cancer patients by transcatheter embolization and its effects on lymphocyte proliferative responses. *J Urol*. 1983;130(1):24-7.
10. Lanigan D, Jurriaans E, Hammonds JC, Wells IP, Choa RG. The current status of embolization in renal cell carcinoma – a survey of local and national practice. *Clin Radiol* 1992;46:176–8.
11. Choe J, Shin JH, Yoon HK, Ko GY, Gwon DI, Ko HK, Kim JH, Sung KB. Safety and efficacy of transarterial nephrectomy as an alternative to surgical nephrectomy. *Korean J Radiol*. 2014 Jul-Aug;15(4):472-80.

# Για τη συμπτωματική θεραπεία του συνδρόμου της Υπερλειτουργικής Κύστης



ADV/BET/11/2014

Βοηθήστε να γίνουν τα φάρμακα πιο ασφαλή και δυναμότερα  
ΟΛΕΣ τις ανεπιθύμητες ενέργειες για ΟΑΑ τα φάρμακα Συμπληρώνονται την «**ΚΙΤΡΙΝΗ ΚΑΡΤΑ**»

Συσκευασία των 30 δισκίων των 50mg,  
Λιανική τιμή Betmiga 50mg Ελλάδα: 45,87€  
Λιανική τιμή Betmiga 50mg Κύπρος: 58,35€

Για περισσότερες πληροφορίες συμβουλευτείτε την ΠΧΠ Betmiga που διατίθεται από τον ΚΑΚ, **ΦΑΡΜΑΚΕΥΤΙΚΟ ΠΡΟΪΟΝ ΓΙΑ ΤΟ ΟΠΟΙΟ ΑΠΑΙΤΕΙΤΑΙ ΙΑΤΡΙΚΗ ΣΥΝΤΑΓΗ**



## ΠΕΡΙΛΗΨΗ ΤΩΝ ΧΑΡΑΚΤΗΡΙΣΤΙΚΩΝ ΤΟΥ ΠΡΟΪΟΝΤΟΣ

▼ Το φάρμακο αυτό τελεί υπό συμπληρωματική παρακολούθηση. Αυτό θα επιφέρει τον ταχύ προσδιορισμό νέων πληροφοριών ασφαλείας. Ζητείται από τους επαγγελματίες του τομέα της υγειονομικής περίθαλψης να αναφέρουν οποιαδήποτε πιθανολογούμενες ανεπιθύμητες ενέργειες. Βλ. παράγραφο 4.8 για τον τρόπο αναφοράς ανεπιθύμητων ενεργειών.

**1. ΟΝΟΜΑΣΙΑ ΤΟΥ ΦΑΡΜΑΚΕΥΤΙΚΟΥ ΠΡΟΪΟΝΤΟΣ:** Betmiga 50 mg δισκία παρατεταμένης αποδέσμευσης **2. ΠΟΙΟΤΙΚΗ ΚΑΙ ΠΟΣΟΤΙΚΗ ΣΥΝΘΕΣΗ:** Κάθε δισκίο περιέχει 50 mg mirabegron. Για τον πλήρη κατάλογο των εκδόχων, βλ. παράγραφο 6.1. **3. ΦΑΡΜΑΚΟΤΕΧΝΙΚΗ ΜΟΡΦΗ:** Δισκίο παρατεταμένης αποδέσμευσης. Οβάλ, κίτρινο δισκίο, χαραγμένο με το λογότυπο της εταιρείας και τον κωδικό "355" στην ίδια πλευρά. **4. ΚΛΙΝΙΚΕΣ ΠΛΗΡΟΦΟΡΙΕΣ: 4.1 Θεραπευτικές ενδείξεις:** Συμπτωματική θεραπεία της επιτακτικότητας, συχνουρίας και/ή επιτακτικού τύπου ακράτειας, όπως αυτή μπορεί να παρουσιαστεί σε ενήλικες ασθενείς με σύνδρομο υπερλειτουργικής ουροδόχου κύστης (Overactive Bladder Syndrome, OAB). **4.2 Δοσολογία και τρόπος χορήγησης:** Δοσολογία: Ενήλικες (συμπεριλαμβανομένων των ηλικιωμένων ασθενών). Η συστηματική δόση είναι 50 mg από 1-2 φορές ημερησίως, με ή χωρίς τροφή. **Είδος/πλήρης/μερική και ηπιακή δυσλειτουργία:** Το Betmiga δεν έχει μελετηθεί σε ασθενείς με νεφροπάθεια τελικού σταδίου (GFR < 15 ml/min/1,73 m<sup>2</sup>) ή ασθενείς που χρειάζονται αιμοδιύλιση (1) ή σοβαρή ηπιακή δυσλειτουργία (Child-Pugh Κατηγορία Γ) και επομένως δεν συνιστάται για χρήση σε αυτούς τους πληθυσμούς ασθενών (βλ. παραγράφους 4.4 και 5.2). Ο παρακάτω πίνακας περιλαμβάνει τις συστάσεις ημερησίου δοσολογίας για άτομα με νεφρική ή ηπιακή δυσλειτουργία στην απουσία και παρουσία ισχυρών αναστολέων του CYP3A (βλ. παραγράφους 4.4, 4.5 και 5.2).

		Ισχυροί αναστολείς του CYP3A (2)	
		Χωρίς αναστολέα	Με αναστολέα
Νεφρική δυσλειτουργία (1)	Ήπια	50 mg	25 mg
	Μέτρια	50 mg	25 mg
	Σοβαρή	25 mg	Δεν συνιστάται
Ηπιακή δυσλειτουργία (2)	Ήπια	50 mg	25 mg
	Μέτρια	25 mg	Δεν συνιστάται

1. Ηπια: GFR 60 έως 89 ml/min/1,73 m<sup>2</sup>; μέτρια: GFR 30 έως 59 ml/min/1,73 m<sup>2</sup>; σοβαρή: GFR 15 έως 29 ml/min/1,73 m<sup>2</sup>. 2. Ηπια: Child-Pugh Κατηγορία Α, Μέτρια: Child-Pugh Κατηγορία Β. 3. Ισχυροί αναστολείς του CYP3A βλ. παράγραφο 4.5

**Φύλο:** Δεν απαιτείται προσαρμογή της δόσης ανάλογα με το φύλο. **Παιδιατρική πληθυσμός:** Η ασφάλεια και η αποτελεσματικότητα του mirabegron σε παιδιά ηλικίας κάτω των 18 ετών δεν έχουν ακόμη τεκμηριωθεί. Δεν υπάρχουν διαθέσιμα δεδομένα. **Τρόπος χορήγησης:** Το δισκίο πρέπει να λαμβάνεται από ημερησίως, με υγρό, να καταπίνεται ολόκληρο και δεν πρέπει να μασάται, να διαλύεται ή να συνθλίβεται. **4.3 Αντενδείξεις:** Υπερτασισία στη δράση/ισοία ή σε κέσσο από τα έκδοχα που αναφέρονται στην παράγραφο 6.1. **4.4 Ειδικές προειδοποιήσεις και προφυλάξεις κατά τη χρήση:** **Νεφρική δυσλειτουργία:** Το Betmiga δεν έχει μελετηθεί σε ασθενείς με νεφροπάθεια τελικού σταδίου (GFR < 15 ml/min/1,73 m<sup>2</sup>) ή ασθενείς που χρειάζονται αιμοδιύλιση (1) και επομένως δεν συνιστάται για χρήση σε αυτούς τους πληθυσμούς ασθενών. Υπάρχουν περιορισμένα δεδομένα για ασθενείς με σοβαρή νεφρική δυσλειτουργία (GFR 15 έως 29 ml/min/1,73 m<sup>2</sup>). Με βάση μια φαρμακοκινητική μελέτη (βλέπε παράγραφο 5.2), συνιστάται μείωση της δόσης στα 25 mg σε αυτούς τον πληθυσμό. Το Betmiga δεν συνιστάται για χρήση σε ασθενείς με σοβαρή νεφρική δυσλειτουργία (GFR 15 έως 29 ml/min/1,73 m<sup>2</sup>) που λαμβάνουν ισχυρούς αναστολείς του CYP3A (βλ. παράγραφο 4.5). **Υπέρταση:** Το Betmiga δεν έχει αξιολογηθεί σε ασθενείς με σοβαρή μη ελεγχόμενη υπέρταση (συστολική αρτηριακή πίεση ≥ 180 mm Hg και/ή διαστολική αρτηριακή πίεση ≥ 110 mm Hg). Συνεπώς, δεν συνιστάται για χρήση σε αυτούς τον πληθυσμό ασθενών. Τα δεδομένα είναι περιορισμένα σε ασθενείς με υπέρταση σταδίου 2 (συστολική αρτηριακή πίεση ≥ 160 mm Hg ή διαστολική αρτηριακή πίεση ≥ 100 mm Hg). **Ασθενείς με αυξημένη ή επίκτητη παράταση του διαστήματος QT:** Το Betmiga, στις θεραπευτικές δόσεις, δεν έχει αποδείξει κλινικά σημαντική παράταση του διαστήματος QT σε κλινικές μελέτες (βλ. παράγραφο 5.1). Ωστόσο, δεδομένου ότι ασθενείς με γνωστό ιστορικό παράτασης του διαστήματος QT ή ασθενείς οι οποίοι λαμβάνουν φαρμακευτικά προϊόντα που είναι γνωστό ότι παρατείνουν το διάστημα QT δεν συμπεριλήφθηκαν σε αυτές τις μελέτες, οι επιδράσεις του mirabegron σε αυτούς τους ασθενείς δεν είναι γνωστές. Προσοχή πρέπει να επιδεικνύεται κατά τη χορήγηση του mirabegron σε αυτούς τους ασθενείς. **Ασθενείς με υποκατατική απόφραξη** και ασθενείς που λαμβάνουν αντιμυοκαρδική αγωγή για ΟΑΒ: Επίσχεση ούρων σε ασθενείς με υποκατατική απόφραξη (BOO) και σε ασθενείς που λαμβάνουν αντιμυοκαρδική αγωγή για τη θεραπεία της ΟΑΒ έχει αναφερθεί κατά την εμπειρία μετά την κυκλοφορία στην αγορά σε ασθενείς που λαμβάνουν mirabegron. Μια ελεγχόμενη μελέτη κλινικής ασφαλείας, σε ασθενείς με BOO δεν καταδείξε αυξημένη επίσχεση ούρων σε ασθενείς υπό θεραπεία με Betmiga. Ωστόσο, το Betmiga θα πρέπει να χορηγείται με προσοχή σε ασθενείς με κλινικά σημαντική BOO. Το Betmiga θα πρέπει επίσης να χορηγείται με προσοχή σε ασθενείς που λαμβάνουν αντιμυοκαρδική αγωγή για τη θεραπεία της ΟΑΒ. **4.8 Ανεπιθύμητες ενέργειες:** Περίληψη του προφίλ ασφαλείας: Η ασφάλεια του Betmiga αξιολογήθηκε σε 8.433 ασθενείς με ΟΑΒ, εκ των οποίων οι 5.648 έλαβαν τουλάχιστον μία δόση του mirabegron στη φάση 2/3 του κλινικού προγράμματος, και 622 ασθενείς έλαβαν Betmiga για τουλάχιστον 1 χρόνο (365 ημέρες). Σε τρεις διάρκειες 12 εβδομάδων, φάσης 3, διπλά τυφλές, ελεγχόμενες με εικονικό φάρμακο μελέτες, το 88% των ασθενών ολοκλήρωσαν τη θεραπεία με Betmiga, και το 4% των ασθενών διέκοψαν τη θεραπεία λόγω ανεπιθύμητων ενεργειών. Οι περισσότερες ανεπιθύμητες ενέργειες ήταν ήπιες έως μέτριες σοβαρότητας. Οι πιο συχνές ανεπιθύμητες ενέργειες που αναφέρθηκαν σε ασθενείς υπό θεραπεία με Betmiga 50 mg κατά τη διάρκεια των τριών, διάρκειας 12 εβδομάδων, φάσης 3, διπλά τυφλών, ελεγχόμενων με εικονικό φάρμακο μελέτων είναι ταχυκαρδία και ουρολοιμώξεις. Η συχνότητα της ταχυκαρδίας ήταν 1,2% σε ασθενείς που λάμβαναν Betmiga 50 mg. Η ταχυκαρδία οδήγησε σε διακοπή στο 0,1% των ασθενών που λάμβαναν Betmiga 50 mg. Η συχνότητα των ουρολοιμώξεων ήταν 2,9% σε ασθενείς που λάμβαναν Betmiga 50 mg. Οι ουρολοιμώξεις δεν οδήγησαν σε διακοπή κανένα από τους ασθενείς που έλαβαν Betmiga 50 mg. Στις σοβαρές ανεπιθύμητες ενέργειες περιλαμβάνεται κοιλιακή μαρμαρυγή (0,2%). Οι ανεπιθύμητες ενέργειες που παρατηρήθηκαν κατά τη διάρκεια της 1 έτους (μακροχρόνιας) ελεγχόμενης με δραστικό φάρμακο (μυοκαρδικής ανταγωνιστής) μελέτης ήταν παρόμοια σε τύπο και σοβαρότητα με εκείνες που παρατηρήθηκαν στις τρεις, διάρκειας 12 εβδομάδων,

φάσης 3, διπλά τυφλές, ελεγχόμενες με εικονικό φάρμακο μελέτες. **Συνοπτικός πίνακας ανεπιθύμητων ενεργειών:** Ο παρακάτω πίνακας απεικονίζει τις ανεπιθύμητες ενέργειες που παρατηρήθηκαν με το mirabegron στις τρεις, διάρκειας 12 εβδομάδων, φάσης 3, διπλά τυφλές, ελεγχόμενες με εικονικό φάρμακο μελέτες. Η συχνότητα των ανεπιθύμητων ενεργειών ορίζεται ως εξής: πολύ συχνές (≥ 1/10), συχνές (≥ 1/100 έως < 1/10), όχι συχνές (≥ 1/1.000 έως < 1/100), σπάνιες (≥ 1/10.000 έως < 1/1.000), πολύ σπάνιες (< 1/10.000). Εντός κάθε κατηγορίας συχνότητας εμφάνισης, οι ανεπιθύμητες ενέργειες παρατίθενται κατά φθίνουσα σειρά σοβαρότητας.

MedDRA Κατηγορία/ οργανικό σύστημα	Συχνές	Όχι συχνές	Σπάνιες
Λοιμώξεις και παροσιτώσεις	Ουρολοιμώξη	Λοίμωξη του κόλπου Κυστίτιδα	
Οφθαλμικές διαταραχές			Οίδημα βλεφάρου
Καρδιακές διαταραχές	Ταχυκαρδία	Αίσθημα παλμών Κοιλιακή μαρμαρυγή	
Διαταραχές του γαστρεντερικού συστήματος		Δυσπεψία Γαστρίτιδα	Οίδημα χειλούς
Διαταραχές του δέρματος και του υποδόριου ιστού		Κνίδωση Εξάνθημα Εξάνθημα κηλιδώδες Εξάνθημα βλατιδώδες Κνησμός	Λευκοκυτταρο- κλαστική αγγειίτιδα Πορφύρα
Διαταραχές του μυοσκελετικού συστήματος και του συνδετικού ιστού		Οίδημα αρθρώσεων	
Διαταραχές του αναπαραγωγικού συστήματος και του μαστού		Αιδοοικολιπτικές κνημιάς	
Παρακλινικές εξετάσεις		αυξημένη αρτηριακή πίεση αυξημένη GGT αυξημένη AST αυξημένη ALT	

**Αναφορά πιθανολογούμενων ανεπιθύμητων ενεργειών:** Η αναφορά πιθανολογούμενων ανεπιθύμητων ενεργειών μετά από τη χορήγηση άδειας κυκλοφορίας του φαρμακευτικού προϊόντος είναι σημαντική. Επιτρέπει τη συνεχή παρακολούθηση της σχέσης οφέλους-κινδύνου του φαρμακευτικού προϊόντος. Ζητείται από τους επαγγελματίες του τομέα της υγειονομικής περίθαλψης να αναφέρουν οποιαδήποτε πιθανολογούμενες ανεπιθύμητες ενέργειες μέσω: **Ελλάδα:** Εθνικός Οργανισμός Φαρμάκων, Μεσογίων 284, GR-15562 Χολαργός, Αθήνα, Τηλ: + 30 21 3204380/337, Φαξ: + 30 21 06549585. Ιστοτόπος: <http://www.eof.gr>. **Κύπρος:** Φαρμακευτικές Υπηρεσίες, Υπουργείο Υγείας, CY-1475 Λευκωσία, Φαξ: + 357 22608649, Ιστοτόπος: <http://www.moh.gov.cy/rys>. **4.9 Υπερδοσολογία:** Το mirabegron έχει χορηγηθεί σε υγιείς εθελοντές σε εφάπαξ δόσεις έως και 400 mg. Σε αυτή τη δόση, οι ανεπιθύμητες ενέργειες που αναφέρθηκαν περιελάμβαναν αίσθημα παλμών (1 από 6 άτομα) και αυξημένη συχνότητα καρδιακών παλμών πάνω από 100 κτύπους ανά λεπτό (bpm) (3 από 6 άτομα). Πολλές δόσεις του mirabegron έως και 300 mg ημερησίως για 10 ημέρες εμφάνισαν αυξήσεις της συχνότητας των καρδιακών παλμών και της συστολικής αρτηριακής πίεσης, όταν χορηγήθηκαν σε υγιείς εθελοντές. Η αντιμετώπιση της υπερδοσολογίας πρέπει να είναι συμπτωματική και υποστηρικτική. Σε περίπτωση υπερδοσολογίας συνιστάται παρακολούθηση της συχνότητας παλμών, της αρτηριακής πίεσης και του ΗΚΓ. **6. ΦΑΡΜΑΚΕΥΤΙΚΕΣ ΠΛΗΡΟΦΟΡΙΕΣ: 6.1 Κατάλογος εκδόχων:** Πυρήνας δισκίου: Πολυαιθυλενογλυκόλες, Υδροξυπροπυλοκυτταρίνη, Βουτυλιωμένο υδροξυτολουόλιο, Μαγνήσιο στεατικό. **Επιχάλυψη δισκίου:** Υδρομεθόλη, Πολυαιθυλενογλυκόλη, Σιδήρου οξείδιο κίτρινο (E172). **6.2 Ασυμβατότητες:** Δεν εφαρμόζεται. **6.3 Διάρκεια ζωής:** 3 χρόνια. Διάρκεια ζωής μετά το πρώτο ανοίγμα της φιάλης: 6 μήνες. **6.4 Ιαίτηρες προφυλάξεις κατά τη φύλαξη του προϊόντος:** Δεν υπάρχουν ειδικές οδηγίες διατήρησης για το προϊόν αυτό. **6.5 Φύση και συστατικά του περιεχτή:** Κυψέλες αλουμινίου/αλουμινίου σε κοιλία που περιέχουν 10, 20, 30, 50, 60, 90, 100 ή 200 δισκία. Φιάλες από υψηλής πυκνότητας πολυαιθυλένιο (HDPE) με τιμωρα ασφαλείας για παιδιά από πολυπροπυλένιο (PP) και μπύρα οξείδιο πηλίμα ως αρωματικό που περιέχουν 90 δισκία. Μπορεί να μην κυκλοφορούν όλες οι συσκευασίες. **6.6 Ιαίτηρες προφυλάξεις απόρριψης:** Κάθε αρωματισμένο φαρμακευτικό προϊόν ή υπόλειμμα πρέπει να απορρίπτεται σύμφωνα με τις κατά τόπους ισχύουσες σχετικές διατάξεις. **7. ΚΑΤΟΧΟΣ ΤΗΣ ΑΔΕΙΑΣ ΚΥΚΛΟΦΟΡΙΑΣ:** Astellas Pharma Europe BV, Sylviusdreef 62, 2333 BG Leiden, Ολλανδία. **8. ΑΡΙΘΜΟΣ(ΟΙ) ΑΔΕΙΑΣ ΚΥΚΛΟΦΟΡΙΑΣ:** EU/1/12/809/001-014. **9. ΗΜΕΡΟΜΗΝΙΑ ΠΡΩΤΗΣ ΕΓΚΡΙΣΗΣ/ΑΝΑΝΕΩΣΗΣ ΤΗΣ ΑΔΕΙΑΣ:** Ημερομηνία πρώτης έγκρισης: 20 Δεκεμβρίου 2012. **10. ΗΜΕΡΟΜΗΝΙΑ ΑΝΑΘΕΩΡΗΣΗΣ ΤΟΥ ΚΕΙΜΕΝΟΥ:** 23 Απριλίου 2014.

Λεπτομερή πληροφοριακά στοιχεία για το παρόν φαρμακευτικό προϊόν είναι διαθέσιμα στον δικτυακό τόπο του Ευρωπαϊκού Οργανισμού Φαρμάκων: <http://www.ema.europa.eu>.



Astellas Pharmaceuticals A.E.B.E.  
Θουκυδίδου 1, 145 65 Αγ. Στέφανος Αττικής Τηλ: 210 8189 900, Fax: 210 8189 960